



Case Report

# Electrical Impedance Tomography (EIT) to Optimize Ventilatory Management in Critically Ill Patients: A Report of Two Cases

Iacopo Cappellini \*, Laura Campiglia, Lucia Zamidei and Guglielmo Consales

Department of Critical Care, Section of Anesthesiology and Critical Care, Azienda USL Toscana Centro, Ospedale Santo Stefano, 59100 Prato, Italy; laura.campiglia@uslcentro.toscana.it (L.C.); lucia.zamidei@uslcentro.toscana.it (L.Z.); guglielmo.consales@uslcentro.toscana.it (G.C.)

\* Correspondence: iacopo.cappellini@uslcentro.toscana.it

**Abstract:** Background: Electrical impedance tomography (EIT) is a non-invasive, radiation-free imaging method that enables the continuous bedside monitoring of regional ventilation and lung volume changes. The technique is based on the estimation of the resistivity changes that occur across the lungs with breathing. Methods: We present two case reports of patients affected by acute respiratory distress syndrome successfully managed with prone-positioning-based regional ventilation shown on EIT. Results: Both patients were submitted to cycles of prone-positioning-guided EIT and were successfully extubated and discharged from intensive care unit. Conclusions: EIT is a functional imaging method that has the potential to improve respiratory care by providing real-time, continuous monitoring of regional ventilation and lung volume changes at the bedside. Further research is needed to evaluate its efficacy in different clinical scenarios and to optimize its use in respiratory care.

**Keywords:** electrical impedance tomography; mechanical ventilation; positive end expiratory pressure



**Citation:** Cappellini, I.; Campiglia, L.; Zamidei, L.; Consales, G. Electrical Impedance Tomography (EIT) to Optimize Ventilatory Management in Critically Ill Patients: A Report of Two Cases. *Anesth. Res.* **2024**, *1*, 3–7.

<https://doi.org/10.3390/anesthres1010002>

Received: 13 June 2023

Revised: 27 June 2023

Accepted: 19 July 2023

Published: 24 July 2023



**Copyright:** © 2023 by the authors. Licensee MDPI, Basel, Switzerland. This article is an open access article distributed under the terms and conditions of the Creative Commons Attribution (CC BY) license (<https://creativecommons.org/licenses/by/4.0/>).

## 1. Introduction

Electrical impedance tomography (EIT) is a non-invasive, radiation-free imaging technique that enables real-time monitoring of lung function in critically ill patients [1]. By measuring changes in electrical impedance within the body, EIT constructs dynamic images of lung function, providing valuable information on ventilation, regional lung compliance, and changes in lung volume during mechanical ventilation [2,3]. Compared with other imaging modalities such as computed tomography (CT) or ultrasound, EIT offers several advantages. It is non-invasive, eliminating radiation exposure and making it safer for critically ill patients [1]. EIT is portable and can be conveniently used at the bedside, facilitating the real-time monitoring of lung function during mechanical ventilation [3]. Furthermore, EIT is a cost-effective modality that complements existing imaging techniques, assisting in the guidance of ventilator management strategies [1].

Numerous studies have explored the application of EIT in the ventilatory management of critically ill patients. One study focused on monitoring regional lung compliance in patients with acute respiratory distress syndrome (ARDS), using EIT to guide ventilator management strategies and identify changes in lung compliance [2]. Another study investigated the use of EIT to monitor changes in regional lung ventilation during prone positioning in ARDS patients, providing real-time feedback on the effectiveness of this technique and aiding in subsequent ventilator management decisions [3]. Additionally, a case report showcased the successful use of EIT in ventilatory management for a critically ill COVID-19 patient. EIT was employed to monitor regional lung ventilation and compliance, enabling targeted and effective ventilator management that potentially contributed to the patient's successful recovery [4].

Despite its potential benefits, EIT does have some limitations. Its spatial resolution is relatively lower compared with other imaging techniques, limiting its ability to identify

structural abnormalities within the lung. Moreover, EIT can be affected by changes in body position and patient movement, leading to artifacts in the imaging data [5].

In this article, we present two case reports of critically ill patients managed successfully with the help of electrical impedance tomography (EIT) for ventilatory management.

## 2. Case Report 1

The first patient is a 57-year-old man who was hospitalized due to severe acute respiratory distress syndrome (ARDS) caused by COVID-19 infection and legionellosis with involvement of the right lung (Figure 1). Initially, the patient was put on non-invasive ventilation with a face mask, but due to his unstable condition, he had to be put on mechanical ventilation. A further CT scan could not be performed due to the patient's condition, so EIT (electrical impedance tomography) with Enlight 2100 (Burke&Burke, Assago (Milan), Italy) was used to assess non-aerated areas in the posterior lung regions (Figure 2). Based on the results of the EIT scan, the patient was placed in a prone position for 16 h, which resulted in improved oxygenation and a best-PEEP (positive end-expiratory pressure) of 10 cm H<sub>2</sub>O (Figure 3). The patient underwent two more pronation-supination cycles, and respiratory exchanges significantly improved. To facilitate difficult weaning, the patient underwent a percutaneous tracheostomy and was weaned off invasive ventilation ten days after admission. The patient was discharged 15 days after admission from the ICU. EIT was crucial in monitoring lung aeration during positioning, optimizing ventilation strategy, and reducing the need for invasive diagnostic procedures.

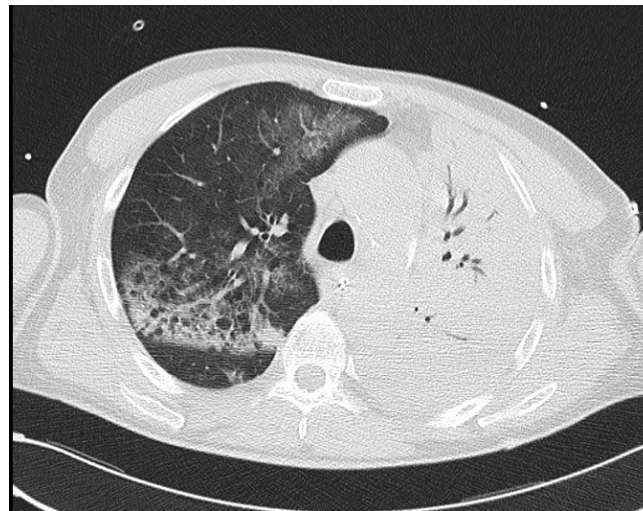

Figure 1. Computed tomography of the chest before starting non-invasive ventilation.

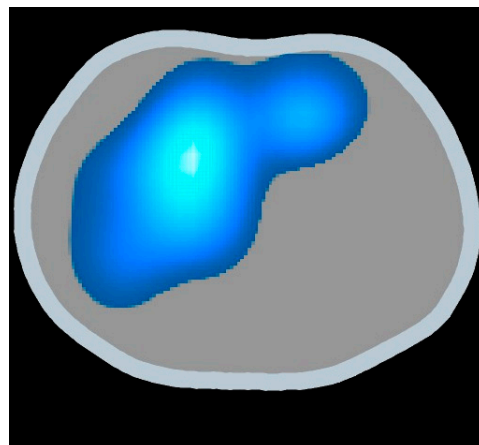


Figure 2. Regional distribution of ventilation based on EIT.

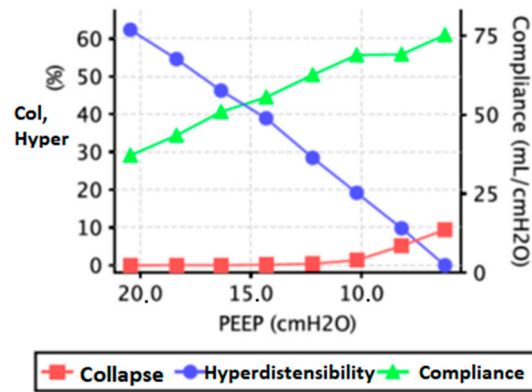


Figure 3. Best PEEP-based PEEP titration method.

### 3. Case Report 2

A 75-year-old man arrived at the emergency room after the self-inflicted ingestion of caustic agents, which resulted in the need for emergency tracheostomy and surgical gastrectomy and transcervical esophagectomy due to gastric perforation. On the first day after admission to the intensive care unit, his respiratory exchanges progressively worsened with the development of acute respiratory distress syndrome (ARDS). Therefore, EIT monitoring with Enlight 2100 was implemented, which showed the non-aeration of dependent lung regions and the inhomogeneity of parenchyma with the basal right pendelluft phenomenon (Figure 4). As a result, three cycles of prone positioning were performed, leading to a significant improvement in oxygenation. This allowed the patient to begin weaning from mechanical ventilation, which was successfully completed on the tenth day after surgery. The patient was then discharged after 25 days of hospitalization to continue the necessary treatments for the underlying condition that led to admission to the intensive care unit. EIT was crucial in monitoring lung aeration during positioning, optimizing the ventilation strategy, and reducing the need for invasive diagnostic procedures.

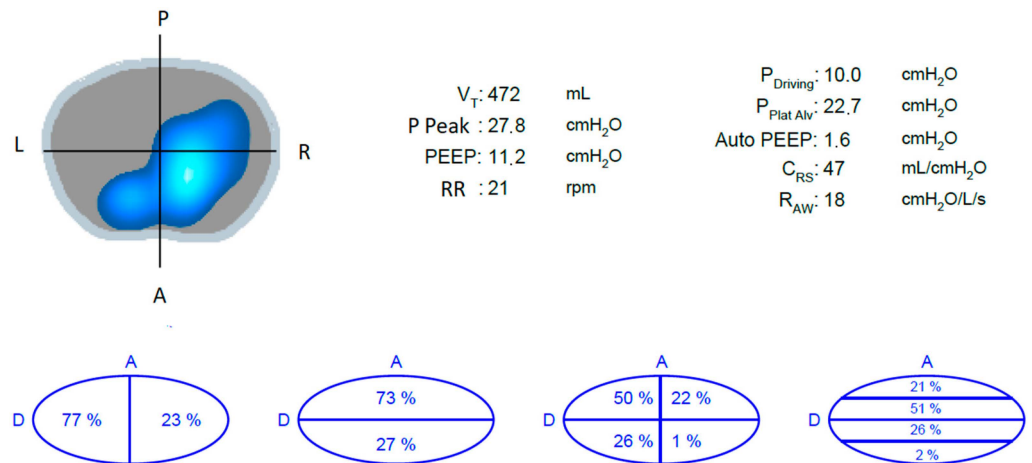


Figure 4. Regional distribution of ventilation with EIT.

### 4. Discussion

Based on the two case reports, it can be concluded that electrical impedance tomography (EIT) is a valuable tool for monitoring lung aeration during positioning, optimizing ventilation strategy, and reducing the need for invasive diagnostic procedures in patients with acute respiratory distress syndrome (ARDS). EIT is a non-invasive imaging technique that uses electrical conductivity measurements to create a dynamic image of the distribution of air in the lungs [6]. EIT has shown promising results in respiratory care as a

bedside monitoring tool for assessing lung function and optimizing mechanical ventilation parameters in critically ill patients [3]. One of the key advantages of EIT in respiratory care is its ability to monitor the distribution of pulmonary ventilation continuously and in real time. This is especially useful in managing acute respiratory distress syndrome (ARDS), where ventilation heterogeneity in the lung is associated with the existence of injurious mechanisms such as the collapse and cyclic opening of small airways and alveoli, and pulmonary overdistension. EIT has been used as a bedside tool to detect the presence of pneumothorax in real-time. In addition, EIT has been used to identify the effects of endotracheal suction on pulmonary volumes, where it showed a greater alveolar collapse, especially in the dorsal regions of the lung [6].

Several studies have also demonstrated the use of EIT in the assessment of lung perfusion. EIT estimates perfusion disturbances at the bedside and has been acquired using two methods: first-pass kinetics and blood volume determination. EIT may be a potential diagnostic bedside tool in the diagnosis and follow-up of acute pulmonary embolism [7,8].

In mechanical ventilation, EIT has been used to personalize care for COVID-19 patients. In one case study, EIT was used to monitor the patient's response to therapeutic interventions [4]. EIT-guided positive end-expiratory pressure (PEEP) titration has also been proposed as a technique to optimize mechanical ventilation parameters [9]. EIT enables real-time assessment of the distribution of ventilation at different levels of PEEP, enabling individualized PEEP titration [10]. A recent study showed that modern EIT devices provide an assessment of regional lung aeration and tidal volume and enable evaluation of the immediate effects of a change in ventilation or other therapeutic intervention [11].

EIT is also useful in detecting patient-ventilator dyssynchrony, which is common during mechanical ventilation and is usually related to adverse events such as weaning prolongation and increased mortality. EIT provides information on the distribution of ventilation during the respiratory cycle, which can be used to detect dyssynchrony and optimize ventilator settings. To quantify and compare the findings obtained from EIT, different indices have been developed from the "offline" analysis of the data. For example, the regional ventilation distribution index (RVDI) has been used to describe the distribution of ventilation within the lungs. The EIT global inhomogeneity index (EIT-GI) has been used to evaluate the heterogeneity of ventilation distribution. The EIT-derived end-expiratory lung impedance (EELI) has been used to assess the amount of aerated lung tissue at end-expiration [6].

Despite its numerous advantages, EIT also has several limitations. Firstly, the spatial resolution of EIT is relatively low compared with other imaging modalities, such as MRI and CT scans, which limits its use in some applications. Secondly, the accuracy of EIT images is dependent on several factors, such as the electrode placement, patient position, and the electrical properties of the tissues being imaged. Finally, the interpretation of EIT images requires specialized training and experience, which can limit its widespread use in clinical practice [12].

Future studies are needed to further investigate the efficacy of EIT in clinical practice and to identify new applications for the technique. In particular, studies are needed to determine the optimal electrode placement and current patterns for different imaging applications and to investigate the potential of combining EIT with other imaging modalities, such as MRI and CT scans. Additionally, more research is needed to identify the specific patient populations that may benefit the most from the use of EIT and to develop standardized protocols for the interpretation of EIT images [13].

## 5. Conclusions

In summary, EIT has shown great promise in respiratory care, especially in managing acute respiratory distress syndrome, assessing lung function, and optimizing mechanical ventilation parameters. EIT provides real-time monitoring of the distribution of pulmonary ventilation, detecting patient-ventilator dyssynchrony, and has also been used to assess lung perfusion. EIT-guided positive end-expiratory pressure (PEEP) titration has been

proposed as a technique to optimize mechanical ventilation parameters. While EIT delivers only relative values, different indices have been developed to quantify and compare the findings obtained from EIT. Despite its limitations, EIT has the potential to revolutionize the way medical imaging is performed and has the potential to improve patient outcomes by providing real-time, bedside monitoring.

**Author Contributions:** Conceptualization, G.C. and I.C.; methodology, I.C.; software, I.C.; validation, G.C., I.C., L.Z. and L.C.; formal analysis, I.C.; investigation, I.C.; resources, G.C.; data curation, I.C.; writing—original draft preparation, I.C.; writing—review and editing, G.C.; visualization, L.Z.; supervision, L.C.; project administration, G.C.; funding acquisition, I.C. All authors have read and agreed to the published version of the manuscript.

**Funding:** This research received no external funding.

**Institutional Review Board Statement:** The study was conducted in accordance with the Declaration of Helsinki, and ethical review and approval were waived for this study because these are two case reports.

**Informed Consent Statement:** Informed consent was obtained from all subjects involved in the study.

**Data Availability Statement:** No new data were created or analyzed in this study. Data sharing is not applicable to this article.

**Conflicts of Interest:** The authors declare no conflict of interest. The funders had no role in the design of the study; in the collection, analyses, or interpretation of data; in the writing of the manuscript; or in the decision to publish the results.

## References

1. Maciejewski, D.; Putowski, Z.; Czok, M.; Krzych, Ł. Electrical impedance tomography as a tool for monitoring mechanical ventilation. An introduction to the technique. *Adv. Med. Sci.* **2021**, *66*, 388–395. [[CrossRef](#)]
2. Walsh, B.K.; Smallwood, C.D. Electrical Impedance Tomography During Mechanical Ventilation. *Respir. Care* **2016**, *61*, 1417–1424. [[CrossRef](#)] [[PubMed](#)]
3. Costa, E.L.V.; Amato, M.B.P. Electrical Impedance Tomography in Critically Ill Patients. *Clin. Pulm. Med.* **2013**, *20*, 26. [[CrossRef](#)]
4. Zhao, Z.; Zhang, J.-S.; Chen, Y.-T.; Chang, H.-T.; Hsu, Y.-L.; Frerichs, I.; Adler, A. The use of electrical impedance tomography for individualized ventilation strategy in COVID-19: A case report. *BMC Pulm. Med.* **2021**, *21*, 38. [[CrossRef](#)] [[PubMed](#)]
5. Thomas, P. An Introduction to the Clinical Application and Interpretation of Electrical Impedance Tomography. *Respir. Care* **2022**, *67*, 721. [[CrossRef](#)]
6. Bachmann, M.C.; Morais, C.; Bugeo, G.; Bruhn, A.; Morales, A.; Borges, J.B.; Costa, E.; Retamal, J. Electrical impedance tomography in acute respiratory distress syndrome. *Crit. Care* **2018**, *22*, 263. [[CrossRef](#)]
7. Prins, S.A.; Weller, D.; Labout, J.A.M.; den Uil, C.A. Electrical Impedance Tomography As a Bedside Diagnostic Tool for Pulmonary Embolism. *Crit. Care Explor.* **2023**, *5*, e0843. [[CrossRef](#)]
8. Xu, M.; He, H.; Long, Y. Lung Perfusion Assessment by Bedside Electrical Impedance Tomography in Critically Ill Patients. *Front. Physiol.* **2021**, *12*, 748724. [[CrossRef](#)]
9. Sella, N.; Pettenuzzo, T.; Zarantonello, F.; Andreatta, G.; De Cassai, A.; Schiavolin, C.; Simoni, C.; Pasin, L.; Boscolo, A.; Navalesi, P. Electrical impedance tomography: A compass for the safe route to optimal PEEP. *Respir. Med.* **2021**, *187*, 106555. [[CrossRef](#)]
10. van der Zee, P.; Somhorst, P.; Endeman, H.; Gommers, D. Electrical Impedance Tomography for Positive End-Expiratory Pressure Titration in COVID-19-related Acute Respiratory Distress Syndrome. *Am. J. Respir. Crit. Care Med.* **2020**, *202*, 280–284. [[CrossRef](#)] [[PubMed](#)]
11. Frerichs, I.; Dargaville, P.A.; Dudykevych, T.; Rimensberger, P.C. Electrical impedance tomography: A method for monitoring regional lung aeration and tidal volume distribution? *Intensive Care Med.* **2003**, *29*, 2312–2316. [[CrossRef](#)] [[PubMed](#)]
12. Lundin, S.; Stenqvist, O. Electrical impedance tomography: Potentials and pitfalls. *Curr. Opin. Crit. Care* **2012**, *18*, 35–41. [[CrossRef](#)] [[PubMed](#)]
13. Brown, B.H. Electrical impedance tomography (EIT): A review. *J. Med. Eng. Technol.* **2003**, *27*, 97–108. [[CrossRef](#)]

**Disclaimer/Publisher's Note:** The statements, opinions and data contained in all publications are solely those of the individual author(s) and contributor(s) and not of MDPI and/or the editor(s). MDPI and/or the editor(s) disclaim responsibility for any injury to people or property resulting from any ideas, methods, instructions or products referred to in the content.