

## Article

# Multiparametric MRI Fusion-Guided Prostate Biopsy for Detection of Clinically Significant Prostate Cancer Eliminates the Systemic Prostate Biopsy

Augustinas Matulevičius<sup>1,2,3</sup>, Arnas Bakavičius<sup>3,4</sup> , Albertas Ulys<sup>2</sup>, Mantas Trakymas<sup>2</sup>, Jurgita Ušinskienė<sup>2</sup>, Ieva Naruševičiūtė<sup>2</sup>, Rasa Sabaliauskaitė<sup>1,2</sup> , Kristina Žukauskaitė<sup>1,2</sup>, Sonata Jarmalaitė<sup>1,2,\*</sup> and Feliksas Jankevičius<sup>3,4</sup>

<sup>1</sup> Institute of Biosciences, Life Sciences Center, Vilnius University, 10257 Vilnius, Lithuania

<sup>2</sup> National Cancer Institute, 08660 Vilnius, Lithuania

<sup>3</sup> Vilnius University Hospital Santaros Klinikos, 08661 Vilnius, Lithuania

<sup>4</sup> Faculty of Medicine, Institute of Clinical Medicine, Vilnius University, 03101 Vilnius, Lithuania

\* Correspondence: sonata.jarmalaitė@gf.vu.lt

**Abstract:** The primary objective of this study was to demonstrate the high accuracy of multiparametric magnetic resonance imaging and ultrasound fusion (mpMRI/US)-guided targeted prostate biopsy for the detection of clinically significant prostate cancer (PCa) and to show that adapted systematic biopsy (AdSB) does not provide additional benefit in detecting clinically significant prostate cancer (PCa). In total, 283 patients have been included in the study. All patients underwent the mpMRI/US biopsies, which have been performed with the “BioJet” fusion system (D&K Technologies, Barum, Germany) using the transperineal approach by a single interventional radiologist. Lesion-targeted and systematic biopsies have been done when 2–4 cores have been taken from each PI-RADS 3–5 lesion, followed by AdSB. This study demonstrated that targeted prostate biopsy is sufficient for safe and sensitive identification of clinically significant PCa in primary biopsy-naïve cases without the need to perform adapted systematic biopsy.

**Keywords:** prostate cancer; mpMRI/US; TRUS-guided biopsy



**Citation:** Matulevičius, A.; Bakavičius, A.; Ulys, A.; Trakymas, M.; Ušinskienė, J.; Naruševičiūtė, I.; Sabaliauskaitė, R.; Žukauskaitė, K.; Jarmalaitė, S.; Jankevičius, F. Multiparametric MRI Fusion-Guided Prostate Biopsy for Detection of Clinically Significant Prostate Cancer Eliminates the Systemic Prostate Biopsy. *Appl. Sci.* **2022**, *12*, 10151. <https://doi.org/10.3390/app121910151>

Academic Editors: Matteo Ferro and Biagio Barone

Received: 12 August 2022

Accepted: 7 October 2022

Published: 9 October 2022

**Publisher's Note:** MDPI stays neutral with regard to jurisdictional claims in published maps and institutional affiliations.



**Copyright:** © 2022 by the authors. Licensee MDPI, Basel, Switzerland. This article is an open access article distributed under the terms and conditions of the Creative Commons Attribution (CC BY) license (<https://creativecommons.org/licenses/by/4.0/>).

## 1. Introduction

Prostate cancer (PCa) is the most prevalent oncological disease in males in Western Europe, including Lithuania [1]. Before the multiparametric magnetic resonance imaging (mpMRI) era, the principal method to diagnose PCa and determine the risk was a systematic 12-core transrectal ultrasound (TRUS)-guided biopsy [2]. Unfortunately, TRUS-guided biopsy is performed randomly, without targeting the tumor, and leads to over-diagnosing of clinically insignificant cancer in up to 50% of cases and not diagnosing clinically significant cancer in up to 18% of men, particularly if the tumor is in the apical or anterior regions of the prostate [3,4]. In addition, TRUS-guided biopsy causes side effects including bleeding, pain, and severe systematic infection [5,6]. To tackle this problem, new methods are being established which lead to increased biopsy accuracy based on the prostate mpMRI. One of the most promising and easily accessible prostate biopsy techniques is the mpMRI and ultrasound fusion (mpMRI/US)-guided prostate biopsy, which uses a specially designed system and software to fuse mpMRI images with real-time TRUS [7]. This technique allows us to target suspicious lesions much more accurately than systemic TRUS-guided prostate biopsy, a little bit more accurately than transrectal cognitive guidance prostate biopsy, and gives advantages of this tactic mainly due to fewer biopsy cores taken that give lower rates of complications and better tolerance for the patient [8–10]. Based on the Cochrane meta-analysis, MRT-FIRST and 4M clinical trials, the absolute added value of systematic biopsy for the detection of clinically significant PCa is known to be lower than that of

targeted biopsy [11]. Nowadays, it is important to get an answer whether targeted prostate biopsy enhances the detection of clinically significant PCa and safely obviates the need for systemic biopsy in primary patients, as some controversies remain [12,13]. This study aimed to prove the high accuracy of mpMRI/US-guided targeted prostate biopsy for the detection of clinically significant PCa and demonstrate that adapted systematic biopsy (AdSB) does not provide additional benefit for the detection of clinically significant PCa.

## 2. Materials and Methods

### 2.1. Patients and Samples

All patients who underwent primary mpMRI/US-targeted prostate biopsy for suspected localized PCa at the National Cancer Institute (Lithuania) between November 2019 and February 2022 were included in the study. The Regional Bioethics Committee approved the study (No. 2019/11-166-654 and 2020-LP-68), and informed consent was obtained from all participants.

All 1.5T and 3T mpMRI scans have been performed in the same institution according to the standardized protocol, while external images have been re-evaluated pre-operatively. The PI-RADSv2.1 scoring system was used to report mpMRI results. Contouring of the prostate margins and target lesions was performed by two experienced radiologists using the transverse T2 TSE images. The mpMRI/US biopsies have been performed with the “BioJet” fusion system (D&K Technologies, Barum, Germany) using the transperineal approach by a single interventional radiologist. Furthermore, we used this technique that avoids rectal wall puncturing, which leads to a near-zero risk of infection [14]. For all patients, a prostate biopsy was performed under general anesthesia. Only 1 g of Cefazolin was used during the procedure for the prevention of UTI, based on the findings of a literature meta-analysis [15].

For all patients, lesion-targeted and systematic biopsies have been performed. Lesion-targeted biopsy 2-4 cores have been taken from each PI-RADS 3-5 lesion, followed by a systemic 12-core biopsy ignoring index lesions. Thus, the median number of cores taken from the lesions by the targeted prostate biopsy was 4 (DS = 1.68), while 12 cores in median (SD = 4.8) were taken during systematic sampling. In general, the median number of biopsy cores performed at one procedure was 16 (SD = 4.5). Slight biopsy variations were allowed in large-size prostates and/or large-size target lesions. All biopsy samples have been evaluated by urological pathologists from the National Center of Pathology (Lithuania) and reported according to the EAU recommendations [16]. Clinically significant PCa was defined as ISUP grade group  $\geq 2$  detected at any biopsy core.

### 2.2. Statistical Analysis

In our study, descriptive statistics were used to outline main patient characteristics (age, PSA, PSA density (PSAD), prostate volume, and mpMRI findings). According to the PI-RADS score, all patients were divided into two groups: clinically significant cancer with ISUP  $\geq 2$  with a PI-RADS score  $\geq 3$  and clinically insignificant PCa. Unpaired *t*-tests were used to assess the differences between these groups, and values were given as mean  $\pm$  standard deviation (SD). Sensitivity, specificity, negative predictive value (NPV), and positive predictive value (PPV) of mpMRI/US-guided biopsy in diagnosing clinically significant PCa (ISUP  $\geq 2$ ) with a PI-RADS score  $\geq 3$  were evaluated with providing supremacy to the dominant lesion in each patient. P-value was calculated as the probability that the observed sample area under the Receiver Operating Characteristic (ROC) curve is found when, in fact, the true area under the ROC curve is 0.5 (null hypothesis: area = 0.5). The significance level of  $p < 0.05$  was used for the evaluation of statistical hypotheses. The combined histological results of MRI/US-guided and 12-core systematic biopsy cores were used as a reference. All statistical tests were performed using SPSS 28.0 (IBM Corp., Armonk, NY, USA).

### 3. Results

#### 3.1. Comparison of Diagnostic Values of Targeted and Systematic Prostate Biopsies

In total, 283 patients have been included in the study (17 cases were excluded due to the clinical and anatomical reasons; data of these cases are not shown). Clinical and radiological characteristics of the study cohort are provided in Table 1.

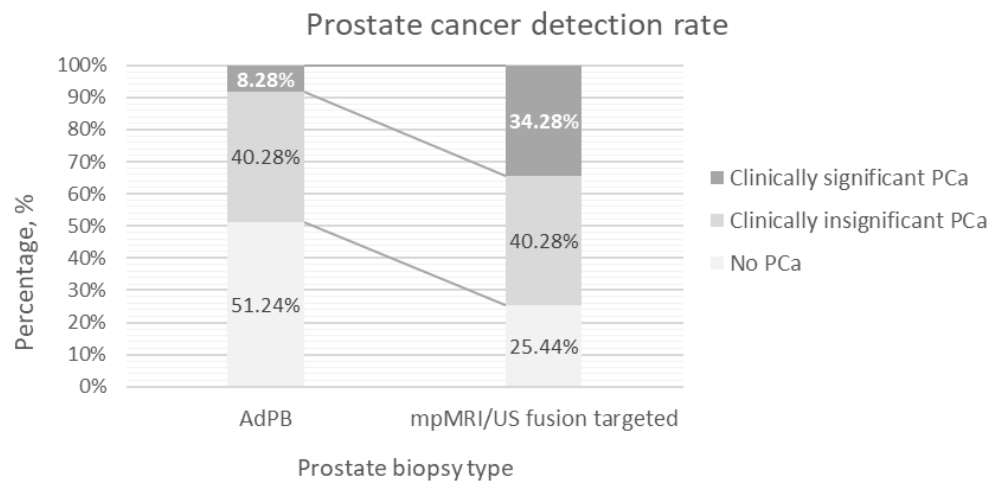
**Table 1.** Clinical and radiological characteristics of the study cohort. PSA—prostate-specific antigen, mpMRI—multi-parametric magnetic resonance imaging, ADC—apparent diffusion coefficient, ISUP—The International Society of Urological Pathology, GG—prostate cancer grade group.

Variable	Patients ( <i>n</i> = 283)	
Age, years	Mean	63.59
	SD	7.41
PSA, ng/mL	Mean	7.67
	SD	5.89
PSA density, ng/mL/cc	Mean	0.19
	SD	0.49
Prostate volume, mL	Mean	50.84
	SD	23.18
mpMRI targets quantity, <i>n</i>	Mean	1.51
	SD	0.65
mpMRI target volume, mL	Mean	1.21
	SD	1.96
mpMRI ADC value $\mu\text{m}^2/\text{s}$	Mean	634.56
	SD	204.85
PI-RADS V2.1 score, <i>n</i> (%)	3	11 (3.9%)
	4	190 (67.1%)
	5	82 (29.0%)
ISUP grade group, <i>n</i> (%)	No PCa	56 (19.8%)
	GG1	130 (45.9%)
	GG2	62 (21.9%)
	GG3	28 (9.9%)
	GG4	7 (2.5%)

The overall detection rate of PCa in the cohort was 80.21% (227/283), while targeted MRI/US-guided biopsy and adapted systematic biopsy detected PCa in 74.56% (211/283) and 48.76% (138/283) of patients ( $p < 0.001$ ), respectively.

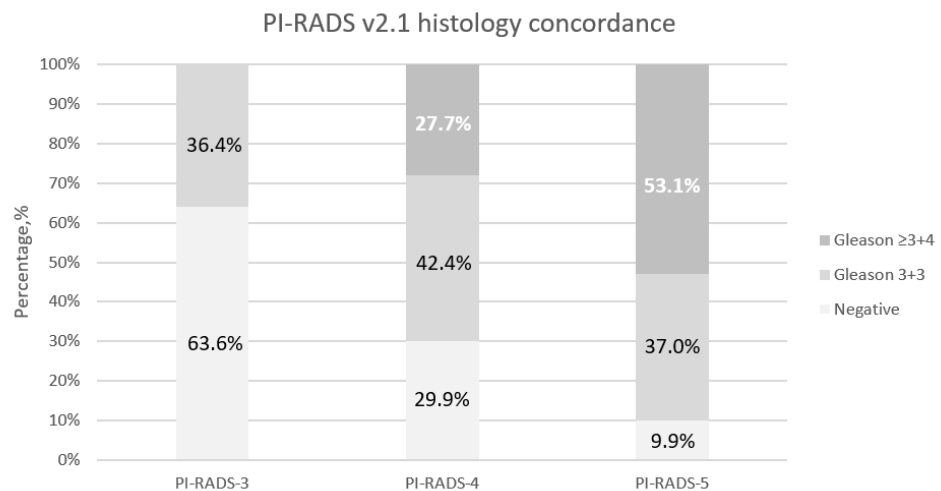
The clinically significant disease was detected in 34.28% (97/283) of patients undergoing prostate biopsy. The detection rate of clinically significant disease by targeted MRI/US-guided biopsy was 34.28% (97/283), which accounted for 45.97% (97/211) of all PCa diagnoses. Meanwhile, the detection rate of clinically significant disease after AdSB was significantly lower (8.48%; 24/283;  $p < 0.001$ ), which accounted just for a small number 17.39%; 24/138) of all PCa cases in comparison to targeted methodology only (17.39% vs. 45.97%;  $p < 0.001$  Figure 1).

Among patients with clinically significant PCa detected by targeted prostate biopsy ( $n = 97$ ), AdSB reconfirmed clinically significant PCa diagnosis just for 24.74% ( $n = 24$ ) of patients. In patients for whom no clinically significant PCa was detected by targeted biopsy, also, no clinically significant cancer was detected by AdSB. AdSB identified 16 additional cases of clinically insignificant PCa for patients with no signs of cancer on targeted prostate biopsy.



**Figure 1.** The comparison of diagnostic value of targeted and systematic prostate biopsy ( $n = 283$ ). AdPB—12-core systematic biopsy ignoring index lesions, mpMRI/US fusion targeted prostate biopsy.

Based on the PI-RADS v2.1 system, the detection rate of clinically significant disease after the targeted prostate biopsy was dependent on PI-RADS’s group and was predominant among cases with PI-RADS 5 (PI-RADS 3 vs. PI-RADS 4 vs. PI-RADS 5, while  $p < 0.001$ ; Figure 2). Meanwhile, the results of AdSB showed no associations with PI-RADS scores of mpMRI (PI-RADS-3 0.00% vs. PI-RADS-4 7.92% vs. PI-RADS-5 11.00%,  $p = 0.415$ ).



**Figure 2.** Concordance between PI-RADS v2.1 category and histology after targeted biopsy. Note—statistically significant association between the proportion of clinically significant lesions (Gleason 3 + 4 or higher) for each category of PI-RADS v2.1 ( $p < 0.001$ ,  $n = 283$ ).

ISUP grade group score was also predominantly higher in the PI-RADS 5 group as compared to PI-RADS 4 and PIRADS 3 groups, and the results are shown in Table 2.

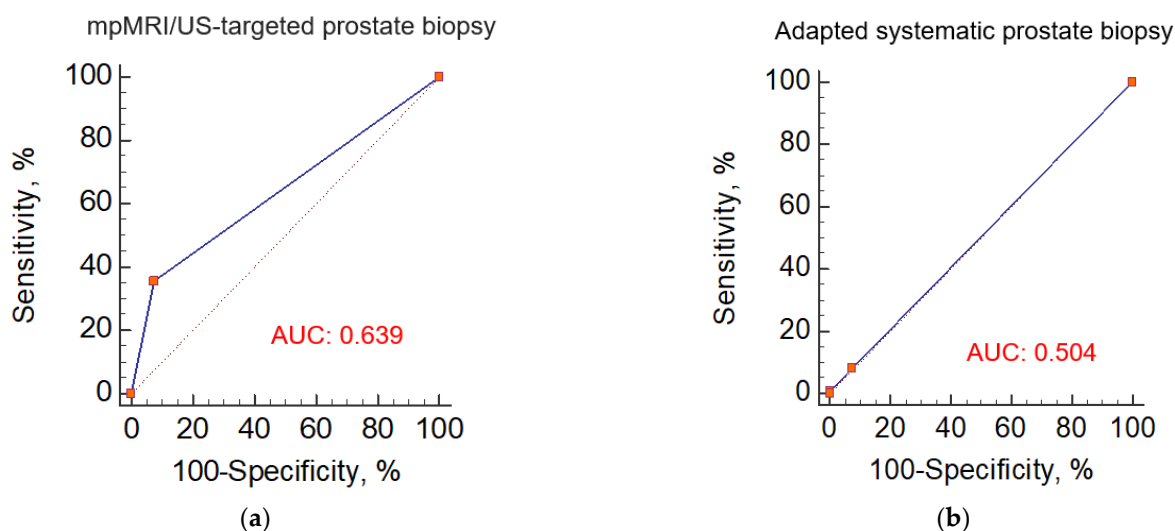
**Table 2.** Different prostate cancer grade group detection rates according to PI-RADS scores. GG—prostate cancer grade group.

		PI-RADS-3		PI-RADS-4		PI-RADS-5		Total, n = 283	
		n	%	n	%	n	%	n	%
GG score after targeted prostate biopsy	No PCa	7	63.63	57	30.00	8	9.76	72	25.44
	GG1	4	36.37	80	42.10	30	36.59	114	40.28
	GG2	0	0.0	35	18.42	27	32.92	62	21.90
	GG3	0	0.0	16	8.42	12	14.63	28	9.89
	GG4	0	0.0	2	1.05	5	6.10	7	2.47
Total		11	100.00	190	100.00	82	100.00	283	100.00

Chi-Square Tests, the value of  $p < 0.001$

PI-RADS v2.1—prostate imaging reporting and data system version 2.1

When using a PI-RADS v2.1 score  $\geq 4$  as a positive test result to detect ISUP  $\geq 2$  PCa, the sensitivity and specificity of MRI/US-targeted biopsy reached 35.56% and 92.31% with a Youden-selected cut-off value of PI-RADS v2.1  $\geq 4$  (area under the curve (AUC) = 0.639 (95% confidence interval (CI): 0.6–0.7) Figure 3). NPV of MRI/US-targeted biopsy was 7.02% (95% CI: 3.792–11.677), while PPV was 98.88% (95% CI: 94.22–99.96,  $p = 0.0007$ ).



**Figure 3.** Sensitivity and specificity of targeted and systematic biopsy in diagnosing ISUP  $\geq 2$  prostate cancer by (a) mpMRI/US-targeted prostate biopsy; (b) Adapted systematic prostate biopsy. AUC—Area Under the Curve.

Using the same approach, the sensitivity and specificity of AdSB group were 8.52% and 92.31%, respectively, with a Youden-selected cut-off value of PI-RADS v2.1  $\geq 4$  (AUC = 0.504; 95% CI: 0.6–0.7 Figure 3). The NPV of the method was 5.04% (95% CI: 2.717–8.459), and PPV was 95.47% (95% CI: 78.33–99.85;  $p = 0.910$ ).

**3.2. Associations with Clinical and Radiological Variables**

Statistical analysis revealed that the patients with clinically significant PCa were significantly older (65.08 (SD = 7.24) vs. 62.82 (SD = 7.4) years,  $p = 0.007$ ) and harbored significantly lower prostate volume (44.25 (SD = 17.83) vs. 54.27 (SD = 24.89), mL,  $p < 0.001$ ) as compared to cases with the clinically insignificant disease. No significant difference was identified in PSA, PSA density level, and target lesion size between targeted and systematic biopsy groups (all  $p > 0.05$ ).

Most cases with clinically significant disease 54.64% (53/97) were detected by the first targeted core, while the second and third targeted samples detected an extra 16.49% (16/97)

and 28.87% (28/97) of cases, respectively. For 78.95% of patients with additional biopsies, the regions of interest (ROI) were greater than 0.5 cm<sup>3</sup> or 8 mm in diameter. According to mpMRI, the most common ROIs were in the peripheral zone of the prostate (66.10%), followed by the transition zone (27.51%) and fibromuscular stroma (6.39%). There were no statistically significant differences between clinically relevant and non-significant PCa detection rates using target and AdSB, depending on lesion location on mpMRI.

#### 4. Discussion

Systematic ultrasound-guided biopsy leads to sampling errors that delay the diagnosis of clinically significant PCa, overdiagnosis of clinically insignificant PCa, and misclassification of the disease. Based on literature data, it is known that the detection rate of clinically significant PCa in primary patients undergoing random systematic biopsy is only 23% [17]. It is known that repeated biopsies give even worse results: secondary systematic biopsy—14% and third repeated biopsy—6% for clinically significant PCa detection [18]. In this study, the clinically significant disease was detected in 34.28% of cases by targeted biopsy only; meanwhile, the detection rate of clinically significant disease after systematic biopsy only was just 8.48%. These results have essentially the same trend compared to the data reported in the literature. According to the PRECISION trial, men who underwent MRI-targeted biopsy had a significantly higher rate of ISUP  $\geq 2$  cancer detection than those who underwent systemic biopsy (38% vs. 26%,  $p = 0.005$ , detection ratio 1.46) [12]. In the mpMRI era, saturating prostate biopsy also has rare indications and is used only in exceptional cases, i.e., secondary patients with negative mpMRI (PI-RADS 1-2 scores) and elevated PSA. According to the literature, the frequency of detection of clinically significant prostate cancer after saturation biopsy (24 biopsy cores) is only 16% [19].

It has been reported that 8–24% of clinically significant PCa may go unnoticed on mpMRI when a tumor has been diagnosed following radical prostatectomy [20]. However, according to our data, the overall detection rate of PCa improved only from 74.56% to 80.21% when an adapted systematic prostate biopsy was performed. A combination of systematic and targeted biopsy schemes has previously been suggested to provide the highest PCa detection rate, and our results are consistent with this fact [21]. However, based on our results, adapted systematic prostate biopsy improved the overall detection rate of PCa but did not provide additional benefit for the detection of clinically significant disease.

The European Association of Urology recommends for primary patients to perform targeted plus systematic biopsy and targeted-only biopsy for secondary patients if their PIRADS score is  $\geq 3$ , but our data suggest that only targeted biopsy could be performed safely in biopsy-naïve patients with a PIRADS score  $\geq 3$  by avoiding systematic biopsy and maintaining a high clinically significant PCa detection rate. We substantiate this on the fact that in patients for whom no clinically significant PCa was detected by targeted prostate biopsy, also, no clinically significant cancer was detected by adapted systemic prostate biopsy. Other randomized Controlled Trials focusing on primary patients with a positive MRI found that targeted biopsy detected significantly more ISUP  $>$  grade 2 cancers than a systemic biopsy (risk difference,  $-0.11$  (95% CI:  $-0.2-0.0$ );  $p = 0.05$ ) [22]. Another extremely important fact is that targeted biopsy without systematic biopsy reduces the detection of ISUP grade 1 PCa compared to systematic biopsy. In the PRECISION and 4M trials, the detection rate of clinically insignificant PCa was significantly lower in the targeted biopsy group as compared to the systematic-only biopsy group (9% vs. 22%,  $p < 0.001$ , detection ratio of 0.41 for PRECISION; 14% vs. 25%,  $p < 0.001$ , detection ratio of 0.56 for 4M) [12,22]. According to the PROMIS study, a negative MRI could avoid unnecessary TRUS biopsies in 28% of patients, while 21% would be confirmed based on true negative results, but 7% would not be justified based on false negative results [23]. However, according to the presented results, it is not possible to assess whether these clinically significant PCa detected by targeted-only biopsy would have been detected by additional systematic biopsy. Moreover, we cannot ignore the fact that the number of biopsy cores performed by targeted biopsy is significantly lower compared to a systematic biopsy

(median number of cores: 2–7 vs. median number of cores: 8–15), and the detection ratio (i.e., the ratio of the detection rates obtained by targeted biopsy alone and by systematic biopsy alone) is in the superiority of targeted biopsy (1.12 (95% CI: 1.02–1.23) for ISUP grade  $\geq 2$  PCa and 1.20 (95% CI: 1.06–1.36) for ISUP grade  $\geq 3$  PCa) [24]. This fact is also reflected in our study.

An equally important question remains to be answered as to how many targeted biopsy cores are required for the detection of clinically significant disease during transperineal MRI/US-guided prostate biopsy. Based on the literature, in men undergoing mpMRI/US-guided biopsy, the first two biopsy cores diagnose the most clinically significant cancers. However, there remains a proportion of men who would benefit from additional diagnostic cores, particularly those with foci greater than 8 mm in diameter [25]. In our trial, the second and third targeted samples detected an extra 16.49% and 28.87% of clinically significant PCa cases. These additional samples detected 45.36% of all clinically significant PCa cases, indicating that at least three targeted biopsy cores might be reasonable for patients with an ROI greater than 0.5 cm<sup>3</sup> or 8 mm in diameter.

The main limitation of this study is the relatively small sample size, especially of the PI-RADS 3 group. We cannot ignore the fact that 19.78% of all cases with PCa have not been diagnosed by both types of biopsy, and we do not know how many truly false negative findings we have. To confirm this fact, a repeated biopsy will be performed for this patient in surveillance protocol.

## 5. Conclusions

In the mpMRI era, systematic prostate biopsy loses its relevance in clinical practice to select the appropriate treatment for PCa patients. The frequency of clinically insignificant PCa detection and over-diagnosis rates can be reduced by completely replacing adapted systematic biopsy with targeted MRI/US-guided prostate biopsy. This study demonstrates that targeted prostate biopsy is sufficient for safe and sensitive identification of clinically significant PCa in primary biopsy-naïve cases without the need to perform an adapted systematic biopsy.

**Author Contributions:** Conceptualization, S.J. and F.J.; methodology, F.J., A.U., M.T. and J.U.; formal analysis, A.M., M.T., J.U., I.N. and K.Ž.; investigation, A.M., A.B., M.T., J.U. and I.N.; resources, A.U., J.U. and R.S.; data curation, A.U., J.U., F.J. and S.J.; writing—original draft preparation, A.M., A.B., R.S. and K.Ž.; supervision, F.J. and S.J.; writing—review and editing, F.J. and S.J.; visualization, R.S. and K.Ž.; project administration, J.U., A.U. and R.S.; funding acquisition, F.J. and S.J. All authors have read and agreed to the published version of the manuscript.

**Funding:** This work was funded by the 2014–2020 European Union Structural Funds according to the activity “Intelligence. Joint science-business projects” grant No. J05-LVPA-K-04–0029.

**Institutional Review Board Statement:** The study was conducted in accordance with the Declaration of Helsinki and approved by the Regional Bioethics Committee (No. 2019/11-166-654 and 2020-LP-68).

**Informed Consent Statement:** Written informed consent was obtained from each participant of the study after a full explanation of the purpose and nature of all procedures used.

**Data Availability Statement:** Not applicable.

**Conflicts of Interest:** The authors declare that no conflict of interest could be perceived as prejudicing the impartiality of the research reported.

## References

1. European Cancer Observatory, International Agency for Research on Cancer, World Health Organization. Available online: <https://gco.iarc.fr/> (accessed on 5 July 2022).
2. Ouzzane, A.; Coloby, P.; Mignard, J.P.; Allegre, J.P.; Soulie, M.; Rebillard, X.; Salomon, L.; Villers, A.; Committee of Infectious Diseases of the French Association of Urology (CIAFU); Committee of Cancerology of the French Association of Urology (CCAFU). Guidelines for prostatic biopsies best practice. *Prog. Urol.* **2011**, *21*, 18–28. [[CrossRef](#)] [[PubMed](#)]
3. Loeb, S.; Bjurlin, M.A.; Nicholson, J.; Tammela, T.L.; Penson, D.F.; Carter, H.B.; Carroll, P.; Etzioni, R. Overdiagnosis and overtreatment of prostate cancer. *Eur. Urol.* **2014**, *65*, 1046–1055. [[CrossRef](#)] [[PubMed](#)]

4. Wilt, T.J.; Brawer, M.K.; Jones, K.M.; Barry, M.J.; Aronson, W.J.; Fox, S.; Gingrich, J.R.; Wei, J.T.; Gilhooly, P.; Grob, B.M.; et al. Radical prostatectomy versus observation for localized prostate cancer. *N. Engl. J. Med.* **2012**, *367*, 203–213. [[CrossRef](#)] [[PubMed](#)]
5. Singh, S.; Dorairajan, L.N.; Manikandan, R.; Sreerag, K.S.; Sunil, K.; Kant, D.U.; Tepukiel, Z. Comparison of infective complications in Transperineal versus Transrectal Ultrasound Guided Prostatic Biopsy in patients suspected to have prostate cancer. *Indian J. Urol.* **2017**, *33*, S43.
6. Pilatz, A.; Dimitropoulos, K.; Veeratterapillay, R.; Yuan, Y.; Omar, M.I.; MacLennan, S.; Cai, T.; Bruyère, F.; Bartoletti, R.; Köves, B.; et al. Antibiotic Prophylaxis for the Prevention of Infectious Complications following Prostate Biopsy: A Systematic Review and Meta-Analysis. *J. Urol.* **2020**, *204*, 224–230. [[CrossRef](#)] [[PubMed](#)]
7. Siddiqui, M.M.; Rais-Bahrami, S.; Truong, H.; Stamatakis, L.; Vourganti, S.; Nix, J.; Hoang, A.N.; Walton-Diaz, A.; Shuch, B.; Weintraub, M.; et al. Magnetic resonance imaging/ultrasound-fusion biopsy significantly upgrades prostate cancer versus systematic 12-core transrectal ultrasound biopsy. *Eur. Urol.* **2013**, *64*, 713–719. [[CrossRef](#)] [[PubMed](#)]
8. Watts, K.L.; Frechette, L.; Muller, B.; Ilinksy, D.; Kovac, E.; Sankin, A.; Aboumohamed, A. Systematic review and meta-analysis comparing cognitive vs. image-guided fusion prostate biopsy for the detection of prostate cancer. *Urol. Oncol.* **2020**, *38*, 19–25. [[CrossRef](#)] [[PubMed](#)]
9. Pepdjonovic, L.; Tan, G.H.; Huang, S.; Mann, S.; Frydenberg, M.; Moon, D.; Hanegbi, U.; Landau, A.; Snow, R.; Grummet, J. Zero hospital admissions for infection after 577 transperineal prostate biopsies using single-dose cephalosporin prophylaxis. *World J. Urol.* **2017**, *35*, 1199–1203. [[CrossRef](#)] [[PubMed](#)]
10. Bass, E.J.; Freeman, A.; Jameson, C.; Punwani, S.; Moore, C.M.; Arya, M.; Emberton, M.; Ahmed, H. Prostate cancer diagnostic pathway: Is a one-stop cognitive MRI targeted biopsy service a realistic goal in everyday practice? A pilot cohort in a tertiary referral centre in the UK. *BMJ Open* **2018**, *8*, 1–8. [[CrossRef](#)]
11. Rouvière, O.; Puech, P.; Renard-Penna, R.; Claudon, M.; Roy, C.; Mège-Lechevallier, F.; Decaussin-Petrucci, M.; Dubreuil-Chambardel, M.; Magaud, L.; Remontet, L.; et al. Use of prostate systematic and targeted biopsy on the basis of multiparametric MRI in biopsy-naïve patients (MRI-FIRST): A prospective, multicentre, paired diagnostic study. *Lancet Oncol.* **2019**, *20*, 100–109. [[CrossRef](#)]
12. Kasivisvanathan, V.; Rannikko, A.S.; Borghi, M.; Panebianco, V.; Mynderse, L.A.; Vaarala, M.H.; Briganti, A.; Budäus, L.; Hellawell, G.; Hindley, R.G.; et al. MRI-Targeted or Standard Biopsy for Prostate-Cancer Diagnosis. *N. Engl. J. Med.* **2018**, *19*, 1767–1777. [[CrossRef](#)]
13. Ahdoot, M.; Wilbur, A.R.; Reese, S.E.; Lebastchi, A.H.; Mehralivand, S.; Gomella, P.T.; Bloom, J.; Gurrarn, S.; Siddiqui, M.; Pinsky, P.; et al. MRI-Targeted, Systematic, and Combined Biopsy for Prostate Cancer Diagnosis. *N. Engl. J. Med.* **2020**, *10*, 917–928. [[CrossRef](#)] [[PubMed](#)]
14. Borghesi, M.; Ahmed, H.; Nam, R.; Schaeffer, E.; Schiavina, R.; Taneja, S.; Weidner, W.; Loeb, S. Complications After Systematic, Random, and Image-guided Prostate Biopsy. *Eur. Urol.* **2017**, *71*, 353–365. [[CrossRef](#)] [[PubMed](#)]
15. Basourakos, S.P.; Alshak, M.N.; Lewicki, P.J.; Cheng, E.; Tzeng, M.; DeRosa, A.P.; Allaway, M.J.; Ross, A.E.; Schaeffer, E.M.; Patel, H.D.; et al. Role of Prophylactic Antibiotics in Transperineal Prostate Biopsy: A Systematic Review and Meta-analysis. *Eur. Urol. Open Sci.* **2022**, *37*, 53–63. [[CrossRef](#)]
16. van Leenders, G.J.; van der Kwast, T.H.; Grignon, D.J.; Evans, A.J.; Kristiansen, G.; Kweldam, C.F.; Litjens, G.; McKenney, J.K.; Melamed, J.; Mottet, N.; et al. The 2019 International Society of Urological Pathology (ISUP) Consensus Conference on Grading of Prostatic Carcinoma. *Am. J. Surg. Pathol.* **2020**, *44*, 87–99. [[CrossRef](#)] [[PubMed](#)]
17. Ukimura, O.; Coleman, J.A.; de la Taille, A.; Emberton, M.; Epstein, J.I.; Freedland, S.J.; Giannarini, G.; Kibel, A.S.; Montironi, R.; Ploussard, G.; et al. Contemporary role of systematic prostate biopsies: Indications, techniques, and implications for patient care. *Eur. Urol.* **2013**, *63*, 214–230. [[CrossRef](#)]
18. Djavan, B.O.; Ravery, V.; Zlotta, A.; Dobronski, P.; Dobrovits, M.; Fakhari, M.; Seitz, C.; Susani, M.; Borkowski, A.; Boccon-Gibod, L.; et al. Prospective evaluation of prostate cancer detected on biopsies 1, 2, 3, and 4: When should we stop? *J. Urol.* **2001**, *166*, 1679–1683. [[CrossRef](#)]
19. Medina, A.A.; Rodríguez, R.R.; Hernández, M.R.; Alcaraz, M.M.; Barreras, S.G.; Conejo, G.F.; Poblador, A.F.; Mayayo, E.S.; Revilla, F.J. Identifying Risk Factors for MRI-Invisible Prostate Cancer in Patients Undergoing Transperineal Saturation Biopsy. *Res. Rep. Urol.* **2021**, *13*, 723–731.
20. Le, J.D.; Tan, N.; Shkolyar, E.; Lu, D.Y.; Kwan, L.; Marks, L.S.; Huang, J.; Margolis, D.J.; Raman, S.S.; Reiter, R.E. Multifocality and prostate cancer detection by multiparametric magnetic resonance imaging: Correlation with whole-mount histopathology. *Eur. Urol.* **2015**, *67*, 569–576. [[CrossRef](#)]
21. Van Hove, A.; Savoie, P.-H.; Maurin, C.; Brunelle, S.; Gravis, G.; Salem, N.; Walz, J. Comparison of image-guided targeted biopsies versus systematic randomized biopsies in the detection of prostate cancer: A systematic literature review of well-designed studies. *World J. Urol.* **2014**, *32*, 847–858. [[CrossRef](#)]
22. van der Leest, M.; Cornel, E.; Israël, B.; Hendriks, R.; Padhani, A.R.; Hoogenboom, M.; Zamecnik, P.; Bakker, D.; Setiasti, A.Y.; Veltman, J.; et al. Head-to-head Comparison of Transrectal Ultrasound-guided Prostate Biopsy Versus Multiparametric Prostate Resonance Imaging with Subsequent Magnetic Resonance-guided Biopsy in Biopsy-naïve Men with Elevated Prostate-specific Antigen: A Large Prospective Multicenter Clinical Study. *Eur. Urol.* **2019**, *75*, 570–578. [[PubMed](#)]



23. Ahmed, H.U.; El-Shater Bosaily, A.; Brown, L.C.; Gabe, R.; Kaplan, R.; Parmar, M.K.; Collaco-Moraes, Y.; Ward, K.; Hindley, R.G.; Freeman, A.; et al. Diagnostic accuracy of multi-parametric MRI and TRUS biopsy in prostate cancer (PROMIS): A paired validating confirmatory study. *Lancet* **2017**, *389*, 815–822. [[CrossRef](#)]
24. Drost, F.H.; Osses, D.F.; Nieboer, D.; Steyerberg, E.W.; Bangma, C.H.; Roobol, M.J.; Schoots, I.G. Prostate MRI, with or without MRI-targeted biopsy, and systematic biopsy for detecting prostate cancer. *Cochrane Database Syst. Rev.* **2019**, *4*, CD012663. [[CrossRef](#)]
25. Kenigsberg, A.P.; Renson, A.; Rosenkrantz, A.B.; Huang, R.; Wysock, J.S.; Taneja, S.; Bjurlin, M.A. Optimizing the Number of Cores Targeted During Prostate Magnetic Resonance Imaging Fusion Target Biopsy. *Eur. Urol. Oncol.* **2018**, *5*, 418–425. [[CrossRef](#)] [[PubMed](#)]