applied sciences

MDPI

Review

Stents in Congenital Heart Disease: State of the Art and Future Scenarios

Alma Brambilla [1], Giancarlo Pennati [2,*], Lorenza Petrini [1] and Francesca Berti [2]

[1] Department of Civil and Environmental Engineering, Politecnico di Milano, 20133 Milan, Italy; alma.brambilla@polimi.it (A.B.); lorenza.petrini@polimi.it (L.P.)
[2] Department of Chemistry, Materials and Chemical Engineering "G. Natta" (LaBS), Politecnico di Milano, 20133 Milan, Italy; francesca.berti@polimi.it
* Correspondence: giancarlo.pennati@polimi.it; Tel.: +39-02-2399-4223

Abstract: Stents are tubular meshed endoprostheses implanted mini-invasively through a transcatheter intervention to guarantee the patency of body conduits, mainly in cardiovascular applications. In pediatric cardiology, stenting has become an accepted procedure in the treatment of congenital heart disease (CHD) as an alternative to open-heart surgery. CHD refers to a range of defects affecting the heart's structure and function arising from abnormal development during pregnancy. While during fetal life, the presence of additional shunts allows for the establishment of parallel circulation and survival of gestation, CHD is not compatible with extrauterine life, and medical intervention is required soon after birth. This review aims to discuss the state of the art of stenting in CHD. Despite the severity of these pathologies, investment from the industry remains limited due to the restricted number of cases, and dedicated devices are still missing. As a consequence, commercially available adult stents are commonly exploited on an off-label basis in newborns without any optimization for the specific anatomy and required function. In this review, a classification of the available stents is provided, resuming the manufacturing technologies, materials, and geometrical aspects to obtain the target biomechanical performance. After analyzing the fetal circulation, different forms of CHD amenable to stenting are considered, collecting the stents currently adopted and discussing the clinical outcomes to outline the features of an ideal device.

Keywords: pediatric cardiology; newborn circulation; hypoplastic left heart syndrome; aortic coarctation; pulmonary atresia; pulmonary artery stenosis; ductus arteriosus; transcatheter intervention; orphan device; ideal stent design

check for updates

Citation: Brambilla, A.; Pennati, G.; Petrini, L.; Berti, F. Stents in Congenital Heart Disease: State of the Art and Future Scenarios. *Appl. Sci.* **2023**, *13*, 9692. https://doi.org/10.3390/app13179692

Academic Editors: Salvatore Pasta and Miquel Aguirre

Received: 31 July 2023
Revised: 22 August 2023
Accepted: 25 August 2023
Published: 28 August 2023

1. Introduction

A stent is a tubular meshed endoprosthesis that is inserted through a transcatheter intervention, to sustain pathological vessels transporting fluids in the human body, providing radial support, and maintaining their patency. They can be used in a variety of diseases affecting human conduits, among which are coronaries, peripheral and cerebral arteries (in the cardiovascular field), ureter, prostate, colon, esophagus, and bile duct [1–5].

Infants suffering from congenital heart diseases (CHDs) are often palliated with an invasive multi-stage surgical treatment that might start in their first weeks of life: the final aim is to reconstruct all the undeveloped anatomical features, increasing their life expectancy and quality of life. Fatal complications can occur, including after the surgical operation, especially for more fragile patients [6]; for this reason, to reduce open heart surgery complications, alternative mini-invasive procedures have been introduced since the 1990s, such as stenting [7]. Some CHDs are currently treated through stenting as gold standard; on one hand, this approach guarantees an easier surgery that can be reiterated in time, if necessary, but not always demonstrating the capability of maintaining patency in time.

Nowadays, almost all stents used in CHD newborns or children have not been approved for such applications and are therefore used off-label [8], meaning that their biomechanical properties might not be targeted for the specific CHD, leading sometimes to a poor outcome of the intervention [9].

This review aims to present the current state of the art of those CHDs treatable through stenting, both as the gold standard and as an alternative to surgery. Starting from the analysis of independent clinical cases, recalling the devices used, and the treatment outcome, this work wants to summarize the reported experiences toward the identification of the best stent for the specific application. First, a brief introduction recalls the diversity of available stents on the market according to their material, manufacturing process, and specific design. Then different forms of CHD that are currently treated through stenting are discussed, presenting their anatomical anomalies and clarifying the need for such treatment. Although a comparative clinical report is not available on the topic, this review may help interpreting the current stent choices and improving future ones.

2. Stent Design

The innovative idea of positioning an intravascular stent percutaneously, as we intend it nowadays, below fluoroscopic remote control, was by Charles Dotter in the early 1960s [10]. In 1969, he led the former experiments on dogs with this technique using one spiral of stainless steel, with very close coils, mounted coaxially on a guide wire and positioned on site thanks to the push provided by a special flexible instrument, then called a catheter. In the 1980s, the first experiments on humans were performed using a self-expandable elastic spiral [11]; it consisted of two bands in stainless steel, 0.10–0.15 mm thick, forged at high temperature to form a double helix spiral, expandable to a maximum diameter of 35 mm. In animal experiments, the stent was completely endothelized within 6 weeks of implantation with a modest intimal reaction.

Nowadays, we can refer to hundreds of different stents organized according to different classifications, related somehow to their final application, which are discussed in the following paragraphs.

2.1. Materials and Deployment Strategy

An ideal stent should have good flexibility and deliverability, low thrombogenicity, strong radial force, good radio-opacity under fluoroscopy, and good biocompatibility to ensure low rates of neointimal hyperplasia and stent thrombosis during long-term follow-up [12]. The first types of devices were proposed for the treatment of coronary arteries and were called bare-metal stents, which were developed with conventional alloys that can be plastically deformed, like stainless steel, cobalt–chromium, or platinum–chromium [13–15]. Later they evolved into drug-eluting stents (DES), which are metal devices coated with an antiproliferative drug to limit the reoccurrence of stenosis. In the last years, bioresorbable vascular scaffolds have been proposed, made of degradable materials designed to support the vessel wall only temporarily and be reabsorbed when their function is no longer required; however, their long-term performance is still under evaluation [16]. Coronary stents belong to the family of the so-called balloon-expandable stents since they are positioned by the inflation of a balloon mounted on the catheter tip; the lesion is reached percutaneously and crossed by a guide wire, then the balloon catheter with the crimped stent is advanced over the wire across the lesion, and finally, the balloon allows the stent expansion to restore the artery lumen. After the balloon is deflated, the stent remains in its expanded shape, except for a slight recoil caused by the elastic portion of the deformation.

On the contrary, stents introduced in peripheral arteries (like femoral, popliteal, or carotid) have to withstand large cyclic loads due to leg/head movements [17–19], and for this reason are usually made by shape memory alloys, such as nickel–titanium (Ni-Ti), which can recover elastic strains up to 10% [20,21]. They are manufactured in the expanded configuration and then crimped and loaded on the tip of the catheter, maintained closed by a sheath; for this reason, Ni-Ti stents are named self-expandable stents since the retraction

of the sheath allows their spontaneous expansion to the predetermined diameter due to a material property exploited at body temperature, called superelasticity [22].

2.2. Fabrication Method

Stents can be made from sheets, wires, ribbons, or tubes, although the majority of balloon-expandable and self-expandable cardiovascular stents are made from metal wire or tubes. The choice of the fabrication method is strongly influenced by the form of the raw material employed, including machining tubular forms and machining and rolling sheets, as well as welding, braiding, knitting, and coiling wires to form the tubular structure of stents [23]. Probably the most common manufacturing process involves laser cutting from tubes, which also allows for great precision in creating complex patterns on very small tubes (from 0.5 mm diameters) [24] (Figure 1).



Figure 1. Different stent geometries according to the choice of the raw material form: (**a**) revolution of a sheet, (**b**) coil, (**c**) braided wires, and (**d**) slotted tubes, with detail on closed-cell (above) and open-cell (below) designs. Adapted with permission from [23]. (Elsevier, 2023).

Balloon-expandable and self-expandable stents are usually laser-cut from small tubes in a crimped or near-crimped form; following the cutting phase, deburring and surface polishing are mandatory. At this point, balloon-expandable stents are ready to be loaded on the catheter. On the contrary, self-expandable stents need to reach their final expanded configuration before they can be constrained through the sheath in the delivery system. This is achieved through a process of shape-setting, which involves using progressively larger mandrels and heat treatments to eliminate any plastic deformations caused by the enlargement. Additionally, heat treatment is a crucial step for such stents as it determines their mechanical properties [25].

Recently, additive manufacturing technologies have been studied as a potential way of stent manufacturing [26]. These stents can revolutionize the field of personalized medicine, with the realization of custom-made devices. In 2020, the FDA approved the use of 3D-printed silicone stents to help patients with serious breathing disorders by keeping their airways open. As for cardiovascular applications with metal stents, there are advances in the realization of functional stents that, however, should be improved to guarantee the same performances as the traditionally manufactured ones [27].

2.3. Geometry and Biomechanical Properties

According to the choice of the specific raw material form, stents can be fabricated in different geometrical configurations, such as a slotted tube, helical spiral, coil, woven, individual rings, and sequential rings [23]. Such a variety of designs seeks to balance

the major requirements for a stent, meaning radial strength, flexibility, and low elastic recoil [24]. While slotted-tube-type designs have excellent radial strength, they sometimes lack flexibility. The opposite is true of coil designs, which are currently used mostly in non-vascular applications, such as urethral and esophageal stenting.

Woven stents refer to many different designs that can be obtained from one or more strands of wire: they include braided stents, which are more common in self-expandable structures; and knitted stents. Braided stents can guarantee excellent surface coverage and kinking resistance, but are affected by a substantial longitudinal shortening during expansion [28]; indeed, their radial strength is strongly dependent on the fixation that can be achieved at the stent ends.

Single Z-shaped rings are typical for supporting endovascular prostheses such as aortic grafts; such rings are individually sutured or attached to the graft tissue, and can provide good radial support.

The majority of cardiovascular stents, both balloon-expandable and self-expandable, can be grouped in the category of sequential rings, meaning the structural elements (also known as struts) are connected by bridges, hinges, or nodes. These stent designs can be grouped into two main categories, namely open- or closed-cell designs. In open-cell stents, some or all of the internal inflection points of the struts are not connected by bridging elements, creating a periodic pattern, whereas in closed cells, all internal inflection points of the struts are connected by bridging elements into a more regular scheme [24]. Reasonably, the closed-cell stents increase the radial strength and better contain the atherosclerotic plaque [29] compared with the open-cell stents at the expense of flexibility, coverage ratio, and ability to access the side branches that are covered by the stent [23]. Even though closed-cell geometries were successful at the early stages of their introduction, open-cell structures are now preferred in stent manufacturing, allowing for greater versatility.

3. Congenital Heart Disease

The term CHD indicates a structural or functional abnormality of the heart or intrathoracic great vessels arising during pregnancy. CHD may occur in many forms affecting different parts of the heart, which can be generally classified into three main categories [30]: (i) cyanotic heart disease, including transposition of the great arteries, tetralogy of Fallot, tricuspid atresia, pulmonary atresia, double outlet right ventricle, and total anomalous pulmonary venous connection; (ii) left-sided obstructive lesions, among which are hypoplastic left heart syndrome (HLHS), mitral and aortic stenosis, aortic coarctation (CoA), and interrupted aortic arch; (iii) septation defects, which may involve the atria, the ventricles, or the central part of the heart. Other functionless abnormalities of the great veins or the branches of the aortic arch as well as congenital arrhythmias are generally not included in this classification. CHD represents the most common congenital malformation diagnosed in newborn babies, with an incidence of about 6 of every 1000 live births for severe and moderate forms of CHD, which increases up to 75 of every 1000 live births including also minor forms [31]. Although morbidity may vary according to the severity of the specific defect form, CHD is retained as the leading cause of mortality related to congenital defects overall [32]. However, the improvements in diagnostic and therapeutic procedures in the last decades have strongly increased life expectancy, leading to a consistent demographic shift, with an expected increase in the population of adults with CHD [33]. Since critical CHD forms are not compatible with life, medical intervention is frequently required soon after birth [34], relying on the combination of open-heart surgery in multiple steps with percutaneous transcatheter interventions such as stenting.

Given the inherent complexity of the different CHD forms and the associated medical interventions, a clear comprehension of the evolution and distribution of blood flow in the various districts during intrauterine life is fundamental for understanding how congenital cardiac malformations affect both fetal growth and adaptation at birth. Therefore, in the following section, the characteristic features of fetal circulation are analyzed in comparison

to adult circulation, providing a clear picture of how specific CHD forms can be managed during fetal life.

3.1. Characteristic Features of Fetal Circulation

The fetal circulation is markedly different from the adult circulation. Indeed, the cardiovascular system undergoes several changes during the whole fetal life and the first days after birth leading to the final adult configuration and structure. Despite these differences, the primary function of the cardiovascular system is always the same: providing oxygen and nutrients from the external environment to the tissues and removing carbon dioxide and waste products. In physiological conditions, once development is completed, the heart is composed of four main chambers, namely the right atrium and the right ventricle and the left atrium and the left ventricle, which perfuse a series system constituted by the pulmonary and systemic circulation. The oxygen-poor blood coming from body tissues and organs returns to the right atrium through the superior and inferior vena cava. The blood enters the right ventricle and then, through the pulmonary artery, it is pumped into the lungs where oxygenation occurs. The oxygenated blood returns to the left atrium through the pulmonary veins and then reaches the left ventricle, where it is pumped towards the various body districts through the aorta and its branches. Adult circulation can thus be schematized as a closed circuit, with four components in series (Figure 2a) in which the blood flow pumped by the right ventricle into the pulmonary circulation should equal the blood flow pumped by the left ventricle into the systemic circulation, defining the cardiac output.

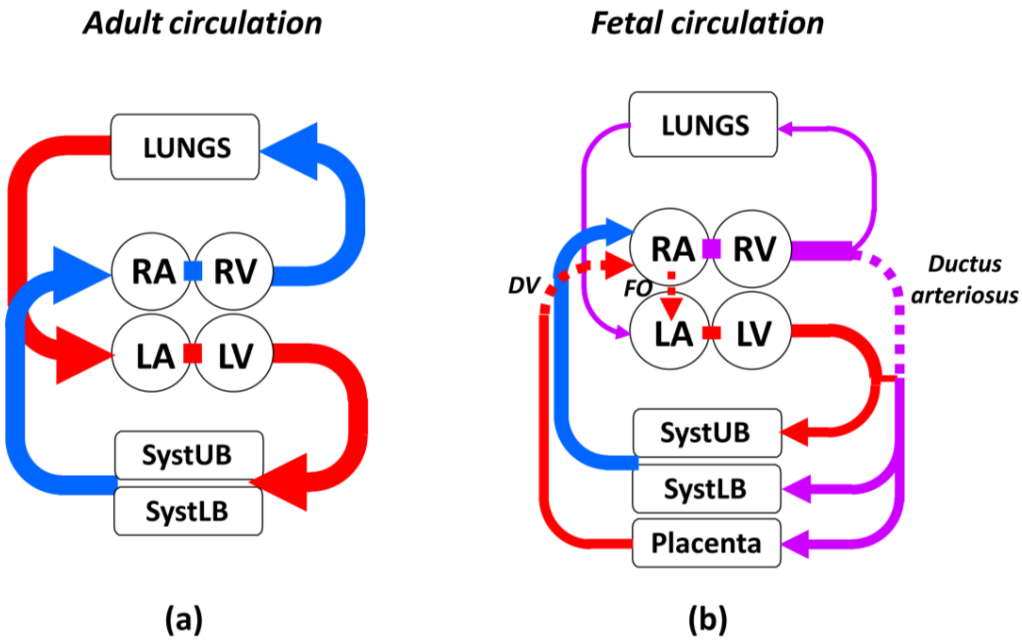

Figure 2. Comparison between (**a**) adult circulation, schematized as a series system, and (**b**) fetal circulation, constituting an intricate parallel circuit. Blue arrows define the path of poorly oxygenated blood, while red arrows stand for oxygenated blood. The magenta color indicates intermediate oxygenation. The dashed arrows in the fetal system indicate the additional pathways the fetal shunts allow. DV = ductus venosus, FO = foramen ovale, RA = right atrium, LA = left atrium, RV = right ventricle, LV = left ventricle, SystUB = systemic upper body, SystLB = systemic lower body.

The primary difference between adult and fetal circulation is that in the fetus gas exchange takes place in the placenta (the organ that connects the maternal and fetal circulatory systems) rather than in the lungs. The placenta substitutes the respiratory, the gastrointestinal, and renal systems during the whole fetal life, assuring the exchange of nutrients and waste products and allowing for blood oxygenation. The deoxygenated

blood comes to the placenta through the umbilical arteries, which originate from the iliac arteries, just beyond the aortic bifurcation. Oxygen-rich blood is returned to the fetus through the umbilical vein, and approximately 50–60% of this blood flow directly reaches the inferior vena cava through the ductus venosus, a fetal shunt that allows part of the placental blood flow to bypass the liver [35]. Oxygen-rich blood in the inferior vena cava enters the right atrium and preferentially streams into the left atrium through the foramen ovale (a hole in the atrial septum present only during gestation) without mixing with the oxygen-poor blood coming from the lower and upper limbs which instead enters the right ventricle. Thanks to the foramen ovale, the most oxygenated blood directly reaches the left heart, is pumped into the ascending aorta, and then is delivered to the coronary circulation and the brain. The remaining part of desaturated blood in the right atrium is delivered to the right ventricle and is pumped into the pulmonary artery. As the lungs are not working in fetal life, only a small portion of blood enters the pulmonary circulation due to the associated high pulmonary vascular resistance [35]. Indeed, most of the pulmonary artery blood flow (90%) bypasses the lungs flowing into the aorta through the ductus arteriosus (also indicated as Botallo's duct). This fetal shunt, a vessel approximately 1.5 cm long with a diameter of 0.5–0.6 cm (which in utero is kept open by the high level of prostaglandins coming from the placenta) ends in the descending aorta after the aortic arch and allows the right ventricle to feed the lower systemic circulation during gestation. In fact, the poorly oxygenated blood is sent to the lower part of the body requiring less oxygen supply, and to the placenta for oxygenation. According to the described vascular organization, it is evident that the resultant circulation is highly optimized to guarantee proper oxygenation of the fetal vital organs, i.e., myocardium and the brain. Due to the presence of intracardiac (foramen ovale) and extracardiac shunts (ductus arteriosus and ductus venosus), the fetal circulation can be schematized as an intricate parallel circuit (Figure 2b) in which systemic circulation is fed both from the right and the left ventricle. Thus, the cardiac output is defined as a combined ventricular output [35] given by the sum of the blood flows from the two ventricles.

At birth, a series of cardiopulmonary adaptions take place to accommodate extra-uterine life. The umbilical cord is clamped, arresting the delivery of oxygen, nutrients, and prostaglandins through the placental circulation and increasing systemic vascular resistance. The blood flow in the ductus venosus drastically reduces until a complete passive closure of the vessel 3–10 days after birth [35]. At the first breath, the lungs expand, causing a strong decrease in pulmonary vascular resistance and an increase in pulmonary blood flow. These events determine a pressure shift, with the pressure in the left ventricle exceeding that in the right ventricle, causing the foramen ovale to close immediately. Complete anatomical closure of the shunt occurs later, within 6–12 months from birth. Additionally, the increase in blood oxygen content, which causes constriction of the smooth muscle in the ductus arteriosus, together with the reduction in prostaglandins level, determines the functional closure of the ductus arteriosus within 24 h from birth. Anatomical closure occurs later via diffuse fibrous tissue proliferation within 2–3 weeks [36].

Once a clear picture of how the physiological fetal cardiovascular system is obtained, it is easy to understand how blood circulation is strongly shunt-dependent during gestation. The three described shunts assure a flexible and adaptive circulation, which makes it possible for the fetus to survive gestation even in the presence of severe congenital malformations typical of CHD (e.g., the absence of underdevelopment of one of the two ventricles), thanks to the establishment of parallel pathways.

3.2. Defects Amenable to Stenting

Among the various CHD forms, this review focuses specifically on those congenital defects which are amenable to treatment through transcatheter stent implantation (Figure 3). According to the kind of lesion, stenting can be adopted both as a stage of a complex multiple-step intervention or as a first-choice treatment. Specifically, the use of stents to ensure patency of the ductus arteriosus counteracting its natural closure at birth is

discussed as a route to establish a parallel pathway in the presence of underdeveloped structures, both in the case of left-sided hypoplasia (i.e., HLHS) or right-sided hypoplasia (i.e., pulmonary atresia). Additionally, the treatment of stenotic lesions affecting the great vessels is investigated, considering both CoA and pulmonary artery stenosis. However, only congenital stenosis present at birth, which is developed during fetal life, is considered, disregarding stenosis forms acquired after surgical procedures or related to atherosclerotic disease.

In the following, these four CHD forms are addressed in this review in depth, describing both the adjustment of blood circulation in utero for defect management and the dramatic effects of the transition from fetal to neonatal circulation.

3.2.1. Hypoplastic Left Heart Syndrome

Hypoplastic left heart syndrome is the most severe form of CHD, consisting of a critical underdevelopment of the left-sided cardiac structures, including the left ventricle, the mitral valve, the aortic valve, and the ascending portion of the aorta [37] (Figure 3a). This pathology is the most common defect among those characterized by single-ventricle physiology [38], comprising 1.4–3.8% of congenital heart defect cases [39], meaning 20,000 diseased newborns worldwide in 2022 [40]. The origin of this condition can be associated with obstruction of the outflow or inflow in the left ventricle, among which a defective aortic valve is the most common [41]. The consequence is a reduced flow in the left ventricle leading to left-sided hypoplasia. Moreover, a pressure unbalance at the foramen ovale occurs, causing blood flow to revert its direction from the left to the right side [41,42].

The physiological blood flow during gestation is affected by the presence of HLHS since the left ventricle does not have sufficient pumping capability to supply oxygen-rich blood to the body. As a consequence, the right heart is exploited as a single pumping chamber, feeding both the pulmonary and the whole systemic circulation (both upper and lower body) in parallel. In this condition, the total cardiac output flows through the right atrium; just a small amount (10%) of blood flow enters pulmonary circulation, while the greater part feeds the systemic circulation through an enlarged ductus arteriosus, which has typically elongated morphology [41]. The blood flow in the aortic arch is reversed to feed the brain and the coronaries, not sufficiently perfused by the left ventricle outflow.

Whereas during pregnancy, systemic circulation is not impaired significantly, the spontaneous closure of the ductus arteriosus leads to a rapid onset of hypoxia and tissue ischemia metabolic acidosis [41]. Neonatal death would typically occur within 7–10 days after birth if the pathology is left untreated [37]. However, medical advancements in the last four decades have allowed for the establishment of a multi-stage palliative surgery, which has highly improved the outlook for these patients.

There are two different approaches for the treatment of HLHS: a purely open-heart surgical repair and a *Hybrid* one, combining transcatheter stenting and surgical features.

In the first case, within a few days of life, the newborns undergo the Norwood operation, in which the right ventricle is rerouted to the systemic circulation by anastomosing the main pulmonary artery to the ascending aorta (neoaorta) to overcome the dependence of the systemic circulation from the ductus arteriosus. Pulmonary blood flow is derived from either a systemic–pulmonary arterial shunt or a right ventricle–pulmonary arterial shunt, and pulmonary venous return is guaranteed through atrial septectomy. However, the whole body is perfused with mixed blood, since only one pumping chamber is present, with an increased workload of the right ventricle. In order to restore a circulation where pulmonary and systemic circulations are in series, two subsequent surgical stages (Glenn procedure and Fontan operation at 4–6 and 18–24 months of age, respectively) are performed, creating a connection between the two systemic vena cavae and the pulmonary arteries.

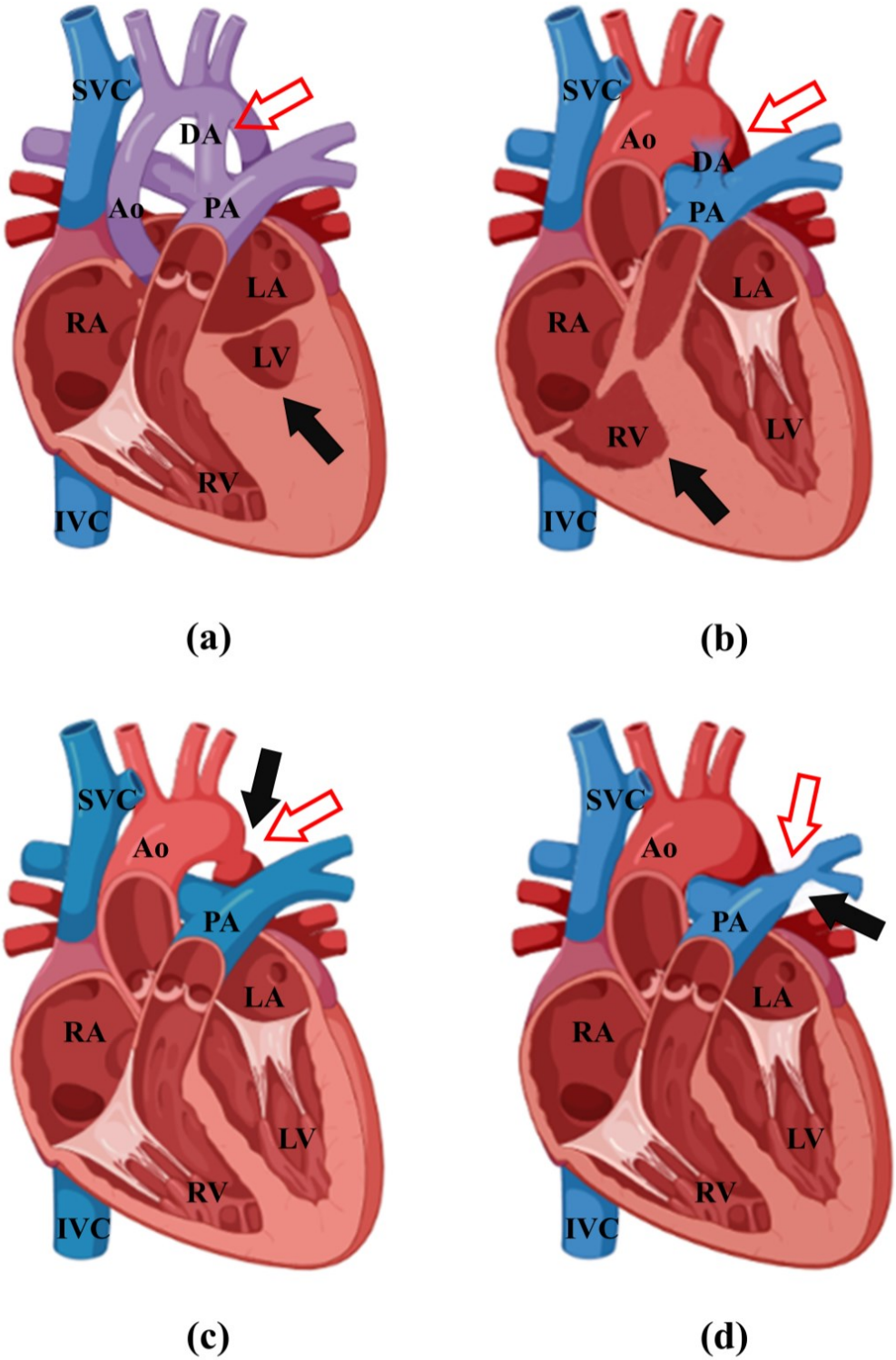

Figure 3. Characteristic anatomy of the heart in the presence of CHDs treatable through stenting, as (**a**) hypoplastic left heart syndrome, (**b**) pulmonary atresia, (**c**) aortic coarctation, and (**d**) pulmonary artery stenosis. Black solid arrows highlight the main aspects that differ from the physiological state, while red arrows show the location of the stent implantation. RA = right atrium, RV = right ventricle, LA = left atrium, LV = left ventricle, SVC = superior vena cava, IVC = inferior vena cava, Ao = aorta, PA = pulmonary artery, DA = ductus arteriosus. Created with BioRender.com.

Hybrid therapy has been able to replace the Stage I Norwood procedure since 1993 [43], especially in those patients considered at high risk for cardiopulmonary bypass or cardiac/total circulatory arrest [44]. This kind of approach integrates interventional cardiac catheterization with off-cardiopulmonary bypass, achieving the same goals of the standard Norwood stage in a less invasive manner. The delaying of cardiopulmonary bypass to the next surgical stages allows a more clinically stable situation to be reached and reduces the risk of abnormal neurocognitive development [39]. In the Hybrid stage, after a few days, a stent is placed in the ductus arteriosus through a mini-invasive transcatheter procedure to guarantee good systemic perfusion. Moreover, surgical bilateral banding of the pulmonary arteries is performed to reduce blood flow into the lungs and obtain a balanced systemic-to-pulmonary flow ratio. Pulmonary venous return is accomplished with balloon atrial septostomy, enlarging the opening between the two atria. The second stage is similar to the standard Glenn technique, plus the reconstruction of the neoaorta, adding the release of pulmonary bands and the removal of the ductus stent, while the third stage is exactly like the Fontan stage.

3.2.2. Pulmonary Atresia

Pulmonary atresia is a defect of the pulmonary valve regulating the blood flow from the right ventricle to the pulmonary artery, which lacks continuity with the ventricular chamber or does not form at all during development. Since blood flow toward the lungs is strongly impaired, this malformation is commonly classified as a cyanotic disease [45–47]. Two variants of the pathology can be recognized according to the presence of a ventricular septal defect separating the two ventricular chambers. In particular, the most critical condition is considered in this review, characterized by an intact ventricular septum, which leads to a very small amount of blood flowing to the right ventricle. As a direct consequence, the right side of the heart develops hypoplasia involving both the right ventricle and the pulmonary artery (Figure 3b), which assumes a severe degree in 35% of the patients [48]. This disease is retained as a quite rare form of CHD. It occurs in approximately 3% of all CHD malformations [45].

During in utero life, the presence of the foramen ovale allows the blood flow from the inferior and superior vena cava to move from the right atrium to the left atrium under a pressure gradient. The blood is pumped into the aorta from the left ventricle and it perfuses the systemic circulation. Just a small amount of blood (10%) flows through a narrowed ductus arteriosus in a reversed direction with respect to physiological conditions, feeding the pulmonary circulation. With duct-dependent pulmonary blood flow, the ductus arteriosus is typically long, curved, and tortuous [49]. After birth, medical intervention is required within the first weeks of life in most cases due to the spontaneous closure of the ductus arteriosus, being blood circulation in the lungs duct-dependent [45]. Given the high morphologic variability of the pathology, the most appropriate surgical and/or transcatheter treatment is planned in each case according to the specific morphologic features and classification. Various management strategies for pulmonary atresia with intact ventricular septum have been established by different centers [45,47,48]. Medical treatment is always preceded by transthoracic echocardiography to assess the size of the pulmonary valve annulus, the size and functionality of the tricuspid valve and the right ventricle, and the morphology of the ductus arteriosus. In any case, the goal of the treatment is to provide adequate pulmonary blood flow, favoring at the same time the growth of the right ventricle. In the less critical patients having a normal or mildly hypoplastic right ventricle, a biventricular approach is preferred, aiming to establish a separate biventricular circulation by creating a patent right ventricular outflow tract (RVOT). This allows for the decompressing of the right ventricle and guarantees an anterograde pulmonary blood flow. This procedure can be performed either percutaneously, through transcatheter pulmonary valve perforation followed by balloon dilation, or surgically, performing pulmonary valvotomy and RVOT reconstruction, and it may result in right ventricle growth [50,51]. Additionally, a hybrid technique that combines surgical access

with a transcatheter intervention has been proposed, having the advantage of avoiding cardiopulmonary bypass and sternotomy in the neonatal period but reducing at the same time the procedural complication and failure rates of the purely percutaneous route [52]. In the most critical patients characterized by severe right ventricle hypoplasia, a univentricular approach is followed, requiring the creation of a systemic-to-pulmonary communication as initial palliation in the neonatal period. Stenting of the ductus arteriosus is generally preferred as a less invasive alternative to the conventional placement of a shunt between the subclavian and the pulmonary artery, allowing for a reduction in post-procedure morbidity and hospital stay [47]. At the same stage, balloon atrial septostomy is performed to guarantee right-to-left atrium communication. Then, the patients undergo a bidirectional Glenn procedure followed by a Fontan stage to achieve total cavo-pulmonary connection, as in the case of HLHS.

3.2.3. Aortic Coarctation

Aortic coarctation is a birth defect consisting of a narrowing of the aorta, which does not form correctly during gestation. The narrowing typically manifests just beyond the left subclavian artery [53], thus, before the aortic isthmus and the ductus arteriosus insertion (Figure 3c), but it may occur in various anatomical locations of the aortic arch or in the thoracic or abdominal aorta [54]. Moreover, CoA may occur in isolation, or it can be associated with other complex CHD lesions such as HLHS. This pathology represents a quite common form of congenital lesion if compared to other malformations, comprising approximately 7% of all CHD forms [55,56], meaning an incidence of 50,000 over the total live births worldwide in 2022 [57,58]. As for the other congenital malformations, the parallel circulation allowed by the fetal shunts permits the fetus to survive gestation. Indeed, the ductus arteriosus provides a route with less resistance for the blood flow in the right ventricle to bypass the aorta stenosis and perfuse the downstream districts, while the left ventricle feeds the upper portions of the body. In extra-utero life, when adult circulation is established, the work of the left ventricle has to increase to generate sufficient pressure to force the blood into the narrowed aorta. In the most severe cases with marked stenosis or interrupted aortic arch, the lower body districts are poorly perfused. The treatment of CoA may vary according to anatomical features and age of presentation. In this review, attention is placed on native CoA forms requiring treatment in the neonatal period. Typically, surgical treatment is retained as the first-choice option in younger patients up to 18 months, while transcatheter treatment through balloon angioplasty or stent implantation in the aortic isthmus is preferred for older children and adolescents [55,59]. Indeed, the main limitation of stenting in infants nowadays is related to the dimension of sheath needed for implantation of stents that can be redilated to adult size following somatic growth [54].

3.2.4. Pulmonary Artery Stenosis

Pulmonary artery stenosis is a narrowing of the pulmonary artery connecting the right ventricle with the lungs (Figure 3d). Depending on the location of the stenosis, the pathology is classified into four different types [60]: type I consists of a single stenosis site affecting the main, the left, or the right pulmonary artery; in type II morphology, the pulmonary artery bifurcation is affected; type III lesion is a stenosis of multiple segmental pulmonary arteries with normal central arteries; in the type IV variant, both peripheral pulmonary arteries and the central ones are stenotic. This pathology accounts for 2–3% of all CHD malformations [54,60,61]. It may generally have a congenital origin or it can be acquired after surgical intervention; however, only the former case is considered in this review. Moreover, it may develop as an isolated defect or in conjunction with other CHD forms. While during in utero life this condition can be tolerated thanks to the parallel circulations, as in the case of pulmonary atresia, at birth, intervention is required in case of right ventricular hypertension associated with the increased work of the right heart, strong asymmetry of the pulmonary blood flow, right ventricle dysfunction, and pulmonary artery hypertension [62]. The goal is to restore a homogeneous pulmonary blood flow distribution,

avoiding hypoplasia of the affected segments due to low perfusion [54,61]. Transcatheter therapies constitute the first-line choice, while the surgical approach is restricted to a limited number of cases such as well-localized lesions of the main pulmonary artery or the pulmonary bifurcation [61]. Transcatheter treatments are basically the same adopted for CoA, namely balloon angioplasty and pulmonary artery stenting. Stenting is typically preferred in cases of proximal or distal branch pulmonary artery stenosis, stenosis due to kinking, tension, or external compression, and in cases of compliant obstructions [61].

4. Stents in the Treatment of Congenital Heart Disease

The transcatheter stenting procedure has been introduced as a less invasive alternative to open-heart surgery in CHD treatment since the 1990s. The first attempts of ductal stenting in humans adopted early-generation rigid stents, with relatively bulky, stiff wires, balloons, and sheats, causing negative outcomes including cyanosis or shock, bleeding, vessel rupture, duct spasm, tissue prolapse, or thrombosis [7,43,63]. Within this context, it is relevant to mention the experience of Gibbs and coworkers, who were the first to investigate the effectiveness of ductal stenting in the palliation of HLHS [43]. They implanted Palmaz–Schatz stainless steel biliary stents in four newborn patients using femoral access, performing balloon expansion in quite straight ducts. However, wrong stent positioning related to the shortening during dilation resulted in incomplete ductal covering and distal ductal stenosis. The same authors were also the first to assess the technical feasibility of ductal stenting in pulmonary atresia [7]. The same stent design was adopted; however, the implantation required multiple interventions to achieve ductal patency, due to the more complex anatomy of the ductus arteriosus. Some cases were reported in which implantation failed due to duct tortuosity [49]. In the same years, the first attempts of stent implantation for treatment of aortic and pulmonary artery stenosis were reported due to the unsatisfactory results of surgery and balloon angioplasty, with acute complications, including vessel wall disruption, stent migration, aneurysm formation, and stent obstruction [64–66]. Since then, thanks to several innovations in device design and fabrication methods as well as in operative techniques and equipment, the stenting procedure has evolved progressively, establishing as a gold standard in many centers [67]. In the following, the pathologies requiring a similar stenting procedure with comparable related issues are grouped together, distinguishing between stenting of the ductus arteriosus and stenting of the great vessels. Common choices for device selection reported in the literature are reviewed, highlighting existing trends.

4.1. Ductal Stenting: HLHS and Pulmonary Atresia

Ductal stenting may be performed as a palliative procedure to ensure ductal patency in newborns with single ventricle physiology, with either duct-dependant systemic circulation (HLHS) or duct-dependant pulmonary circulation (pulmonary atresia). Table 1 provides a clear picture of the wide variety of devices that have been used over the years and are still currently adopted, following the stent classification proposed in paragraph 2.

Table 1. State of the art of stents adopted in the treatment of HLHS and pulmonary atresia. A distinction is made between those stents developed for other applications, thus used off-label in CHD, and those specifically developed for cardiac congenital malformations. Devices are classified among balloon-expandable and self-expandable stents, having a closed-cell (C) or open-cell (O) geometry.

	Off-Label Use		**Ad Hoc for CHD**
	Balloon-Expandable	**Self-Expandable**	
HLHS	Palmaz-Schatz (C) [43,49,63] Palmaz-Genesis (C) [68] Herculink (O) [68,69] Nir Royal (C) [69] Mega-Link (O) [69] Libertè (O) [70] Jo stent (C) [68,71,72] Omnilink (O) [68,72] Saxx stent (C) [68,71,72] Cook Formula 414 (O) [73]	Precise (O) [74] Protégé (O) [70,74,75]	Sinus-Repo-DS (C) [68]  Sinus-SuperFlex-DS (O) [73,76–78] 
Pulmonary atresia	Palmaz–Schatz (C) [7,46,49,79] Multi-Link Vision (O) [80–83] Promus Premier * (O) [80] Driver (O) [83–86] Tsunami (O) [84] Libertè (O) [84,85] Ephesos (O) [85] Jostent (C) [87] Express (O) [87] Cordis Bx Velocity * (O) [87] AVE S670 (O) [87] VeriFLEX (O) [82,83] Integrity (O) [82,83] Omega (O) [82] Skylor (C) [82] Amazonia * (O) [82]	NA	NA

* Drug-eluting stent (DES); others, where no specification is provided, are bare metal stents (BMS).

By examining the existing literature, it emerges how the vast majority of devices for ductal stenting are used on an off-label basis. Many endovascular stents developed for adult patients for different anatomical locations are exploited, among which are coronary, iliac, biliary, renal, carotid, and peripheral stents. To understand this scenario, one should consider that medical devices for CHD are classified as orphan devices, intended for the treatment of rare pathologies interesting less than 1 in 2000 people [88]. In the market of CHD devices, the high cost associated with the development of a new device and regulation is unbalanced with respect to profitability to the industry given the restricted number of cases [89]. Moreover, the variety of congenital problems and anatomical configurations requires high flexibility and unique treatment strategies, with very few devices approved for specific indications [90].

In spite of the fact that the objective of using stenting in HLHS and pulmonary atresia is similar, the distinct ductal morphology calls for different devices and intervention approaches.

In HLHS, the ductus is typically straight, without narrowing, with a large diameter of around 3 mm to 6 mm at the pulmonary end and 5 mm to 8 mm at the aortic end. An accurate preliminary delineation of the ductal morphology by angiography is mandatory to select the proper device. The stenting procedure is quite straightforward and stents of a diameter between 6 mm and 10 mm are generally needed [69]. Since, from a histological point of view, the ductus has a significant muscular component that applies an active closing action at birth [91], a device with sufficient radial strength is needed to avoid collapse. Moreover, since especially the distal part of the ductus is strongly prone to constrict if a

short tract is left unstented, a stent slightly longer than the ductus should be implanted to ensure complete coverage. In the literature, there are reported cases on such use of open-cell stents to alter the local hemodynamics less, either balloon or self-expandable [70,77]. In many cases, multiple overlapping stents need to be adopted according to the available sizes [49,92]. Nowadays, self-expandable stents with a cell design suitable to guarantee a high radial force are the preferred choice [67], chosen among carotid and peripheral stents. Balloon-expandable stents, selected among coronary, renal, and biliary devices, are only indicated in case of ductal stenosis to reduce stent migration risk [68]. The great advantage of self-expandable stents relies on their higher flexibility and conformability to duct shape with respect to balloon-expandable stents and the possibility of implantation through smaller sheaths [70,73,77,93]. Among the most common complications, stent migration, need for re-stenting, aortic isthmus jialing, and stent obstruction are reported [70,77,92]. According to stent design, an open-cell configuration is a quite common choice thanks to the reduced foreshortening and the high conformability [67]. Moreover, since the ductus is typically short and straight, large cross-sections, thick struts, and small cell areas are indicated, allowing for good scaffolding with minimum tissue prolapse [94]. It is relevant to mention that there are on the market two stents specifically designed and certified for hybrid palliation of HLHS: the nitinol Sinus-SuperFlex-DS and the Sinus-Repo-DS (Optimed, Germany). The former is characterized by an open-cell design to provide an effective combination between conformability and radial force, with diameters ranging from 4 mm to 9 mm; the latter has a closed-cell design and is indicated for combined treatment of aortic coarctation, with size of 5 mm and 6 mm. However, controversial outcomes have been reported: while some studies reveal positive follow-up with sufficient radial strength, good hemodynamics, and reduced wall trauma [77,78], others report early collapse due to insufficient radial force and severe restenosis [73,76].

In pulmonary atresia, due to the reduced blood flow, the ductus arteriosus typically assumes a narrow and tortuous morphology [7,49,84]. Therefore, stenting might be changeling or even unsuitable [49,85,87], and it is associated with a high unplanned re-intervention rate [95]. Also, in this case, accurate delineation of the ductal morphology by angiography is needed. A stent slightly longer than the ductus should be implanted for complete coverage [94], relying in many cases on overlapping stents [49,84] with sufficient radial force to counteract ductal active closure. Probably for this reason, there are no reported uses of self-expandable stents. The small size of the ductus arteriosus in this condition leads to the use of coronary balloon-expandable stents with diameters ranging from 3 mm to 5 mm in most cases. These devices provide sufficient radial strength to ensure ductal patency, allowing pulmonary arteries growth, good systemic oxygenation, and spontaneous improvement of pulmonary circulation [84,86]. Moreover, they allow for the possibility of further dilation by balloon expansion to counteract duct constriction [7]. However, they poorly conform to the curvature of the ductus, and their implantation is associated with a transient blockage of cardiac output that unbalances hemodynamics [77]. According to stent geometry, open-cell designs are widely adopted also in this case, preferring larger cell areas to improve flexibility and conformability given the strong duct tortuosity. At the moment, no ad hoc devices specifically developed for pulmonary atresia have been found in the literature.

Despite DESs being shown to reduce early coronary artery restenosis when compared to uncoated stents, limiting thrombosis and neointimal proliferation, their use is rarely reported for ductal stenting in HLHS or pulmonary atresia. Although they might seem an attractive option, the mechanism of restenosis in the ductus arteriosus is different from that of a coronary artery with an atherosclerotic plaque [87]. In this case, a mechanical opening counteracting muscular action is needed and antiproliferative drugs may not necessarily prolong duct patency. Except for some initial old studies [96,97], there is still a lack of experience in the use of DES in pediatric applications, with many concerns about the systemic side effects of drugs in infants [98].

4.2. Great Vessel Stenting: CoA and Pulmonary Artery Stenosis

In Table 2, the stents adopted over the years for the treatment of both CoA and pulmonary artery stenosis are collected.

Table 2. Stents adopted in the treatment of CoA and pulmonary artery stenosis. A distinction is made between off-label and specifically developed designs. Devices are classified among balloon-expandable and self-expandable stents, with closed-cell (C) or open-cell (O) geometry.

	Off-Label Use		**Ad Hoc for CHD**
	Balloon-Expandable	**Self-Expandable**	
CoA	Cook Formula 418 and 535 (O) [99] Palmaz Genesis (C) [100–102] Ev3 Maxi (O) [102] Palmaz Genesis XD (C) [55,65] IntraStent Mega LD (O) [55] IntraStent Max LD (O) [55] Palmaz XL (C) [55] Valeo (O) [55]	Sinus-XL (C) [103]	Growth Stent (O) [104]  Cheatam Platinum (C) [100,101] 
Pulmonary artery stenosis	iCAST Atrium * (C) [105] Palmaz Blue (C) [105] Palmaz Genesis (C) [105] Cook Formula 418 (O) [105] VeriFLEX (O) [105] IntraStent Max (O) [105] IntraStent Mega (O) [105] Edwards Valeo Lifestent (O) [106]	Protégé (O) [105] Zilver Cook (O) [105] Dynalink Biliary (O) [105]	Growth Stent (O) [104] 

* Drug-eluting stent (DES); others, where no specification is provided, are bare metal stents (BMS).

Even in this case, it is clearly possible to notice how the majority of devices are used off-label, due to the limited investment from industry. The proper device is generally selected among coronary, peripheral, carotid, biliary, and renal stents according to the vessel caliber, which may be extremely different case by case, requiring stents in a variable range of size from a few millimeters up to a few centimeters [105].

The goal of the stenting procedure in this case is more traditional, aiming to restore blood flow in a stenotic site in place of balloon angioplasty, given improved acute and long-term outcomes [55,105]. However, somatic growth accommodation represents the most critical aspect regarding the stenting procedure in great vessels, requiring subsequent redilation and eventually reinterventions according to the age at presentation. Specifically, according to the American Heart Association, stent placement for CoA is indicated in patients in whom stent expansion to adult size is possible, with a coarctation gradient above 20 mmHg or significant hypertension [62]. Similarly, stenting is indicated for proximal or distal pulmonary artery stenosis when accommodation of further stent dilation to adult size is possible [62]. However, in specific cases, it might be also reasonable to implant small stents that cannot achieve adult size in small children as part of a palliative approach [105].

Baloon-expandable stents represent nowadays the gold standard in the treatment of great vessel stenosis given their superior radial strength, well-predictable placement, and the possibility of growth accommodation through further balloon expansion [105]. However, inherent complications are not absent, including vessel rupture, stent migration, re-stenosis, and aneurysm formation, which generally occur in long-term follow-up [67,105,107]. Conversely, self-expandable stent application in this context is still at its outset, with very scarce studies investigating their performance. While some authors hypothesize that removing the need for ballooning might reduce the risk of stent fracture, vessel dissection, and aneurysm formation [103], some others sustain that the unequal rate of expansion in different por-

tions of the vessel during growth might lead to an eccentric radial force, causing late stent migration [108]. Moreover, these devices cannot be dilated beyond their nominal diameter, and implantation of an oversized self-expandable stent is not advised as it might stimulate neointimal growth and vessel erosion [108]. For what concerns device geometry, open-cell design is generally preferred as it is associated with a larger final size and allows for the reopening of side branches [54,105].

The limited number of reports about DES implantation for aortic and pulmonary artery stenosis is explained also in this case by the lack of experience in their use in infants. Indeed, longer follow-up is needed to assess their performance and utility in congenital anatomical stenosis. There are recent studies [109,110] investigating the use of covered stents to limit wall injuries; however, they are not able to always quantify the usefulness in preventing reinterventions compared to non-covered ones.

Trying to overcome the issue related to somatic growth accommodation, self-disrupting stents were investigated at the beginning of the century. A well-known example is the Growth stent (QualiMed, Winsen, Germany), initially developed for aortic coarctation [104]. It is composed of two separate halves of laser-cut and electropolished stainless steel, which are connected with bioabsorbable sutures to create a circular structure. Complete absorption of the sutures occurs after 6 months; then, the two separate halves would remain in place without limiting somatic growth and allowing for easier implantation of a larger conventional stent with potential expansion to adult size. However, the high reintervention rate and early redilation need reported in the first trials, without fulfilling the adaptive growth requirement [104], led to the failure of this design. To address growth issue, the most common strategy nowadays is the use of newer stent designs combining a low delivery profile with high redilation potentials, such as the Palmaz Genesis XD, Palmaz XL, Intrastent Mega, and Intrastent Max LD, which can be easily dilated up to adult vessel diameters (20–25 mm). Within this category, it is relevant to mention the so-called Cheatham Platinum (CP) stent (NuMED, Hopkinton, New York, USA), which is the first device to be approved for CoA [111]. It is constituted of platinum and iridium wires arranged in a zig pattern, with an expansion range of up to 30 mm, existing also in a covered version (DES). Its high dilation potential highly reduces the need for additional stent implantation, reducing the rate of restenosis with respect to other devices [100]. It is interesting to cite also the Minima stent (Renata Medical, Newport Beach, CA, USA) [112], a cobalt–chromium balloon-expandable device that is currently under clinical trials for application in congenital vascular stenosis. Its unique design allows for an initial size of less than 4 mm for implantation at birth, with the possibility to expand to over 22 mm, maintaining structural integrity and radial strength. Another recent advancement is given by the BeGrow stent (Bentley InnoMed, Hechingen, Germany), developed for pulmonary artery stenosis, which is currently completing a clinical trial [113]. It consists of a cobalt–chromium balloon-expandable stent with a unique design to allow for dilation up to 11.5 mm; the presence of predetermined breaking points allows for a controlled and reliable rupture when this size is exceeded for growth accommodation and/or subsequent implantation of larger stents.

5. Vision and Future Perspectives

Despite great advancements in the field of transcatheter stenting procedures for CHD treatment being made since their introduction, some issues are still to be solved, and open questions guide ongoing research studies. Even if the definition of a unique ideal stent for each specific malformation seems to be quite hard given the high morphological variability, it is possible to outline the optimal characteristics that an ad hoc designed device should pursue.

For what concerns ductal stenting, an optimal device should be characterized by:

- High conformability to well adapt to duct geometry and shape;
- High radial force to counteract duct constriction keeping duct patency;
- Low profile for implantation at birth through small delivery sheaths;

- Good longitudinal flexibility to allow for delivery and maneuverability in/through torturous vessels during implantation;
- Minimal foreshortening for precise positioning in the duct, avoiding portions of the conduit being left uncovered after stent expansion;
- Minimal recoil to maintain duct patency after expansion.

Since implantation is only temporary and the device will be removed 4–6 months after birth during the next surgery step, accommodation of somatic growth is not generally perceived as an issue. For the same reason, fatigue testing should be adapted to this reduced lifetime. Following the most recent innovations in the market of devices for hybrid palliation of HLHS, a self-expandable stent with an optimized design to guarantee sufficient radial force and flexibility for delivery would be the best option. An increased oversize of the device with respect to the vessel might improve the radial expansion force, helping in counteracting ductal constriction. Another possibility might be the design of variable strut thickness along the device length to increase the radial strength in those areas of the ductus having remarkable power to constrict. Specifically for HLHS treatment, ad hoc geometries with lateral protrusions in the pulmonary conduits might be investigated to achieve both pulmonary artery flow reduction (as with the surgical banding) and stenting with a single device, in a unique procedure. Conversely, for what concerns ductal stenting in pulmonary atresia, the complex geometry of the tortuous ductus paves the way toward less traditional manufacturing technologies. As an emerging example, additive manufacturing techniques are quite attractive for realizing personalized stents to target specific lesions in patients with complex cardiac anatomy [26].

Moving to great vessel stenting, the characteristic features of an optimal device should include:

- Adaptable dimensions to accommodate vessel somatic growth;
- High radial strength to resist external radial forces applied by the stenotic vessel wall;
- Low profile for implantation in small children through small delivery sheaths;
- High longitudinal flexibility to allow for delivery in/through torturous vessels and maneuverability during deployment;
- Minimal foreshortening at maximal expansion for precise positioning in the vessel, to better match the length of the stenotic lesion;
- Excellent durability to withstand long-term working conditions;
- Open-cell configuration to ensure blood flow in side branches.

Following the trend of medical industries, the best option for great vessel stenting is represented by devices with great expansion potential, characterized by a low profile and small minimum diameter for implantation in newborns. Optimized designs allow for further balloon expansion up to adult size (above 20 mm) without neither stent uncontrolled fracture nor in-stent re-stenting. Of course, a long-term fatigue assessment of these devices is needed to evaluate their durability, since they are expected to have a longer working life than standard adult stenting. Within this context, it is also worth mentioning that some authors advocate the use of bioresorbable stents to overcome the issue of somatic growth accommodation [67,105,114]. Despite the lack of long-term results in coronary artery trials, temporal stenting in the pediatric field seems an attractive option, without any limitation to future vessel growth thanks to the complete resorption of the device. Repeated implantation of new bioresorbable stents might be performed after degradation of the previous one, avoiding in-stent re-stenting, until the vessel reaches a diameter suitable for permanent stent implantation. However, except for some animal trials investigating novel designs [115], no specific studies have been published regarding the development of bioresorbable stents for congenital stenosis. More effort has still to be made in this direction to clearly understand the mechanism regulating stent degradation rate and the progressive decrease in radial force.

Many challenges have still to be overcome in the development of ad hoc devices for the discussed CHD lesions. To support the design phase of a new device, nowadays, patient-specific simulations allow for testing of the implantation procedure to predict structural

and hemodynamic changes [116]. The best match between the device design and the lesion site can be identified by assessing the device's optimal size and positioning and evaluating both the local flow field and the interaction between the device and the surrounding structures. There are examples of numerical models already used for investigating CHDs pathophysiology and the improvement in patient treatment due to personalized stenting solutions [117–120]. Such models, properly integrating structural and hemodynamic patient data, might be effectively used for determining the efficacy of the treatment [121,122].

While taking into account the inherent complexity of congenital heart disease, one can be confident that continued advances in manufacturing technologies and materials production, as well as the study of ad hoc stent design, are paving the way for less invasive treatments with limited surgical components and associated risks, which can increase the life expectancy of patients with complex CHDs.

Author Contributions: Conceptualization, A.B., G.P. and F.B.; writing—original draft preparation, A.B., G.P., L.P. and F.B.; writing—review and editing, A.B., G.P, L.P. and F.B. All authors have read and agreed to the published version of the manuscript.

Funding: The authors acknowledge L'Oréal Italia and UNESCO for the partial support in the frame of the 2023 Italian edition of the "For Women in Science" fellowship assigned to F.B.

Institutional Review Board Statement: Not applicable.

Informed Consent Statement: Not applicable.

Data Availability Statement: Data sharing is not applicable to this article as no new data were created or analyzed in this study.

Conflicts of Interest: The authors declare no conflict of interest.

References

1. Nakamura, K.; Keating, J.K.; Edelman, E.R. Pathology of Endovascular Stents. *Interv. Cardiol. Clin.* **2016**, *5*, 391–403. [CrossRef]
2. Mosayyebi, A.; Manes, C.; Carugo, D.; Somani, B.K. Advances in Ureteral Stent Design and Materials. *Curr. Urol. Rep.* **2018**, *19*, 35. [CrossRef] [PubMed]
3. Sagar, J. Role of Colonic Stents in the Management of Colorectal Cancers. *World J. Gastrointest. Endosc.* **2016**, *8*, 198–204. [CrossRef]
4. Vermeulen, B.D.; Siersema, P.D. Esophageal Stenting in Clinical Practice: An Overview. *Curr. Treat. Options Gastroenterol.* **2018**, *16*, 260–273. [CrossRef] [PubMed]
5. Mangiavillano, B.; Pagano, N.; Baron, T.H.; Arena, M.; Iabichino, G.; Consolo, P.; Opocher, E.; Luigiano, C. Biliary and Pancreatic Stenting: Devices and Insertion Techniques in Therapeutic Endoscopic Retrograde Cholangiopancreatography and Endoscopic Ultrasonography. *World J. Gastrointest. Endosc.* **2016**, *8*, 143–156. [CrossRef]
6. Bentham, J.R.; Zava, N.K.; Harrison, W.J.; Shauq, A.; Kalantre, A.; Derrick, G.; Chen, R.H.; Dhillon, R.; Taliotis, D.; Kang, S.L.; et al. Duct Stenting Versus Modified Blalock-Taussig Shunt in Neonates with Duct-Dependent Pulmonary Blood Flow: Associations with Clinical Outcomes in a Multicenter National Study. *Circulation* **2018**, *137*, 581–588. [CrossRef] [PubMed]
7. Gibbs, J.L.; Rothman, M.T.; Rees, M.R.; Parsons, J.M.; Blackburn, M.E.; Ruiz, C.E. Stenting of the Arterial Duct: A New Approach to Palliation for Pulmonary Atresia. *Heart* **1992**, *67*, 240–245. [CrossRef] [PubMed]
8. Hascoët, S.; Baruteau, A.; Jalal, Z.; Mauri, L.; Acar, P.; Elbaz, M.; Boudjemline, Y.; Fraisse, A. Stents in Paediatric and Adult Congenital Interventional Cardiac Catheterization. *Arch. Cardiovasc. Dis.* **2014**, *107*, 462–475. [CrossRef]
9. Van Gameren, M.; Witsenburg, M.; Takkenberg, J.J.M.; Boshoff, D.; Mertens, L.; Van Oort, A.M.; De Wolf, D.; Freund, M.; Sreeram, N.; Bökenkamp, R.; et al. Early Complications of Stenting in Patients with Congenital Heart Disease: A Multicentre Study. *Eur. Heart J.* **2006**, *27*, 2709–2715. [CrossRef] [PubMed]
10. Dotter, C.T.; Judkins, M.P. Percutaneous Transluminal Treatment of Arteriosclerotic Obstruction. *Radiology* **1965**, *84*, 631–643. [CrossRef]
11. Dotter, C.T.; Buschmann, R.W.; McKinney, R.K.; Rösch, J. Transluminal Expandable Nitinol Coil Stent Grafting: Preliminary Report. *Radiology* **1983**, *147*, 259–260. [CrossRef]
12. Tomberli, B.; Mattesini, A.; Baldereschi, G.I.; Di Mario, C. A Brief History of Coronary Artery Stents. *Rev. Española Cardiol.* **2018**, *71*, 312–319. [CrossRef]
13. Raval, A.; Choubey, A.; Engineer, C.; Kothwala, D. Development and Assessment of 316LVM Cardiovascular Stents. *Mater. Sci. Eng. A* **2004**, *386*, 331–343. [CrossRef]

14. Sun, F.; Mantovani, D.; Prima, F. Carbides and Their Role in Advanced Mechanical Properties of L605 Alloy: Implications for Medical Devices. *Mater. Sci. Forum* **2014**, *783–786*, 1354–1359. [CrossRef]
15. O'Brien, B.J.; Stinson, J.S.; Larsen, S.R.; Eppihimer, M.J.; Carroll, W.M. A Platinum-Chromium Steel for Cardiovascular Stents. *Biomaterials* **2010**, *31*, 3755–3761. [CrossRef] [PubMed]
16. Antonini, L.; Poletti, G.; Pennati, G.; Petrini, L. A Review on the Use of Finite Element Simulations for Structural Analyses of Coronary Stenting: What Can We Do Nowadays and What Do We Need to Move Forward? *Eur. J. Mech. A Solids* **2023**, *101*, 105071. [CrossRef]
17. Duerig, T.W.; Wholey, M. A Comparison of Balloon- and Self-Expanding Stents. *Minim. Invasive Ther. Allied Technol.* **2002**, *11*, 173–178. [CrossRef] [PubMed]
18. MacTaggart, J.N.; Phillips, N.Y.; Lomneth, C.S.; Pipinos, I.I.; Bowen, R.; Baxter, B.T.; Johanning, J.; Matthew Longo, G.; Desyatova, A.S.; Moulton, M.J.; et al. Three-Dimensional Bending, Torsion and Axial Compression of the Femoropopliteal Artery during Limb Flexion. *J. Biomech.* **2014**, *47*, 2249–2256. [CrossRef]
19. Smouse, H.B.; Nikanorov, A.; LaFlash, D. Biomechanical Forces in the Femoropopliteal Arterial Segment. *Endovasc. Today* **2005**, *4*, 60–66.
20. Stoeckel, D.; Pelton, A.; Duerig, T. Self-Expanding Nitinol Stents: Material and Design Considerations. *Eur. Radiol.* **2004**, *14*, 292–301. [CrossRef]
21. Stoeckel, D. Nitinol Medical Devices and Implants. *Minim. Invasive Ther. Allied Technol.* **2000**, *9*, 81–88. [CrossRef]
22. Robertson, S.W.; Pelton, A.R.; Ritchie, R.O. Mechanical Fatigue and Fracture of Nitinol. *Int. Mater. Rev.* **2012**, *57*, 1–37. [CrossRef]
23. Korei, N.; Solouk, A.; Nazarpak, M.H.; Nouri, A. A Review on Design Characteristics and Fabrication Methods of Metallic Cardiovascular Stents. *Mater. Today Commun.* **2022**, *31*, 103467. [CrossRef]
24. Stoeckel, D.; Bonsignore, C.; Duda, S.; Stoeckel, D.; Bonsignore, C.; Duda, S. A Survey of Stent Designs. *Minim. Invasive Ther. Allied Technol.* **2002**, *11*, 137–147. [CrossRef] [PubMed]
25. Maleckis, K.; Anttila, E.; Aylward, P.; Poulson, W.; Desyatova, A.; MacTaggart, J.; Kamenskiy, A. Nitinol Stents in the Femoropopliteal Artery: A Mechanical Perspective on Material, Design, and Performance. *Ann. Biomed. Eng.* **2018**, *46*, 684–704. [CrossRef] [PubMed]
26. Khalaj, R.; Tabriz, A.G.; Okereke, M.I.; Douroumis, D. 3D Printing Advances in the Development of Stents. *Int. J. Pharm.* **2021**, *609*, 121153. [CrossRef]
27. Finazzi, V.; Berti, F.; Petrini, L.; Previtali, B.; Demir, A.G. Additive Manufacturing and Post-Processing of Superelastic NiTi Micro Struts as Building Blocks for Cardiovascular Stents. *Addit. Manuf.* **2023**, *70*, 103561. [CrossRef]
28. Zaccaria, A.; Migliavacca, F.; Pennati, G.; Petrini, L. Modeling of Braided Stents: Comparison of Geometry Reconstruction and Contact Strategies. *J. Biomech.* **2020**, *107*, 109841. [CrossRef]
29. Lee, H.J.; Chang, F.C.; Luo, C.B.; Guo, W.Y. Influence of Stenting with Open-Cell Stents vs. Close-Cell Stents on the Outcomes of Patients with Bilateral Carotid Stenosis. *J. Chin. Med. Assoc.* **2019**, *82*, 66–71. [PubMed]
30. Bruneau, B.G. The Developmental Genetics of Congenital Heart Disease. *Nature* **2008**, *451*, 943–948. [CrossRef]
31. Hoffman, J.I.E.; Kaplan, S. The Incidence of Congenital Heart Disease. *J. Am. Coll. Cardiol.* **2002**, *39*, 1890–1900. [CrossRef] [PubMed]
32. Tennant, P.W.; Pearce, M.S.; Bythell, M.; Rankin, J. 20-Year Survival of Children Born with Congenital Anomalies: A Population-Based Study. *Lancet* **2010**, *375*, 649–656. [CrossRef]
33. Bouma, B.J.; Mulder, B.J.M. Changing Landscape of Congenital Heart Disease. *Circ. Res.* **2017**, *120*, 908–922. [CrossRef] [PubMed]
34. Triedman, J.K.; Newburger, J.W. Trends in Congenital Heart Disease. *Circulation* **2016**, *133*, 2716–2733. [CrossRef] [PubMed]
35. Murphy, P.J. The Fetal Circulation. *Contin. Educ. Anaesth. Crit. Care Pain* **2005**, *5*, 107–112. [CrossRef]
36. Gillam-Krakauer, M.; Mahajan, K. *Patent Ductus Arteriosus*; StatPearls Publishing: Treasure Island, FL, USA, 2023.
37. Rai, V.; Gładki, M.; Dudyńska, M.; Skalski, J. Hypoplastic Left Heart Syndrome [HLHS]: Treatment Options in Present Era. *Indian J. Thorac. Cardiovasc. Surg.* **2019**, *35*, 196–202. [CrossRef]
38. Coats, L.; O'Connor, S.; Wren, C.; O'Sullivan, J. The Single-Ventricle Patient Population: A Current and Future Concern a Population-Based Study in the North of England. *Heart* **2014**, *100*, 1348–1353. [CrossRef]
39. Yabrodi, M.; Mastropietro, C.W. Hypoplastic Left Heart Syndrome: From Comfort Care to Long-Term Survival. *Pediatr. Res.* **2017**, *81*, 142–149. [CrossRef]
40. Wald, R.M.; Mertens, L.L. Hypoplastic Left Heart Syndrome Across the Lifespan: Clinical Considerations for Care of the Fetus, Child, and Adult. *Can. J. Cardiol.* **2022**, *38*, 930–945. [CrossRef]
41. Gobergs, R.; Salputra, E.; Lubaua, I. Hypoplastic Left Heart Syndrome: A Review. *Acta Medica Litu.* **2016**, *23*, 86–98. [CrossRef]
42. Kiserud, T. Physiology of the Fetal Circulation. *Semin. Fetal Neonatal Med.* **2005**, *10*, 493–503. [CrossRef] [PubMed]
43. Gibbs, J.L.; Wren, C.; Watterson, K.G.; Hunter, S.; Hamilton, J.R. Stenting of the Arterial Duct Combined with Banding of the Pulmonary Arteries and Atrial Septectomy or Septostomy: A New Approach to Palliation for the Hypoplastic Left Heart Syndrome. *Br. Heart J.* **1993**, *69*, 551–555. [CrossRef]

44. Hsia, T.Y.; Cosentino, D.; Corsini, C.; Pennati, G.; Dubini, G.; Migliavacca, F. Use of Mathematical Modeling to Compare and Predict Hemodynamic Effects between Hybrid and Surgical Norwood Palliations for Hypoplastic Left Heart Syndrome. *Circulation* **2011**, *124*, 204–210. [CrossRef] [PubMed]
45. Chikkabyrappa, S.M.; Loomba, R.S.; Tretter, J.T. Pulmonary Atresia with an Intact Ventricular Septum: Preoperative Physiology, Imaging, and Management. *Semin. Cardiothorac. Vasc. Anesth.* **2018**, *22*, 245–255. [CrossRef] [PubMed]
46. Siblini, G.; Rao, P.S.; Singh, G.K.; Tinker, K.; Balfour, I.C. Transcatheter Management of Neonates with Pulmonary Atresia and Intact Ventricular Septum. *Cathet. Cardiovasc. Diagn.* **1997**, *42*, 395–402. [CrossRef]
47. Alwi, M. Management Algorithm in Pulmonary Atresia with Intact Ventricular Septum. *Catheter. Cardiovasc. Interv.* **2006**, *67*, 679–686. [CrossRef]
48. Nasr, V.G.; DiNardo, J.A. Pulmonary Atresia/Intact Ventricular Septum (PA/IVS). In *The Pediatric Cardiac Anesthesia Handbook*; John Wiley & Sons, Ltd: Chichester, UK, 2017; pp. 125–129.
49. Gibbs, J.L.; Uzun, O.; Blackburn, M.E.C.; Wren, C.; Hamilton, J.R.L.; Watterson, K.G. Fate of the Stented Arterial Duct. *Circulation* **1999**, *99*, 2621–2625. [CrossRef]
50. Ovaert, C.; Qureshi, S.A.; Rosenthal, E.; Baker, E.J.; Tynan, M. Growth of the Right Ventricle after Successful Transcatheter Pulmonary Valvotomy in Neonates and Infants with Pulmonary Atresia and Intact Ventricular Septum. *J. Thorac. Cardiovasc. Surg.* **1998**, *115*, 1055–1062. [CrossRef]
51. Alcíbar-Villa, J.; Rubio, A.; Peña, N.; Galdeano, J.M.; Luis, M.; Arriola, J.; Inguanzo, R.; Pérez-Asenjo, J.; Aramendi, J.I.; Barrenechea, J.I. Atresia Pulmonar Con Septo Íntegro. Perforación y Valvuloplastia Pulmonar Mediante Técnica Mecánica Modificada. Seguimiento a Medio Plazo. *Rev. Española Cardiol.* **2007**, *60*, 833–840. [CrossRef]
52. Zampi, J.D.; Hirsch-Romano, J.C.; Goldstein, B.H.; Shaya, J.A.; Armstrong, A.K. Hybrid Approach for Pulmonary Atresia with Intact Ventricular Septum: Early Single Center Results and Comparison to the Standard Surgical Approach. *Catheter. Cardiovasc. Interv.* **2014**, *83*, 753–761. [CrossRef]
53. Sohrabi, B.; Jamshidi, P.; Yaghoubi, A.; Habibzadeh, A.; Hashemi-aghdam, Y.; Moin, A.; Kazemi, B.; Ghaffari, S.; Abdolahzadeh Baghayi, M.R.; Mahmoody, K. Comparison between Covered and Bare Cheatham-Platinum Stents for Endovascular Treatment of Patients with Native Post-Ductal Aortic Coarctation. *JACC Cardiovasc. Interv.* **2014**, *7*, 416–423. [CrossRef]
54. Goldstein, B.H.; Kreutzer, J. Transcatheter Intervention for Congenital Defects Involving the Great Vessels. *J. Am. Coll. Cardiol.* **2021**, *77*, 80–96. [CrossRef]
55. Boe, B.A.; Armstrong, A.K.; Janse, S.A.; Loccoh, E.C.; Stockmaster, K.; Holzer, R.J.; Cheatham, S.L.; Cheatham, J.P.; Berman, D.P. Percutaneous Implantation of Adult Sized Stents for Coarctation of the Aorta in Children $\leq$ 20 Kg. *Circ. Cardiovasc. Interv.* **2021**, *14*, E009399. [CrossRef]
56. Castaldi, B.; Ciarmoli, E.; Di Candia, A.; Sirico, D.; Tarantini, G.; Scattolin, F.; Padalino, M.; Vida, V.; Di Salvo, G. Safety and Efficacy of Aortic Coarctation Stenting in Children and Adolescents. *Int. J. Cardiol. Congenit. Heart Dis.* **2022**, *8*, 100389. [CrossRef]
57. Butera, G.; Manica, J.L.L.; Marini, D.; Piazza, L.; Chessa, M.; Filho, R.I.R.; Sarmento Leite, R.E.; Carminati, M. From Bare to Covered. *Catheter. Cardiovasc. Interv.* **2014**, *83*, 953–963. [CrossRef]
58. Ringel, R.E.; Gauvreau, K.; Moses, H.; Jenkins, K.J. Coarctation of the Aorta Stent Trial (COAST): Study Design and Rationale. *Am. Heart J.* **2012**, *164*, 7–13. [CrossRef]
59. Bondanza, S.; Calevo, M.G.; Marasini, M. Early and Long-Term Results of Stent Implantation for Aortic Coarctation in Pediatric Patients Compared to Adolescents: A Single Center Experience. *Cardiol. Res. Pr.* **2016**, *2016*, 4818307. [CrossRef]
60. Trivedi, K.R.; Benson, L.N. Interventional Strategies in the Management of Peripheral Pulmonary Artery Stenosis. *J. Interv. Cardiol.* **2003**, *16*, 171–188. [CrossRef]
61. BACHA, E.A.; KREUTZER, J. Comprehensive Management of Branch Pulmonary Artery Stenosis. *J. Interv. Cardiol.* **2001**, *14*, 367–376. [CrossRef]
62. Feltes, T.F.; Bacha, E.; Beekman, R.H.; Cheatham, J.P.; Feinstein, J.A.; Gomes, A.S.; Hijazi, Z.M.; Ing, F.F.; de Moor, M.; Morrow, W.R.; et al. Indications for Cardiac Catheterization and Intervention in Pediatric Cardiac Disease. *Circulation* **2011**, *123*, 2607–2652. [CrossRef]
63. Ruiz, C.E.; Gamra, H.; Zhang, H.P.; Garcia, E.J.; Boucek, M.M. Stenting of the Ductus Arteriosus as a Bridge to Cardiac Transplantation in Infants with the Hypoplastic Left-Heart Syndrome. *N. Engl. J. Med.* **1993**, *328*, 1605–1608. [CrossRef] [PubMed]
64. Suárez de Lezo, J.; Pan, M.; Romero, M.; Medina, A.; Segura, J.; Lafuente, M.; Pavlovic, D.; Hernández, E.; Melián, F.; Espada, J. Immediate and Follow-up Findings after Stent Treatment for Severe Coarctation of Aorta. *Am. J. Cardiol.* **1999**, *83*, 400–406. [CrossRef]
65. Magee, A.G.; Brzezinska-Rajszys, G.; Qureshi, S.A.; Rosenthal, E.; Zubrzycka, M.; Ksiazyk, J.; Tynan, M. Stent Implantation for Aortic Coarctation and Recoarctation. *Heart* **1999**, *82*, 600–606. [CrossRef] [PubMed]
66. Fogelman, R.; Nykanen, D.; Smallhorn, J.F.; McCrindle, B.W.; Freedom, R.M.; Benson, L.N. Endovascular Stents in the Pulmonary Circulation. *Circulation* **1995**, *92*, 881–885. [CrossRef]
67. Peters, B.; Ewert, P.; Berger, F. The Role of Stents in the Treatment of Congenital Heart Disease: Current Status and Future Perspectives. *Ann. Pediatr. Cardiol.* **2009**, *2*, 3. [CrossRef]
68. Akintürk, H.; Michel-Behnke, I.; Valeske, K.; Mueller, M.; Thul, J.; Bauer, J.; Hagel, K.-J.; Schranz, D. Hybrid Transcatheter–Surgical Palliation. *Pediatr. Cardiol.* **2007**, *28*, 79–87. [CrossRef]

69. Ruiz, C.E. Ductal Stents in the Management of Congenital Heart Defects. *Catheter. Cardiovasc. Interv.* **2001**, *53*, 75–80. [CrossRef]
70. Baba, K.; Chaturvedi, R.; Lee, K.-J.; Caldarone, C.A.; Benson, L.N. Fate of the Ductal Stent after Hybrid Palliation for Hypoplastic Left Heart Syndrome. *Ann. Thorac. Surg.* **2013**, *95*, 1660–1664. [CrossRef]
71. Akintuerk, H.; Michel-Behnke, I.; Valeske, K.; Mueller, M.; Thul, J.; Bauer, J.; Hagel, K.J.; Kreuder, J.; Vogt, P.; Schranz, D. Stenting of the Arterial Duct and Banding of the Pulmonary Arteries: Basis for Combined Norwood Stage I and II Repair in Hypoplastic Left Heart. *Circulation* **2002**, *105*, 1099–1103. [CrossRef]
72. Michel-Behnke, I. Stenting of the Ductus Arteriosus and Banding of the Pulmonary Arteries: Basis for Various Surgical Strategies in Newborns with Multiple Left Heart Obstructive Lesions. *Heart* **2003**, *89*, 645–650. [CrossRef]
73. Hribernik, I.; Thomson, J.; Bentham, J. Deformation and Stenosis of the Sinus-SuperFlex-DS Stent after Ductal Stenting for the Hybrid Stage 1 Procedure. *Catheter. Cardiovasc. Interv.* **2021**, *98*, 533–539. [CrossRef] [PubMed]
74. Bacha, E.A.M.; Hijazi, Z.M. Hybrid Procedures in Pediatric Cardiac Surgery. *Pediatr. Card. Surg. Annu.* **2005**, *8*, 78–85. [CrossRef] [PubMed]
75. Galantowicz, M.; Cheatham, J.P. Lessons Learned from the Development of a New Hybrid Strategy for the Management of Hypoplastic Left Heart Syndrome. *Pediatr. Cardiol.* **2005**, *26*, 190–199. [CrossRef] [PubMed]
76. Betrián-Blasco, P.; Marti-Aguasca, G.; Giralt-Garcia, G. Sinus Superflex DS © Early Collapse in Systemic Arterial Duct. *Cardiol. Young* **2020**, *30*, 436–437. [CrossRef]
77. Goreczny, S.; Qureshi, S.A.; Rosenthal, E.; Krasemann, T.; Nassar, M.S.; Anderson, D.R.; Morgan, G.J. Comparison of Self-Expandable and Balloon-Expanding Stents for Hybrid Ductal Stenting in Hypoplastic Left Heart Complex. *Cardiol. Young* **2017**, *27*, 837–845. [CrossRef]
78. Goreczny, S.; Qureshi, S.; Rosenthal, E.; Krasemann, T.; Bedair, R.; Salih, C.; Austin, C.; Anderson, D.; Morgan, G.J. Self-Expanding Stent Implantation in Arterial Duct during Hybrid Palliation of Hypoplastic Left Heart Syndrome: Midterm Experience with a Specially Designed Stent. *EuroIntervention* **2015**, *10*, 1318–1325. [CrossRef] [PubMed]
79. Schneider, M. Stent Implantation of the Arterial Duct in Newborns with Duct-Dependent Circulation. *Eur. Heart J.* **1998**, *19*, 1401–1409. [CrossRef]
80. Aggarwal, V.; Dhillon, G.S.; Penny, D.J.; Gowda, S.T.; Qureshi, A.M. Drug-Eluting Stents Compared with Bare Metal Stents for Stenting the Ductus Arteriosus in Infants with Ductal-Dependent Pulmonary Blood Flow. *Am. J. Cardiol.* **2019**, *124*, 952–959. [CrossRef]
81. McMullan, D.M.; Permut, L.C.; Jones, T.K.; Johnston, T.A.; Rubio, A.E. Modified Blalock-Taussig Shunt versus Ductal Stenting for Palliation of Cardiac Lesions with Inadequate Pulmonary Blood Flow. *J. Thorac. Cardiovasc. Surg.* **2014**, *147*, 397–403. [CrossRef]
82. Haddad, R.N.; Hanna, N.; Charbel, R.; Daou, L.; Chehab, G.; Saliba, Z. Ductal Stenting to Improve Pulmonary Blood Flow in Pulmonary Atresia with Intact Ventricular Septum and Critical Pulmonary Stenosis after Balloon Valvuloplasty. *Cardiol. Young* **2019**, *29*, 492–498. [CrossRef]
83. Mallula, K.; Vaughn, G.; El-Said, H.; Lamberti, J.J.; Moore, J.W. Comparison of Ductal Stenting versus Surgical Shunts for Palliation of Patients with Pulmonary Atresia and Intact Ventricular Septum. *Catheter. Cardiovasc. Interv.* **2015**, *85*, 1196–1202. [CrossRef]
84. Schranz, D.; Michel-Behnke, I.; Heyer, R.; Vogel, M.; Bauer, J.; Valeske, K.; Akintürk, H.; Jux, C. Stent Implantation of the Arterial Duct in Newborns with a Truly Duct-Dependent Pulmonary Circulation: A Single-Center Experience with Emphasis on Aspects of the Interventional Technique. *J. Interv. Cardiol.* **2010**, *23*, 581–588. [CrossRef] [PubMed]
85. Celebi, A.; Yucel, I.K.; Bulut, M.O.; Kucuk, M.; Balli, S. Stenting of the Ductus Arteriosus in Infants with Functionally Univentricular Heart Disease and Ductal-Dependent Pulmonary Blood Flow: A Single-Center Experience. *Catheter. Cardiovasc. Interv.* **2017**, *89*, 699–708. [CrossRef] [PubMed]
86. Santoro, G.; Palladino, M.T.; Capozzi, G.; Iacono, C.; Russo, M.G.; Calabrò, R. Pulmonary Artery Growth Following Arterial Duct Stenting in Congenital Heart Disease with Duct-Dependent Pulmonary Circulation. *Catheter. Cardiovasc. Interv.* **2009**, *74*, 1072–1076. [CrossRef]
87. Alwi, M.; Choo, K.K.; Latiff, H.A.; Kandavello, G.; Samion, H.; Mulyadi, M.D. Initial Results and Medium-Term Follow-up of Stent Implantation of Patent Ductus Arteriosus in Duct-Dependent Pulmonary Circulation. *J. Am. Coll. Cardiol.* **2004**, *44*, 438–445. [CrossRef] [PubMed]
88. Melvin, T.; Kenny, D.; Gewillig, M.; Fraser, A.G. Orphan Medical Devices and Pediatric Cardiology – What Interventionists in Europe Need to Know, and What Needs to be Done. *Pediatr. Cardiol.* **2023**, *44*, 271–279. [CrossRef]
89. Peiris, V.; Xu, K.; Agler, H.L.; Chen, E.A.; Gopal-Srivastava, R.; Lappin, B.M.; Lewis, D.Y.; Rao, G.R. Children and Adults with Rare Diseases Need Innovative Medical Devices. *J. Med. Device* **2018**, *12*, 034701. [CrossRef]
90. Holzer, R.; Hijazi, Z. The Off-versus on-Label Use of Medical Devices in Interventional Cardiovascular Medicine?: Clarifying the Ambiguity between Regulatory Labeling and Clinical Decision Making, Part III: Structural Heart Disease Interventions. *Catheterizatio. Cardiovasc. Interv.* **2008**, *72*, 848–852. [CrossRef]
91. Matsui, H.; McCarthy, K.; Ho, S. Morphology of the Patent Arterial Duct: Features Relevant to Treatment. *Images Paediatr. Cardiol.* **2008**, *10*, 27–38.
92. Chan, K.C.; Mashburn, C.; Boucek, M.M. Initial Transcatheter Palliation of Hypoplastic Left Heart Syndrome. *Catheter. Cardiovasc. Interv.* **2006**, *68*, 719–726. [CrossRef]
93. Boucek, M.M.; Mashburn, C.; Kunz, E.; Chan, K.-C. Ductal Anatomy. *Pediatr. Cardiol.* **2005**, *26*, 200–205. [CrossRef] [PubMed]

94. Gewillig, M.; Boshoff, D.E.; Dens, J.; Mertens, L.; Benson, L.N. Stenting the Neonatal Arterial Duct in Duct-Dependent Pulmonary Circulation: New Techniques, Better Results. *J. Am. Coll. Cardiol.* **2004**, *43*, 107–112. [CrossRef]
95. Qureshi, A.M.; Goldstein, B.H.; Glatz, A.C.; Agrawal, H.; Aggarwal, V.; Ligon, R.A.; McCracken, C.; McDonnell, A.; Buckey, T.M.; Whiteside, W.; et al. Classification Scheme for Ductal Morphology in Cyanotic Patients with Ductal Dependent Pulmonary Blood Flow and Association with Outcomes of Patent Ductus Arteriosus Stenting. *Catheter. Cardiovasc. Interv.* **2019**, *93*, 933–943. [CrossRef] [PubMed]
96. Lee, K.J.; Hinek, A.; Chaturvedi, R.R.; Almeida, C.L.; Honjo, O.; Koren, G.; Benson, L.N. Rapamycin-Eluting Stents in the Arterial Duct Experimental Observations in the Pig Model. *Circulation* **2009**, *119*, 2078–2085. [CrossRef] [PubMed]
97. Riede, F.T.; Schneider, P.; Dähnert, I. Transient Sirolimus Serum Levels after Implantation of a Sirolimus Eluting Stent in an Infant. *Clin. Res. Cardiol.* **2007**, *96*, 508–510. [CrossRef]
98. McCrossan, B.A.; McMahon, C.J.; Walsh, K.P. First Reported Use of Drug-Eluting Bioabsorbable Vascular Scaffold in Congenital Heart Disease. *Catheter. Cardiovasc. Interv.* **2016**, *87*, 324–328. [CrossRef]
99. van Kalsbeek, R.J.; Krings, G.J.; Molenschot, M.M.C.; Breur, J.M.P.J. Early and Midterm Outcomes of Bare Metal Stenting in Small Children with Recurrent Aortic Coarctation. *EuroIntervention* **2021**, *16*, e1281–e1287. [CrossRef]
100. Hatoum, I.; Haddad, R.N.; Saliba, Z.; Abdel Massih, T. Endovascular Stent Implantation for Aortic Coarctation: Parameters Affecting Clinical Outcomes. *Am. J. Cardiovasc. Dis.* **2020**, *10*, 528–537.
101. Holzer, R.J.; Gauvreau, K.; McEnaney, K.; Watanabe, H.; Ringel, R. Long-Term Outcomes of the Coarctation of the Aorta Stent Trials. *Circ. Cardiovasc. Interv.* **2021**, *14*, E010308. [CrossRef]
102. Forbes, T.J.; Gowda, S.T. Intravascular Stent Therapy for Coarctation of the Aorta. *Methodist Debakey Cardiovasc. J.* **2014**, *10*, 82. [CrossRef]
103. Sadeghipour, P.; Mohebbi, B.; Firouzi, A.; Khajali, Z.; Saedi, S.; Shafe, O.; Pouraliakbar, H.R.; Alemzadeh-Ansari, M.J.; Shahdi, S.; Samiei, N.; et al. Balloon-Expandable Cheatham-Platinum Stents Versus Self-Expandable Nitinol Stents in Coarctation of Aorta: A Randomized Controlled Trial. *JACC Cardiovasc. Interv.* **2022**, *15*, 308–317. [CrossRef]
104. Ewert, P.; Peters, B.; Nagdyman, N.; Miera, O.; Kühne, T.; Berger, F. Early and Mid-Term Results with the Growth Stent—A Possible Concept for Transcatheter Treatment of Aortic Coarctation from Infancy to Adulthood by Stent Implantation? *Catheter. Cardiovasc. Interv.* **2008**, *71*, 120–126. [CrossRef] [PubMed]
105. Zablah, J.E.; Morgan, G.J. Pulmonary Artery Stenting. *Interv. Cardiol. Clin.* **2019**, *8*, 33–46. [CrossRef] [PubMed]
106. Stern, H.J.; Baird, C.W. A Premounted Stent That Can Be Implanted in Infants and Re-Dilated to 20 Mm: Introducing the Edwards Valeo Lifestent. *Catheter. Cardiovasc. Interv.* **2009**, *74*, 905–912. [CrossRef] [PubMed]
107. Ooi, Y.K.; Kim, S.I.H.; Gillespie, S.E.; Kim, D.W.; Vincent, R.N.; Petit, C.J. Premounted Stents for Branch Pulmonary Artery Stenosis in Children: A Short Term Solution. *Catheter. Cardiovasc. Interv.* **2018**, *92*, 1315–1322. [CrossRef]
108. Cheung, Y.F.; Sanatani, S.; Leung, M.P.; Human, D.G.; Chau, A.K.; Culham, J.A. Early and Intermediate-Term Complications of Self-Expanding Stents Limit Its Potential Application in Children with Congenital Heart Disease. *J. Am. Coll. Cardiol.* **2000**, *35*, 1007–1015. [CrossRef]
109. Rajan, P.; Kaur, N.; Barwad, P.; Revaiah, P.; Rohit, M. Coarctation of Aorta Intervention: When Covered Stents Should Have Been First Choice? *Ann. Pediatr. Cardiol.* **2021**, *14*, 204. [CrossRef]
110. Stassen, J.; De Meester, P.; Troost, E.; Roggen, L.; Moons, P.; Gewillig, M.; Van De Bruaene, A.; Budts, W. Covered Stent Placement for Treatment of Coarctation of the Aorta: Immediate and Long-Term Results. *Acta Cardiol.* **2021**, *76*, 464–472. [CrossRef]
111. Cheatham, J.P. Stenting of Coarctation of the Aorta. *Catheter. Cardiovasc. Interv.* **2001**, *54*, 112–125. [CrossRef]
112. Zahn, E.M.; Abbott, E.; Tailor, N.; Sathanandam, S.; Armer, D. Preliminary Testing and Evaluation of the Renata Minima Stent, an Infant Stent Capable of Achieving Adult Dimensions. *Catheter. Cardiovasc. Interv.* **2021**, *98*, 117–127. [CrossRef]
113. Quandt, D.; Knirsch, W.; Michel-Behnke, I.; Kitzmüller, E.; Obradovic, M.; Uhlemann, F.; Kretschmar, O. First-in-Man Pulmonary Artery Stenting in Children Using the Bentley®BeGrow™ Stent System for Newborns and Infants. *Int. J. Cardiol.* **2019**, *276*, 107–109. [CrossRef]
114. Sizarov, A.; Boudjemline, Y. Novel Materials and Devices in the Transcatheter Management of Congenital Heart Diseases—The Future Comes Slowly (Part 1). *Arch. Cardiovasc. Dis.* **2016**, *109*, 278–285. [CrossRef] [PubMed]
115. Reddy, S.R.V.; Welch, T.R.; Nugent, A.W. Biodegradable Stent Use for Congenital Heart Disease. *Prog. Pediatr. Cardiol.* **2021**, *61*, 101349. [CrossRef]
116. Capelli, C.; Sauvage, E.; Giusti, G.; Bosi, G.M.; Ntsinjana, H.; Carminati, M.; Derrick, G.; Marek, J.; Khambadkone, S.; Taylor, A.M.; et al. Patient-Specific Simulations for Planning Treatment in Congenital Heart Disease. *Interface Focus* **2018**, *8*, 20170021. [CrossRef]
117. Biglino, G.; Corsini, C.; Schievano, S.; Dubini, G.; Giardini, A.; Hsia, T.-Y.; Pennati, G.; Taylor, A.M. Computational Models of Aortic Coarctation in Hypoplastic Left Heart Syndrome: Considerations on Validation of a Detailed 3D Model. *Int. J. Artif. Organs* **2014**, *37*, 371–381. [CrossRef] [PubMed]
118. Biglino, G.; Capelli, C.; Bruse, J.; Bosi, G.M.; Taylor, A.M.; Schievano, S. Computational Modelling for Congenital Heart Disease: How Far Are We from Clinical Translation? *Heart* **2017**, *103*, 98–103. [CrossRef]
119. Marsden, A.L.; Feinstein, J.A. Computational Modeling and Engineering in Pediatric and Congenital Heart Disease. *Curr. Opin. Pediatr.* **2015**, *27*, 587–596. [CrossRef]

120. Rigatelli, G.; Chiastra, C.; Pennati, G.; Dubini, G.; Migliavacca, F.; Zuin, M. Applications of Computational Fluid Dynamics to Congenital Heart Diseases: A Practical Review for Cardiovascular Professionals. *Expert Rev. Cardiovasc. Ther.* **2021**, *19*, 907–916. [CrossRef]
121. Levitt, M.R.; McGah, P.M.; Aliseda, A.; Mourad, P.D.; Nerva, J.D.; Vaidya, S.S.; Morton, R.P.; Ghodke, B.V.; Kim, L.J. Cerebral Aneurysms Treated with Flow-Diverting Stents: Computational Models with Intravascular Blood Flow Measurements. *Am. J. Neuroradiol.* **2014**, *35*, 143–148. [CrossRef]
122. Hewlin, R.L.; Kizito, J.P. Development of an Experimental and Digital Cardiovascular Arterial Model for Transient Hemodynamic and Postural Change Studies: "A Preliminary Framework Analysis". *Cardiovasc. Eng. Technol.* **2018**, *9*, 1–31. [CrossRef]