

Review

Fractal Analysis Applied to the Diagnosis of Oral Cancer and Oral Potentially Malignant Disorders: A Comprehensive Review

Maria Contaldo ^{1,*}, Federica Di Spirito ², Maria Pia Di Palo ², Alessandra Amato ³, Fausto Fiori ^{1,*}
and Rosario Serpico ¹

¹ Multidisciplinary Department of Medical-Surgical and Dental Specialties, University of Campania Luigi Vanvitelli, Via Luigi de Crecchio, 6, 80138 Naples, Italy; rosario.serpico@unicampania.it

² Department of Medicine, Surgery and Dentistry, University of Salerno, 84084 Salerno, Italy; fdspirito@unisa.it (F.D.S.); mariapia140497@gmail.com (M.P.D.P.)

³ Department of Neuroscience, Reproductive Science and Dentistry, University of Naples Federico II, 80131 Naples, Italy; aale.amato@gmail.com

* Correspondence: maria.contaldo@unicampania.it (M.C.); fausto.fiori@outlook.com (F.F.)

Abstract: In nature, everything is regular and orderly arranged. The degree of derailment from geometry is related to the disarrangement of living tissues associated with diseases. In the diagnostic field, fractal analysis calculates the fractal dimension (FD), a numerical measure of the degree of regularity of a tissue or structure. As for oral lesions, fractal analysis has been reported to determine the degree of irregular tissue/vascularization derailment mathematically, and this event has been correlated with the nature of the lesion. The purpose of this paper is to evaluate the scientific literature on the fractal analysis of oral cancer and its precursors (oral potentially malignant disorders, OPMDs) to convey whether the specific fractal dimension may be predictive of cancer or the cancerous progression of OPMDs. For this purpose, three databases (PubMed, Scopus, and ISI Web of Science) were investigated according to the PRISMA checklist to answer the following query: "Is fractal analysis a support method to diagnose oral cancer and distinguish it from its precursors?" The risk of biases was also assessed. All original articles published in English were considered; letters, reviews, editorials, and proceedings were excluded.

Keywords: fractal dimension; fractal analysis; oral oncology; oral carcinoma; OPMDs; OSCC



Citation: Contaldo, M.; Di Spirito, F.; Di Palo, M.P.; Amato, A.; Fiori, F.; Serpico, R. Fractal Analysis Applied to the Diagnosis of Oral Cancer and Oral Potentially Malignant Disorders: A Comprehensive Review. *Appl. Sci.* **2024**, *14*, 777. <https://doi.org/10.3390/app14020777>

Academic Editor: Bruno Chrcanovic

Received: 23 November 2023

Revised: 15 January 2024

Accepted: 15 January 2024

Published: 16 January 2024



Copyright: © 2024 by the authors. Licensee MDPI, Basel, Switzerland. This article is an open access article distributed under the terms and conditions of the Creative Commons Attribution (CC BY) license (<https://creativecommons.org/licenses/by/4.0/>).

1. Introduction

Cancers of the lips and oral cavity (ICD C00-06) (oral cancer, OC) are a significant global health concern, with rising incidence in many parts of the world. The last statistics available from the International Agency for Cancer Research (IARC) are related to 2020 and reported 377,713 new cases, a 5-year prevalence of 959,248, and a mortality of 177,757 [1]. OC may arise on apparently healthy oral mucosa or from precursor lesions and conditions with an increased risk of malignancy, collectively named "oral potentially malignant disorders" (OPMDs) [2]. The heterogeneous clinical patterns of OPMDs and OC at its early stages, together with their misdiagnosis, lead to the diagnosis of OC often at its advanced stages, when lymph nodal and distant metastases are already present, and thus are responsible for high mortality and morbidity (related to poor life expectancy and quality) [3–5].

Biopsy procedures and related histopathological assessments are still the gold standard for diagnosing oral lesions suspected of OC [6]. However, various methods (salivary markers, liquid biopsies) and tools (imaging systems) have been developed to obtain more accurate, noninvasive, and timely diagnoses for effective treatments and improved patient outcomes [7–10].

In recent years, rising numbers of digitally assisted medical procedures have been born, as eHealth has irrupted our lives. eHealth, by the definition given by the World Health

Organization, is “the cost-effective and secure use of information and communications technologies (ICT) in support of health and health-related fields” [11].

One such innovative approach to oral-health-related challenges is fractal analysis. Fractal analysis (FA) is a mathematical and computational tool that quantitatively assesses the so-called fractal dimension (FD) of a natural or artificial thing called a “fractal object”, whose irregular and highly intricate structures repeat at different scales, with the peculiar phenomenon of “self-similarity” [12]. Indeed, the shape of a fractal object is usually given by the repetition of regular shapes reproducing its geometry at different scales, thus having a peculiar FD. Another critical point of FA is the “measuring complexity”: FA quantifies the intricate and complex nature of objects that may not have a well-defined, smooth geometry, thus providing a more nuanced understanding of irregular shapes and patterns.

Last, it must be considered that various methods can be employed to calculate fractal dimensions. Each method emphasizes different aspects of the fractal structure. The more common method to measure FD is the box-counting method and its variants, as follows [13]:

- The box-counting method is based on a grid of multiple small boxes at different scales superimposed on the fractal object to analyze and count the boxes needed to cover the object; the relationship between box size and the number of boxes gives the FD.
- Box-counting in 2D (Minkowski–Bouligand dimension) is an extension of the box-counting method wherein the box size is varied, and the relationship between box size and the number of boxes is analyzed.
- Box-counting in 3D is an extension of the box-counting method to three-dimensional objects. Three-dimensional boxes are used to cover the fractal, and the relationship between box size and the number of boxes is analyzed.

Independently from these methods, to simplify, the higher the FD, the more chaotic and irregular the geometry of an object. An example of the application of FA in medicine is when the fractal object is a histopathological specimen: healthy tissues have low FD due to the regularity of their shapes, but the progressive derailment that occurs during pathology or cancerization leads to the disarrangement of their fractal geometry, which will be more complex and is expressed as an increase in its FD [14,15].

On these bases, fractal analysis, when applied to clinical and histological images, can quantitatively assess the complexity and irregularity of structures within these images, thus allowing characterizing and distinguishing patterns, textures, and structures in various medical applications such as diagnosing diseases and evaluating tissue properties [16]. In oncology, fractal analysis has shown its utility for diagnosing, staging, or prognosis of various cancer types, including those of the oropharynx area [17]. This approach can enhance diagnostic accuracy and improve the understanding of the disease’s progression at a microscopic level. Through a comprehensive review, this work aims to explore the application of fractal analysis to diagnose oral cancer and OPMDs to provide scientific evidence to determine whether fractal dimensioning can improve oral cancer diagnosis.

2. Research Methods

2.1. Protocol, Focused Question

This review was performed according to the Preferred Reporting Items for Systematic Reviews and Meta-Analysis (PRISMA) [18]. The search was conducted by investigating three different databases (PubMed, Scopus, and the ISI Web of Science, or WoS) to answer the following focused question: “Is fractal analysis a valid support method to diagnose oral cancer or its precursors in humans?”

2.2. Search and Selection Strategy

The research strategy consisted of the following terms and their synonyms, used in a single query and combined with the Boolean operators (AND, OR): fractal dimension, fractal analysis, oral oncology, oral carcinoma, oral squamous cell carcinoma, oral cancer, oral potentially malignant disorders, lip cancer, actinic cheilitis, leukoplakia, erythroplakia, oral lichen planus, oral ulcers, oral submucous fibrosis, reverse smokers, lupus erythemato-

sus, dyskeratosis congenita, epidermolysis bullosa, chronic hyperplastic candidiasis, oral lichenoid lesions, exophytic verrucous hyperplasia, oral lesions of graft vs. host disease.

The search was conducted in all databases without any restrictions on year of publication, type of publication, language, or species studied. The research and export phase ended on 31 July 2023, and a re-check for novel published articles was performed on 20 September.

The PICO strategy was considered to focus the question [19]:

- The study population (P) consists of humans with oral cancer and oral potentially malignant disorders;
- The intervention (I) was fractal analysis for diagnostic purposes;
- The comparison (C) was with the conventional gold standard diagnosis;
- The outcome (O) was the evaluation of the capability of fractal analysis to diagnose oral cancer and distinguish among oral cancer, oral potentially malignant disorders, and non-neoplastic oral lesions and diseases;
- The study designs (S) included cross-sectional studies, retrospective cohort studies, prospective comparative studies, case-control studies, case series, and case reports.

The following articles were eligible: original studies on humans that underwent fractal analysis (from different kinds of sources, later reported), available full text, and published in English. The exclusion criteria were studies on animal or cellular models. All the reviews, letters, proceedings, meeting abstracts, and editorials were excluded from qualitative analysis but were read for searching the eventually cross-referenced eligible articles. Further exclusion criteria included languages different from English and lack of full-text availability. Two authors performed the quality assessment of the articles (M.C. and F.F.) while, in case of disagreement, a third reviewer was involved (F.D.S.). Data from the eligible papers were organized in tables summarizing, for any study, the reference, the aims, the methods, the sample source that had undergone fractal analysis (clinical macroscopic photographs of the lesions, histological samples at microscopic resolution, vessel architecture, and so on. . .), the main findings, and the conclusions.

3. Characteristics of the Studies

A total of 110 articles were identified. After removing 57 duplicates and 16 articles considered ineligible because of a language different from English or the type (reviews, systematic reviews, editorials, letters, proceedings, and meeting abstracts), the remaining 37 records were screened for inclusion/exclusion criteria by considering their title/abstract. According to this screening, two works not meeting the inclusion criteria were excluded. In total, 35 full texts were read, and 27 of them, fulfilling all the requirements, were considered eligible at the end of the selection (Figure 1).

The 27 eligible studies were published over 30 years (1993–2022) from different countries of origin. Forty-four percent of them were published by Indian research groups [20–31], followed by, per number, four works from Greece [32–35], three from Italy [36–38], and the remaining papers from different countries, such as the UK [39], Romania [40], Germany [41], Canada [42], Taiwan [43], China [44], Poland [45], and Spain [46]. All the main characteristics of the studies are reported in Table 1.

Table 1. Main characteristics of the studies.

	First Author, (Year), Country	Aims of the Study	Sample Source (Fractal Object)	Method of Fractal Dimension Calculation	Methods, Number of Cases, and Type of Lesion	Main Findings	Conclusions
1	Landini (1993), UK [39]	To quantitatively investigate nFD of normal and cancerous oral epithelial cell nuclei	Histological specimens for nuclei assessment in OC	Yardstick method for fractal dimension estimation	Total of 762 nuclei of 10 OC and normal oral mucosa, digitalized images from transmission electron microscope ($\times 1400$)	Statistically significant differences in FD of OC nuclei vs. normal cells' nuclei	Confirmed potential use of FA for diagnosis and prognosis of malignancy.
2	Goutzanis (2008), Greece [32]	To evaluate the nFD in tissue specimens from patients with OC	Histological specimens for nuclei assessment in OC	Implementation of box-counting algorithm in a specially designed application (Fractalyser)	Histological sections from 48 OC and 17 healthy controls to quantify nFD using box-counting method	nFD mean values significantly increased from healthy mucosa to well differentiated and poorly differentiated OC. OC-nFD mean values were higher than normal mucosa. Patients with FD lower than the median value of the sample had statistically significant higher survival rates.	nFD was proved to be an independent prognostic factor of survival in oral cancer patients.
3	Goutzanis, (2009), Greece [33]	To evaluate the vascular FDs in OC to assess their potential value as factors reflecting angiogenesis	Histological specimens for vascular assessment in OC	Box-counting algorithm using the Fractalyser software	Histologic sections from 48 OC and 17 healthy controls to quantify vascular FD	OC presented statistically significant higher mean values of vascular FD compared with normal mucosa.	Vascular FD was a reliable indicator of angiogenesis in oral malignant tumors.
4	Margaritescu, (2010), Romania [40]	To assess the geometry of the lymphatic vessels in oral mucosa utilizing fractal analysis	Histological specimens for lymphatic vessels assessment in OC	Perimeter stepping algorithm using Image-Pro Plus software (Media Cybernetics, Inc., Bethesda, MD, USA)	Comparison between immunohistochemistry images of 20 OC with tumor-free resection margins	Comparison between contour FD values of different pathological conditions of the same area showed no statistically significant difference.	Results not statistically significant
5	Krishnan, (2011), India [30]	To improve the classification accuracy based on different textural features for the development of computer-assisted screening of OSF	Histological specimens for fibrosis in OSF	Modified differential box-counting with sequential algorithm	Involved 45 OSF patients and 10 healthy controls for a total of 90 images of normal oral mucosa, 42 OSF without dysplasia, and 26 OSF with dysplasia. Compared textural features obtained using FA and other textural techniques.	The combination of FD with other textural analyses led to the highest accuracy of 88.38% for classification.	Combining more than two texture measures is most effective in characterizing OSF subtypes.
6	Krishnan, (2012), India [20]	To analyze collagen fibers in the subepithelial connective tissue for accurate OSF screening and classification	Histological specimens for FA of fibrosis in OSF	Differential box-counting	Used 60 normal and 59 OSF images taken from histopathological samples. The segmentation of collagen fibers from histological images was performed using neural networks on color channels. Textural features were extracted from collagen areas using fractal methods like differential box-counting.	F fractal features of collagen under Gaussian transformation improves classification performance from 80.69% to 90.75%.	FA significantly improved the classification of healthy and OSF tissues.
7	Raja, (2012), India [21]	To investigate the usefulness of texture analysis in the OC characterization To evaluate its effectiveness in distinguishing between different grades of tumors	Computed tomography of OC	Differential box-counting	Compared 21 computed tomography images of OC patients. Two ROIs were identified: one at the site of the lesion and the other on the normal, unaffected side of the buccal mucosa. Texture analysis measures, specifically FD and gray level co-occurrence matrix (GLCM), in both ROIs.	Statistically significant differences between the mean FD and GLCM parameters of the lesion ROI and the normal ROI	FD demonstrated its usefulness in distinguishing between normal and pathological tissues, but it could not play a role in tumor grading detection.

Table 1. Cont.

	First Author, (Year), Country	Aims of the Study	Sample Source (Fractal Object)	Method of Fractal Dimension Calculation	Methods, Number of Cases, and Type of Lesion	Main Findings	Conclusions
8	Klatt, (2014), Germany [41]	To assess the potential of calculated fractal dimension FD of time-resolved autofluorescence in discriminating tumors from healthy tissues of the oral cavity	Histological fluorescence in OC	Fractal dimension based on time-resolved autofluorescence spectra	Histological samples from 15 OC and 22 healthy controls. After time-resolved fluorescence measurements, the FD was calculated by using an algorithm based on the non-exponential decay behavior of autofluorescence.	FD was significantly higher in OC than in healthy tissues, at 86% specificity and 100% sensitivity.	FD, based on time-resolved autofluorescence spectra, had promising potential in real-time detection of OC.
9	Spyridonos, (2014), Greece [34]	To quantify the morphological irregularities of the lower lip border, to validate its discriminative power in solar cheilosis diagnosis, and to provide supportive tools toward cost effective, noninvasive disease monitoring	Clinical picture of actinic cheilitis	Box-counting method and Sevcik approximation	Clinical pictures from 50 subjects were used. Two different methods for estimating FD were employed: the box-counting method (FD _{bc}) and a method proposed by Sevcik (FD _s).	FD yielded the highest accuracy in discriminating patients from controls, resulting in 98% sensitivity and 94% specificity.	FA to evaluate lip contour irregularities might be effective in distinguishing healthy lips from solar cheilosis-affected lips.
10	Bose, (2015), Canada [42]	To propose a method that integrates multiple histopathological features of the tumor microenvironment into a single, digital pathology-based biomarker using nFD analysis	Microarray nuclei evaluation DAPI-stained images of tissue microarray (TMA) cores	Box-counting	A total of 107 consecutive OC patients were classified using nFD scores of nuclei stained with DAPI from TMA.	High nFD was significantly associated with pT-stage and RT. High nFD of the total tumor microenvironment was significantly associated with improved disease-specific survival. High nFD was significantly associated with high tumor proliferation and lymphatic invasion.	nFD analysis integrates known prognostic factors from the tumor microenvironment, such as proliferation and immune infiltration, into a single digital pathology-based biomarker.
11	Lucchese, (2015), Italy [36]	To assess local vascular architecture in atrophic-erosive OLP	OPL capillaroscopy	Box-counting	Used 31 OLP patients and 32 healthy controls. The images captured with capillaroscopy were converted to 8-bit grayscale, and the box-counting method was used to assess the FD.	Statistically significant differences in the FD of vessels' density in OLP and healthy controls	Microvessel density analysis could be used as a parameter in determining potential malignant progression of OLP lesions, but more studies are needed.
12	Mincione, (2015), Italy [37]	To investigate FD as an OC prognostic tool by correlating FD values with clinicopathological features and survival of OC patients	Immunohistochemistry of podoplanin in OC	Box-counting	Used 64 OC and 10 healthy controls. Postproduction analysis of the specimen images was performed, and the box-counting method was used to assess FD. Podoplanin expression in tumor-free resection margins of OC	The mean FD values difference was statistically significant between the control and test groups. Increasing value of FD statistically correlated with different stages, grades, and survival of OC.	FD correlates with OC histological grade and stage and can be used for prognosticating OC survival.
13	Ou-Yang, (2015), Taiwan [43]	To develop a combination of textural and spectral methods for diagnosing OC	Histological images from an inverted microscope	Morphology-based fractal dimension method for tissue discrimination	Total of 34 OC and 34 patient-related healthy mucosa	FD had 90% sensitivity and 88% specificity in distinguishing among OC and healthy mucosa.	FD was effective in detecting OC in biopsies with high sensitivity and specificity.
14	Pandey, (2015), India [22]	To evaluate the FD of OL compared with normal oral mucosa and the changes during and after treatments	Clinical pictures of OL	Box-counting	Clinical pictures of 50 OL and 50 normal mucosa considered for FA after postproduction ROI selection.	The difference between the two groups was statistically significant. The difference in FDs between pretreated and post-treated lesions was observed and was suggestive of decreased FD.	FA can be an effective, economical, and noninvasive diagnostic and prognostic tool for OL.
15	Spirydonos, (2015), Greece [35]	To determine robust macro-morphological descriptors of the vermilion border from non-standardized digital photographs	Clinical picture of actinic cheilitis	Box-counting method and Sevcik approximation	Clinical images from 75 AC and 75 healthy controls. Lip borders quantified on the basis of the extent of vermilion retraction and the degree of border irregularity employing fractal features.	The different FD values were related with individual variabilities other than the status (AC vs. healthy lips).	The proposed method opens new perspectives toward a cost-effective, noninvasive monitoring of AC.

Table 1. Cont.

	First Author, (Year), Country	Aims of the Study	Sample Source (Fractal Object)	Method of Fractal Dimension Calculation	Methods, Number of Cases, and Type of Lesion	Main Findings	Conclusions
16	Yinti, (2015), India [23]	To assess nuclear morphologic complexity with nFD obtained from computer-aided image analysis and correlate the fractal dimension with clinical features	Histological specimens for nuclei assessment in OC	Sarkar box-counting method	Histopathological and postproduction analysis of 14 OC and 6 healthy controls. After hematoxylin and eosin for histopathological assessment, Feulgen staining was performed to evaluate nuclear complexity. Using Adobe Adobe PhotoShop CS and ImageJ software 1.43u (Wayne Rasband, National Institutes of Health, Bethesda, USA), postproduction analysis was performed.	Higher mean nFD was observed in the OC group compared with the control group. Significant difference in the average value of nFD between the four stages of the disease. Patients with FD value ≤ 1.71 showed a higher survival period of 72 months, while patients with FD > 1.71 showed a lower survival period of 36 months.	nFD seemed a reliable diagnostic tool that need standardization to be validated, but the data collected suggest the possible use of FD also as a prognostic factor.
17	Phulari, (2016), India [24]	To compare the morphometric complexity using nFD in normal, epithelial dysplasia, and OC cases and to verify the differences among the various histological grades of dysplasia and OC	Histological specimens for assessment for distinguishing OC and various degrees of dysplasia	Box-counting	Used 70 histological samples of normal mucosa, mild dysplasia, moderate dysplasia, severe dysplasia, well-differentiated OC, moderately differentiated OC, and poorly differentiated OC. The images were analyzed using ImageJ and the box-counting algorithm.	Progressive increase in mean FD from healthy mucosa to poorly differentiated OC.	FA could be a reliable tool for distinguishing the normal, dysplastic, and neoplastic tissues.
18	Das, (2017), India [25]	To develop a microscopic image analytics approach for automated recognition of mitotic cells and its count for assisting pathological evaluation of OC	Histological specimens for assessment of mitotic cells	Modified differential box-counting method	Five histological slides for each grade, fifteen slides, and ten images for every region of interest. FD was calculated using the box-counting method.	Found 89% precision in mitotic cell segmentation.	The proposed methodology was effective for mitotic cell detection in OC histopathological images.
19	Yang, (2017), China [44]	To quantitatively examine the DNA content and nuclear morphometry status of OL and investigate their association with the degree of dysplasia	Cytology study to assess DNA content amount, nuclear shape, area, radius, intensity, sphericity, entropy, and nFD	Not specified	Cytobrush samples from 70 OLs, before the scalpel biopsy, were stained with Feulgen-thionin.	A total of 48.6% of the OLs had a DNA content abnormality; positive correlation was observed between the degree of oral dysplasia and DNA content status.	DNA content and nuclear morphometric status using cytobrush biopsy with image cytometry contribute to diagnosing high-grade dysplasia within OL.
20	Daddazio, (2018), Italy [38]	To consider a possible correlation between the intensity of expression of osteopontin and grading in OC To correlate the increase in FD and osteopontin	Histological OC	Box-counting	Used 64 OC and 14 healthy controls and immunohistochemical stain to identify and localize osteopontin. Postproduction analysis was performed using ImageJ and the box-counting method.	Statistically significant differences found in the FD values between the test group and controls. Correlation between FD and OPN expression was visually more considerable when divided by tumor grading, especially in the G3 group.	The study suggests a potential correlation between osteopontin expression, FD values, and OC grading. Combining these factors may enhance diagnostic accuracy and prognostic evaluation.
21	Jurczyszyn, (2018), Poland [45]	To distinguish OL and OLP using FA in a classical examination with white light and PDD	Clinical photos and photodynamic diagnosis photos of OL and OLP	Modified box-counting	In 41 patients with OL or OLP, photodynamic therapy (PDT) with 5-ALA was administered, and FA was conducted using the Fractalyse program to evaluate the efficacy of PDT in treating oral lesions.	No significant differences were observed between the FDs of OL and OLP.	Variations within groups were noted, although its utility in distinguishing between LP and leukoplakia without histopathological examination remains inconclusive.

Table 1. Cont.

First Author, (Year), Country	Aims of the Study	Sample Source (Fractal Object)	Method of Fractal Dimension Calculation	Methods, Number of Cases, and Type of Lesion	Main Findings	Conclusions	
22	Iqbal, (2020), India [26]	To assess the efficacy of FA in detecting the malignancy potential of OL	Clinical photo after toluidine blue staining of OL	Box-counting	In 121 OL and healthy controls, digital images of normal mucosa and lesions were taken before and after staining with toluidine blue. Postproduction analysis performed using the box-counting method.	FD values showed a significant difference between dysplastic and nondysplastic cases. FD values based on age and the type of tobacco product used indicated an increasing trend with advancing age. Surti/khaini abusers showed a significant difference in FD values. The correlation of FD values with age and the duration of smoking and smokeless tobacco was highly significant.	FD analysis could be used as a noninvasive, cost-effective diagnostic tool for the early detection of malignant conversion.
23	Nawn, (2021), India [27]	To explore and analyze oral differences in FD among normal mucosa, OSF, OSF with dysplasia, OL, and OC	Histopathological images	Not specified	Histological sections of healthy mucosa, OSF, OSF with dysplasia, OL, and OC were considered for tissue grading and FA.	Discriminative multifractal signatures for healthy and pathological tissues	FA was useful to distinguish alterations in the singularity spectrum width across healthy, pre-cancerous, and cancerous tissues.
24	Sharma, (2021), India [28]	To understand the crystallization patterns in saliva and their relation to oral potentially malignant disorders in male patients	Salivary specimens for assessment of crystallization pattern in OSF, OL, and OC	Not specified	Dried salivary films from patients with OSF, OL, and OC were examined under a stereo-zoom microscope to select ROIs for fern structure analysis.	Significant differences in FD among normal individuals and those with OSF, OL, and OC	Saliva could serve as a potential imaging biomarker for the early-stage, noninvasive diagnosis of OPMDs and OC.
25	Guerrero-Sánchez, (2022), Spain [46]	To assess dysplasia	Histological specimens for assessment of FD of in OL	Modified box-counting	A total of 29 OL and 10 normal oral mucosa biopsies were analyzed using FA for the epithelial and the connective layer.	In the OL group, the FD median value was higher compared with the control group, with statistically significant differences. Significant differences were observed between the non-dysplasia vs. high-grade and low-grade vs. high-grade groups.	FD is an effective tool for diagnosing OL when evaluating the epithelial layer.
26	Rahman, (2022), India [31]	To evaluate differences in nFD values of epithelial cells of normal tissue, fibroepithelial hyperplasia, verrucous carcinoma, and OSCC. Also, the correlation between these features and the cervical lymph node metastasis was assessed.	Histological specimens for assessment of epithelial cells from fibroepithelial hyperplasia, verrucous carcinoma, and OSCC	Box-counting	Photo of samples underwent postproduction analysis with Image J. All the clinical features were then compared with the image analysis results.	Significant difference between the mean nFD of healthy cells and malignant epithelial cells. nFD and grading together demonstrated significant predictive potential for lymph node metastasis.	nFD combined with grading may predict lymph node metastasis.
27	Santolia, (2022), India [29]	To assess the fractal dimension (FD) and radiomorphometric indices (RMIs) in the mandible from orthopantomographic radiographs in patients with oral lesions	Radiological images in patients with tobacco and areca-nut-associated oral lesions	Box counting method by White and Rudolph	FD and radiomorphometric indices were assessed, along with participant habits, BMI, and statistical analyses.	Mean FD was significantly reduced in patients with oral lesions compared with controls. FD and RMI values were significantly altered in patients with oral lesions associated with tobacco and areca nut habits.	These imaging parameters could potentially serve as indicators or markers for assessing oral health in individuals with specific tobacco and areca nut habits in the North Indian population.

AC, actinic cheilitis; DAPI, 4',6-diamidino-2-phenylindole; FA, fractal analysis; FD, fractal dimension; nFD, nuclear fractal dimension; OC, oral cancer; OL, oral leukoplakia; OLP, oral lichen planus; OSCC, oral squamous cell carcinoma; OSF, oral submucous fibrosis; PDD, photodynamic diagnosis; pT, pathological state grade; ROI, region of interest; RT, radiation treatment; TMA, tissue microarray.

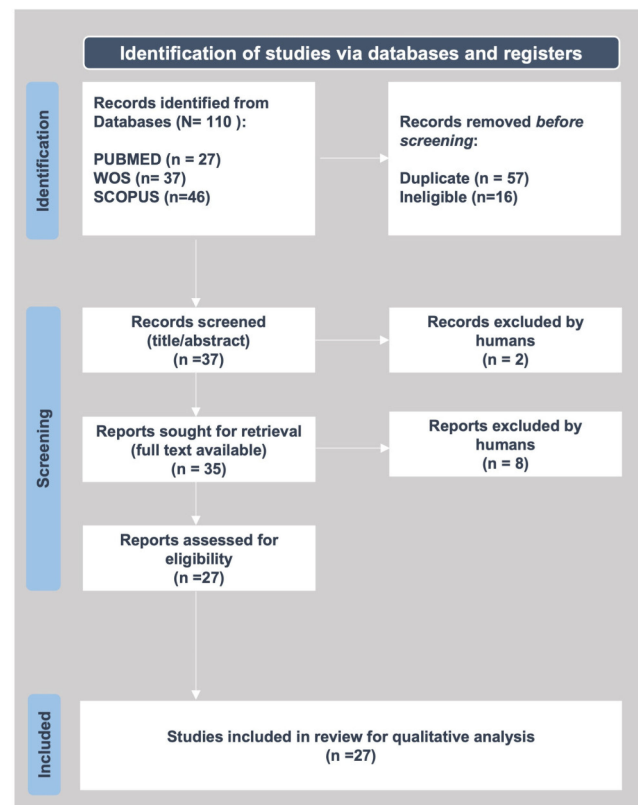


Figure 1. PRISMA flowchart.

3.1. FA Methodologies and Tools

The first method reported to measure the fractal dimension was the “yardstick method” used in 1993 by Landini et al. [39] and consisting of a ruler to manually measure the perimeters of nuclei from normal and cancerous keratinocytes from histological specimens that were magnified up to $\times 1400$, photographed and further enlarged 2.6 times, with a black-and-white scanned photograph at a final resolution of 1 pixel equal to 35 nm.

Then, Goutzanis et al. [32,33] adopted the box-counting method to measure the nuclear periphery, its inner structure complexity, and the tumor-associated vasculature FD. In their works, the authors reported a significant positive correlation between FD and the size of the neoplastic nuclei, with FD values generally higher in carcinomas than in the control group and a statistically significant difference in FD between well-differentiated tumors and moderately or poorly differentiated ones.

Since then, the box-counting method and its variants have become the most used method. Box-counting was refined year after year, owing to the rising technological and informatics improvements of specific tools to acquire high-definition images, such as CDD cameras, which replaced scanned analog conventional photographs. Image processing software is consistently more accurate and precise in performing textural analysis in the RGB channel; this is then transformed into grayscale and later into binary images for better definition through semi-automatized and automatized image analyses with neural network supports.

3.2. Fractal Objects

The sample source objects for the fractal analyses comprised histological specimens, clinical pictures, radiological images, salivary samples, and cytobrushes. The main application of the FD was to perform textural features for improved classification of oral histopathological images. The most frequent purpose that emerged from the studies was diagnosis to discriminate among normal mucosa, various degrees of dysplasia, OPMDs, and OC. Other research focused on the prognostic significance of nuclear fractal dimensions

among oral squamous cell carcinoma (OSCC), thus relating to other classical prognostic factors such as lymphatic invasion or tumoral neovascularization. Other works explored multifractal alterations in the oral subepithelial connective tissue during the progression of pre-cancer and cancer or else integrated tumor and stromal features into a single prognostic factor of the oral cancer microenvironment [38]. Some reports further explored the nuclear fractal dimension in oral squamous cell carcinoma to evaluate grading, staging, and survival.

Fractal analysis was predominantly applied to the analysis of the nuclear fractal dimension [23,24,31,32,39,43], in some cases supported by adjunct methods such as fluorescent or immunohistochemical staining [37,38,41,42], while other authors considered the fractal analysis to detect mitotic cells [25]. In some works, the vascular fractal dimension [33] or the geometry of the lymphatic vessels [40] was considered instead.

Additionally, other works focused on the textural features of the epithelial-connective interface and its regularity or irregularity in healthy specimens compared with oral submucous fibrosis (OSF), dysplastic, and cancerous specimens [20,27,30,46], or they studied the OC-associated vasculature [33,36].

Furthermore, apart from the classical nuclear fractal dimension, some researchers used immunohistochemical and fractal analysis to focus on specific OC-related cell markers according to their nuclear localization and quantification, such as D'Addazio et al. [38], who investigated osteopontin, or Margaritescu et al. [40], who investigated podoplanin expression.

Some cumulative methods added to conventional histology were variously considered, from time-resolved autofluorescence to discriminate tumors from healthy tissues in the oral cavity [41] to tissue microarrays to differentiated nuclear/cytoplasmic biomarkers localization [42].

Apart from histological samples, some research groups considered alternative sources to be analyzed via fractal analysis. Sharma et al. [28] conducted multifractal texture analysis of salivary fern patterns for oral pre-cancers and cancer assessment. Alternatively, Raja et al. [21] performed texture analysis of CT images to characterize oral cancers involving the buccal mucosa. Similarly, Santolia et al. [29] investigated fractal dimension and radiomorphometric analysis of orthopantomographic radiographs in patients with tobacco- and areca-nut-associated oral mucosal lesions. The Greek group of Spyridonos et al. [34,35] compared the fractal dimension of actinic cheilitis and healthy lips from clinical pictures of the vermilion borders.

Apart from actinic cheilitis, among the OPMDs, FD was widely and preponderantly investigated in oral leukoplakia [22,26,44–47] and oral submucous fibrosis (OSF) [20,27,28,30], mainly by the Indian groups, where OSF is endemic [47]. Regarding OLP, different preliminary studies investigated fractal analysis of mucosal microvascular patterns [36] and fractal dimension analysis to differentiate between lichen planus and leukoplakia [45].

4. Fractal Analysis to Support Oral Cancer and OPMDs Diagnosis and Prognosis

From the analysis of the results presented in the selected literature, fractal analysis can be globally considered to be a valid supporting method to diagnose oral cancer or its precursors in humans.

The most frequently investigated parameter that gave, in general, supportive robust results was the nuclear fractal dimension (nFD). nFD was statistically significantly different in OC nuclei than in normal cell nuclei [23,24,26,38,39]. In detail, a progressive increase in the mean FD was shown from healthy mucosa to poorly differentiated OC. These pieces of evidence were strengthened by the statistical analysis of Klatt et al., who reported that nFD was significantly higher in tumors than in healthy tissues, with an 86% specificity and 100% sensitivity [41], and confirmed by Ou-Yang et al. [43], who reported a similar high sensitivity rate (correctly identifying cancerous cells) and high specificity rate (correctly identifying normal cells). Furthermore, the nuclear fractal dimension was also proved to be an independent prognostic factor of survival in oral cancer patients, while, in syn-

ergy with the grading, it demonstrated significant predictive potential for lymph node metastasis [31–33].

Furthermore, nFD also correlated with prognostic factors from the tumor microenvironment, such as proliferation and immune infiltration, into a single digital pathology-based biomarker [22,32,42].

The exact significance was also reported in those studies in which the fractal object was a histological section. In these cases, the FD of histological architecture and the epithelial-connective interface of healthy mucosa compared with OC or OPMDs significantly differed [21,27].

Moreover, fractal analysis applied to vasculature also revealed its efficacy as a prognostic parameter to determine the potential malignant progression of OLP lesions based on the microvessel density analysis [36]. Statistically significant differences were also reported concerning the vascular fractal dimension of OC compared with normal mucosa [33].

Limitations of the Studies

Not all applications of fractal analysis to support OC and OPMD diagnosis were successful. In some cases, the results did not reach statistical significance; in others, they failed.

As an example, the studies on actinic cheilitis did not find the fractal analysis to be effective in distinguishing healthy lips from solar cheilosis-affected lips [34]. However, it must be considered that clinical pictures instead of histological samples were used for fractal analysis in these cases.

In fact, a key point first highlighted by Landini et al. [39] was that “the irregularity is not fully reproduced at all scales”. They noticed that the same nuclear borders appeared more irregular at lower magnification and smoother at higher magnification.

Hence, the fractal object and methodology must be accurately chosen, from the acquisition mode, to the image magnification and processing, up to the fractal analysis methods.

Furthermore, it is not always true that “more is better”: in some cases, combining fractal analysis with other texture measures did not reveal significant advantages over fractal analysis alone in discerning subtypes and grades of similar histopathological diseases [30] or among different OPMDs such as oral lichen planus and leukoplakia [45].

5. Discussion and Conclusions

Modern medicine and dentistry require the growing support of digital technologies to improve the diagnostic, therapeutic, and follow-up processes in patient management, including and especially cancer patients, where the timeliness and precocity of diagnosis and intervention, and knowledge of the prognosis related to novel parameters, can make the difference between life and death.

Digital aid is conveyed by the practice of eHealth, recently regulated by the World Health Organization [48].

One such innovative approach to oral health-related challenges in oral oncology is fractal analysis to assess quantitatively the regularity/irregularity of patterns mathematically and digitally in healthy mucosa compared with OC and OPMDs.

The present review affirmatively answered whether fractal analysis could be considered a valid support method to diagnose oral cancer or its precursors in humans.

Indeed, fractal analysis succeeded in the measurement and quantification of changes in the morphological complexity of the epithelial, connective, and vascular components of the tumor.

In detail, the box-counting method was the most frequently used. However, it was possible to assist, year after year, in the refinement of the method and the increasing support of digital processes for image analysis, from conventional photographs scanned and manually segmented up to the acquisition through CDD cameras and integrated software, thus resulting in more accurate and standardized textural analyses.

The keratinocyte nuclear boundary was the most frequently considered and most significant fractal object. The mean nuclear fractal dimension (nFD) progressively increased from healthy oral keratinocytes to those from poorly differentiated OC, thus being considered an independent prognostic factor of survival in oral cancer patients. Furthermore, the nFD prognostic significance was enhanced when grading, immune infiltration, and tumoral neovascularization were correlated.

Other works focused on this last feature, the pattern of tumor-associated neovascularization, thus reporting statistically significant differences between the vascular density of OC compared with healthy mucosa.

A third most frequent fractal object was the epithelial-subepithelial interface, whose FD statistically significantly differed between healthy mucosa and OC and between healthy mucosa and OPMDs.

Last, the fractal analyses failed in some works, such as those on solar cheilitis. In these cases, it was unclear whether the failure to discriminate was due to the fractal object considered (a clinical picture) or to the pathological features not adequately investigated through fractal analysis.

Furthermore, few works—only 27—have emerged from the literature. They are very heterogeneous, considering the source analyzed (mainly clinical pictures or histological specimens), the diseases investigated, the methodologies of fractal analysis, and the significance of the results.

These limitations are mainly related to the preliminary nature of these works, which, although pioneering, need more extended and standardized studies to be consolidated and considered for clinical applications.

6. Future Directions

In summary, fractal analysis provides a powerful tool for characterizing and understanding complex, irregular patterns and structures that may not fit well within traditional geometric frameworks. It has broad applications across various scientific disciplines and has contributed to a deeper understanding of the complexity inherent in natural and artificial systems.

In oral oncology, fractal analysis is worthy of consideration because it can be an effective and noninvasive diagnostic and prognostic tool for various premalignant lesions and conditions. It is economical, less time-consuming, and an accurate tool for measuring the progression of premalignant lesions [22], mainly when applied to clinical pictures, thus opening new perspectives toward cost-effective, noninvasive monitoring of OPMDs and suspicious lesions to support the patients' management [35].

Indeed, the fractal analysis could be applied virtually to all clinical and histological procedures to obtain significant progress in managing oral cancer and its precursors, to offer the capability to distinguish among oral lesions that are similar in shape but different in prognosis.

At this point, it is reasonable to hypothesize the future directions for fractal analysis in oral oncology and modern dentistry.

First, fractal analysis could be investigated for benefits in association with other digitally assisted imaging systems, such as *in vivo* microscopy, thus improving the qualitative assessment of *in vivo*-detected histological and cytological differences among OPMDs and OSCCs with mathematical analysis. In this case, *in vivo* confocal microscopy itself already has proven to be dramatically helpful, for diagnosing the early signs of malignancies/pathology in living tissues before biopsy, offering digital pictures of living tissues at microscopic resolution that could be fit to be considered appropriate fractal objects in future works, and for measuring the fractals of nuclear shapes, cellular borders, and/or other parameters easily visible and defined through this *in vivo* technique [49,50].

Second, apart from histological samples and clinical photographs, it could be interesting to test the fractal analysis applied to innovative imaging procedures, which could fit well with the application of fractal analysis of vascular patterns, already proven to

be distinct through conventional capillaroscopy, which will benefit from a mathematical analysis for diagnostic and prognostic purposes.

Third, fractal analysis could be used to estimate responsiveness to treatments.

Although the present review focused on the diagnostic and prognostic value of fractal analysis in oral oncology, the literature reported some sporadic and preliminary works dealing with the monitoring of treatments as reported by the Polish group of Jurczyszyn et al. [51,52], who applied fractal dimension and texture analysis of lesion autofluorescence in the evaluation of oral lichen planus treatment effectiveness and in estimating the effectiveness of oral leukoplakia treatment using the LiteTouch™ Er:YAG Dental laser, or by Varsha et al., who recently explored the pre- and post-treatment objective evaluation of remission in oral lichen planus using fractal analysis and compared it with the visual analog (VAS) scale [53].

Moreover, it could be interesting to understand if fractal analysis could also be valuable for characterizing, distinguishing, and evaluating HPV-related oral and oropharyngeal lesions due to the evidence that HPV DNA integrates with human keratinocytes' DNA, giving origin to HPV-associated cancers.

Last, to revolutionize oral cancer diagnosis and make the most of the potential of fractal analysis in oral oncology, it could be integrated with machine learning and other artificial intelligence-enhanced tools, as demonstrated in the case of breast and colon cancers [54,55].

Author Contributions: Conceptualization, M.C. and R.S.; methodology, M.C. and F.D.S.; investigation, F.F. and A.A.; data curation, M.C. and M.P.D.P.; writing—original draft preparation, M.C. and F.D.S.; writing—review and editing, M.C. and F.F.; supervision, M.C. and R.S. All authors have read and agreed to the published version of the manuscript.

Funding: This research received no external funding.

Institutional Review Board Statement: Not applicable.

Informed Consent Statement: Not applicable.

Data Availability Statement: Not applicable.

Conflicts of Interest: The authors declare no conflicts of interest.

References

1. Miranda-Filho, A.; Bray, F. Global Patterns and Trends in Cancers of the Lip, Tongue and Mouth. *Oral Oncol.* **2020**, *102*, 104551. [[CrossRef](#)] [[PubMed](#)]
2. Warnakulasuriya, S. Oral Potentially Malignant Disorders: A Comprehensive Review on Clinical Aspects and Management. *Oral Oncol.* **2020**, *102*, 104550. [[CrossRef](#)] [[PubMed](#)]
3. Mauceri, R.; Bazzano, M.; Coppini, M.; Tozzo, P.; Panzarella, V.; Campisi, G. Diagnostic Delay of Oral Squamous Cell Carcinoma and the Fear of Diagnosis: A Scoping Review. *Front. Psychol.* **2022**, *13*, 1009080. [[CrossRef](#)] [[PubMed](#)]
4. Contaldo, M.; Di Napoli, A.; Pannone, G.; Franco, R.; Ionna, F.; Feola, A.; De Rosa, A.; Santoro, A.; Sbordone, C.; Longo, F.; et al. Prognostic Implications of Node Metastatic Features in OSCC: A Retrospective Study on 121 Neck Dissections. *Oncol. Rep.* **2013**, *30*, 2697–2704. [[CrossRef](#)]
5. Mascitti, M.; Togni, L.; Caponio, V.C.A.; Zhurakivska, K.; Bizzoca, M.E.; Contaldo, M.; Serpico, R.; Lo Muzio, L.; Santarelli, A. Lymphovascular Invasion as a Prognostic Tool for Oral Squamous Cell Carcinoma: A Comprehensive Review. *Int. J. Oral Maxillofac. Surg.* **2021**, *51*, 1–9. [[CrossRef](#)]
6. Chasma, F.; Pedr King, R.; Ker, S.Y. Are There Diagnostic Alternatives to Histopathology in Detecting Oral Cancer? *Evid. Based Dent.* **2022**, *23*, 24–25. [[CrossRef](#)]
7. Anders, P.L.; Davis, E.L.; Reuland-Bosma, W.; Van Dijk, J.; Nakagawa, I.; Amano, A.; Ohara-Nemoto, Y.; Endoh, N.; Morisaki, I.; Kimura, S.; et al. Electronic Cigarette: Users Profile, Utilization, Satisfaction and Perceived Efficacy. *Spec. Care Dent.* **2015**, *11*, 30–35. [[CrossRef](#)]
8. Mauceri, R.; Coppini, M.; Vacca, D.; Bertolazzi, G.; Panzarella, V.; Di Fede, O.; Tripodo, C.; Campisi, G. Salivary Microbiota Composition in Patients with Oral Squamous Cell Carcinoma: A Systematic Review. *Cancers* **2022**, *14*, 5441. [[CrossRef](#)]
9. Romano, A.; Di Stasio, D.; Petrucci, M.; Fiori, F.; Lajolo, C.; Santarelli, A.; Lucchese, A.; Serpico, R.; Contaldo, M. Noninvasive Imaging Methods to Improve the Diagnosis of Oral Carcinoma and Its Precursors: State of the Art and Proposal of a Three-Step Diagnostic Process. *Cancers* **2021**, *13*, 2864. [[CrossRef](#)]
10. Sreeshma, B.; Sivakumar, D.; Maiti, D.; Devi, A. Biomarkers in the Progression and Metastasis of Oral Squamous Cell Carcinoma. *J. Stem Cells* **2022**, *16*, 127–161.

11. Penedo, F.J.; Oswald, L.B.; Kronenfeld, J.P.; Garcia, S.F.; Cella, D.; Yanez, B. The Increasing Value of EHealth in the Delivery of Patient-Centred Cancer Care. *Lancet Oncol.* **2020**, *21*, e240–e251. [[CrossRef](#)] [[PubMed](#)]
12. Lopes, R.; Betrouni, N. Fractal and multifractal analysis: A review. *Med. Image Anal.* **2009**, *13*, 634–649. [[CrossRef](#)] [[PubMed](#)]
13. Bisoi, A.K.; Mishra, J. On calculation of fractal dimension of images. *Pattern Recognit. Lett.* **2001**, *22*, 631–637. [[CrossRef](#)]
14. Salwaji, S.; Pasupuleti, M.K.; Manyam, R.; Pasupuleti, S.; Alapati, N.S.; Birajdar, S.S.; Mounika, R. Nuclear Fractal Dimension in Diagnosing Oral Cancer—A Systematic Review. *Uttar Pradesh J. Zool.* **2023**, *44*, 47–55. [[CrossRef](#)]
15. Panigrahi, S.; Rahmen, J.; Panda, S.; Swarnkar, T. Fractal Geometry for Early Detection and Histopathological Analysis of Oral Cancer. In Proceedings of the 7th International Conference, MIKE 2019, Goa, India, 19–22 December 2020; Volume 11987, pp. 177–185.
16. Sahoo, G.R.; Bharti, D.; Pradhan, A. Multifractal Analysis of Low Coherence Spectra for Oral Cancer Detection. In Proceedings of the SPIE BiOS, San Francisco, CA, USA, 1–6 February 2020; Volume 11253.
17. Delides, A.; Panayiotides, I.; Alegakis, A.; Kyroudi, A.; Banis, C.; Pavlaki, A.; Helidonis, E.; Kittas, C. Fractal Dimension as a Prognostic Factor for Laryngeal Carcinoma. *Anticancer Res.* **2005**, *25*, 2141–2144.
18. Page, M.J.; McKenzie, J.E.; Bossuyt, P.M.; Boutron, I.; Hoffmann, T.C.; Mulrow, C.D.; Shamseer, L.; Tetzlaff, J.M.; Akl, E.A.; Brennan, S.E.; et al. The PRISMA 2020 Statement: An Updated Guideline for Reporting Systematic Reviews. *BMJ* **2021**, *372*, n71. [[CrossRef](#)]
19. Saaq, M.; Ashraf, B. Modifying “Pico” Question into “Picos” Model for More Robust and Reproducible Presentation of the Methodology Employed in A Scientific Study. *World J. Plast. Surg.* **2017**, *6*, 390–392.
20. Krishnan, M.M.R.; Shah, P.; Chakraborty, C.; Ray, A.K. Statistical Analysis of Textural Features for Improved Classification of Oral Histopathological Images. *J. Med. Syst.* **2012**, *36*, 865–881. [[CrossRef](#)] [[PubMed](#)]
21. Raja, J.V.; Khan, M.; Ramachandra, V.K.; Al-Kadi, O. Texture Analysis of CT Images in the Characterization of Oral Cancers Involving Buccal Mucosa. *Dentomaxillofac. Radiol.* **2012**, *41*, 475–480. [[CrossRef](#)]
22. Pandey, P.; Kandakurti, S.; Saxena, V.; Tripathi, P.; Pamula, R.; Yadav, M. Fractal Analysis in Oral Leukoplakia. *J. Indian Acad. Oral Med. Radiol.* **2015**, *27*, 354–358. [[CrossRef](#)]
23. Yinti, S.R.; Srikant, N.; Boaz, K.; Lewis, A.J.; Ashokkumar, P.J.; Kapila, S.N. Nuclear Fractal Dimensions as a Tool for Prognostication of Oral Squamous Cell Carcinoma. *J. Clin. Diagn. Res.* **2015**, *9*, EC21–EC25. [[CrossRef](#)] [[PubMed](#)]
24. Phulari, R.; Rathore, R.; Talegaon, T. Nuclear Fractal Dimension: A New Objective Approach for Discriminating Normal Mucosa, Dysplasia and Carcinoma. *J. Oral Maxillofac. Pathol.* **2016**, *20*, 400–404. [[CrossRef](#)]
25. Das, D.K.; Mitra, P.; Chakraborty, C.; Chatterjee, S.; Maiti, A.K.; Bose, S. Computational Approach for Mitotic Cell Detection and Its Application in Oral Squamous Cell Carcinoma. *Multidimens. Syst. Signal Process.* **2017**, *28*, 1031–1050. [[CrossRef](#)]
26. Iqbal, J.; Patil, R.; Khanna, V.; Tripathi, A.; Singh, V.; Munshi, M.A.I.; Tiwari, R. Role of Fractal Analysis in Detection of Dysplasia in Potentially Malignant Disorders. *J. Fam. Med. Prim. Care* **2020**, *9*, 2448–2453. [[CrossRef](#)]
27. Nawn, D.; Pratiher, S.; Chatteraj, S.; Chakraborty, D.; Pal, M.; Paul, R.R.; Dutta, S.; Chatterjee, J. Multifractal Alterations in Oral Sub-Epithelial Connective Tissue during Progression of Pre-Cancer and Cancer. *IEEE J. Biomed. Health Inform.* **2021**, *25*, 152–162. [[CrossRef](#)]
28. Sharma, N.; Nawn, D.; Pratiher, S.; Shome, S.; Chatterjee, R.; Biswas, K.; Pal, M.; Paul, R.R.; Dutta, S.; Chatterjee, J. Multifractal Texture Analysis of Salivary Fern Pattern for Oral Pre-Cancers and Cancer Assessment. *IEEE Sens. J.* **2021**, *21*, 9333–9340. [[CrossRef](#)]
29. Santolia, D.; Dahiya, S.; Sharma, S.; Khan, M.A.; Mohammed, N.; Priya, H.; Gupta, S.R.; Bhargava, S.; Gupta, D.S.R. Fractal Dimension and Radiomorphometric Analysis of Orthopantomographic Radiographs in Patients with Tobacco and Areca Nut Associated Oral Mucosal Lesions: A Pilot in-Vivo Study in a North Indian Cohort. *Oral Surg. Oral Med. Oral Pathol. Oral Radiol.* **2022**, *134*, 627–638. [[CrossRef](#)]
30. Krishnan, M.M.R.; Shah, P.; Choudhary, A.; Chakraborty, C.; Paul, R.R.; Ray, A.K. Textural Characterization of Histopathological Images for Oral Sub-Mucous Fibrosis Detection. *Tissue Cell* **2011**, *43*, 318–330. [[CrossRef](#)]
31. Rahman, J.; Panda, S.; Panigrahi, S.; Mohanty, N.; Swarnkar, T.; Mishra, U. Perspective of Nuclear Fractal Dimension in Diagnosis and Prognosis of Oral Squamous Cell Carcinoma. *J. Oral Maxillofac. Pathol.* **2022**, *26*, 127. [[CrossRef](#)]
32. Goutzanis, L.; Papadogeorgakis, N.; Pavlopoulos, P.M.; Katti, K.; Petsinis, V.; Plochoras, I.; Pantelidaki, C.; Kavantzias, N.; Patsouris, E.; Alexandridis, C. Nuclear Fractal Dimension as a Prognostic Factor in Oral Squamous Cell Carcinoma. *Oral Oncol.* **2008**, *44*, 345–353. [[CrossRef](#)]
33. Goutzanis, L.P.; Papadogeorgakis, N.; Pavlopoulos, P.M.; Petsinis, V.; Plochoras, I.; Eleftheriadis, E.; Pantelidaki, A.; Patsouris, E.; Alexandridis, C. Vascular Fractal Dimension and Total Vascular Area in the Study of Oral Cancer. *Head Neck* **2009**, *31*, 298–307. [[CrossRef](#)] [[PubMed](#)]
34. Spyridonos, P.; Gaitanis, G.; Tzaphlidou, M.; Bassukas, I.D. Spatial Fuzzy C-Means Algorithm with Adaptive Fuzzy Exponent Selection for Robust Vermilion Border Detection in Healthy and Diseased Lower Lips. *Comput. Methods Programs Biomed.* **2014**, *114*, 291–301. [[CrossRef](#)]
35. Spyridonos, P.; Gaitanis, G.; Bassukas, I.D.; Tzaphlidou, M. Evaluation of Vermilion Border Descriptors and Relevance Vector Machines Discrimination Model for Making Probabilistic Predictions of Solar Cheilosis on Digital Lip Photographs. *Comput. Biol. Med.* **2015**, *63*, 11–18. [[CrossRef](#)] [[PubMed](#)]

36. Lucchese, A.; Gentile, E.; Capone, G.; De Vico, G.; Serpico, R.; Landini, G. Fractal analysis of mucosal microvascular patterns in oral lichen planus: A preliminary study. *Oral Surg. Oral Med. Oral Pathol. Oral Radiol.* **2015**, *120*, 609–615. [[CrossRef](#)] [[PubMed](#)]
37. Mincione, G.; Di Nicola, M.; Di Marcantonio, M.C.; Muraro, R.; Piattelli, A.; Rubini, C.; Penitente, E.; Piccirilli, M.; Aprile, G.; Perrotti, V.; et al. Nuclear fractal dimension in oral squamous cell carcinoma: A novel method for the evaluation of grading, staging, and survival. *J. Oral Pathol. Med.* **2015**, *44*, 680–684. [[CrossRef](#)]
38. D'Addazio, G.; Artese, L.; Traini, T.; Rubini, C.; Caputi, S.; Sinjari, B. Immunohistochemical study of osteopontin in oral squamous cell carcinoma allied to fractal dimension. *J. Biol. Regul. Homeost. Agents* **2018**, *32*, 1033–1038.
39. Landini, G.; Rippin, J.W. An “asymptotic fractal” approach to the morphology of malignant cell nuclei. *Fractals* **1993**, *1*, 326–335. [[CrossRef](#)]
40. Margaritescu, C.; Raica, M.; Pirici, D.; Simionescu, C.; Mogoanta, L.; Stinga, A.C.; Stinga, A.S.; Ribatti, D. Podoplanin Expression in Tumor-Free Resection Margins of Oral Squamous Cell Carcinomas: An Immunohistochemical and Fractal Analysis Study. *Histol. Histopathol.* **2010**, *25*, 701–711.
41. Klatt, J.; Gerich, C.E.; Gröbe, A.; Opitz, J.; Schreiber, J.; Hanken, H.; Salomon, G.; Heiland, M.; Kluwe, L.; Blessmann, M. Fractal Dimension of Time-Resolved Autofluorescence Discriminates Tumour from Healthy Tissues in the Oral Cavity. *J. Cranio-Maxillo-Facial Surg. Off. Publ. Eur. Assoc. Cranio-Maxillo-Facial Surg.* **2014**, *42*, 852–854. [[CrossRef](#)]
42. Bose, P.; Brockton, N.T.; Guggisberg, K.; Nakoneshny, S.C.; Kornaga, E.; Klimowicz, A.C.; Tambasco, M.; Dort, J.C. Fractal Analysis of Nuclear Histology Integrates Tumor and Stromal Features into a Single Prognostic Factor of the Oral Cancer Microenvironment. *BMC Cancer* **2015**, *15*, 409. [[CrossRef](#)]
43. Ou-Yang, M.; Hsieh, Y.-F.; Lee, C.-C. Biopsy Diagnosis of Oral Carcinoma by the Combination of Morphological and Spectral Methods Based on Embedded Relay Lens Microscopic Hyperspectral Imaging System. *J. Med. Biol. Eng.* **2015**, *35*, 437–447. [[CrossRef](#)] [[PubMed](#)]
44. Yang, X.; Xiao, X.; Wu, W.; Shen, X.; Zhou, Z.; Liu, W.; Shi, L. Cytological Study of DNA Content and Nuclear Morphometric Analysis for Aid in the Diagnosis of High-Grade Dysplasia within Oral Leukoplakia. *Oral Surg. Oral Med. Oral Pathol. Oral Radiol.* **2017**, *124*, 280–285. [[CrossRef](#)]
45. Jurczyszyn, K.; Kazubowska, K.; Kubasiewicz-Ross, P.; Ziólkowski, P.; Dominiak, M. Application of fractal dimension analysis and photodynamic diagnosis in the case of differentiation between lichen planus and leukoplakia: A preliminary study. *Adv. Clin. Exp. Med.* **2018**, *27*, 1729–1736. [[CrossRef](#)] [[PubMed](#)]
46. Guerrero-Sánchez, Y.; Gómez García, F.; Chamorro-Petronacci, C.M.; Suárez-Peñaranda, J.M.; Pérez-Sayáns, M. Use of the Fractal Dimension to Differentiate Epithelium and Connective Tissue in Oral Leukoplakias. *Cancers* **2022**, *14*, 2697. [[CrossRef](#)] [[PubMed](#)]
47. Singh, G.; Preethi, B.; Chaitanya, K.K.; Navyasree, M.; Kumar, T.G.; Kaushik, M.S. Prevalence of Oral Mucosal Lesions among Tobacco Consumers: Cross-Sectional Study. *J. Pharm. Bioallied. Sci.* **2023**, *15*, S562–S565. [[CrossRef](#)]
48. Seventy-First World Health Assembly mHealth. Use of Appropriate Digital Technologies for Public Health. Available online: https://apps.who.int/gb/ebwha/pdf_files/WHA71/A71_R7-en.pdf (accessed on 21 November 2023).
49. Contaldo, M.; Lauritano, D.; Carinci, F.; Romano, A.; Di Stasio, D.; Lajolo, C.; Della Vella, F.; Serpico, R.; Lucchese, A. Intraoral confocal microscopy of suspicious oral lesions: A prospective case series. *Int. J. Dermatol.* **2020**, *59*, 82–90. [[CrossRef](#)]
50. Contaldo, M.; Di Stasio, D.; Petrucci, M.; Serpico, R.; Lucchese, A. In vivo reflectance confocal microscopy of oral lichen planus. *Int. J. Dermatol.* **2019**, *58*, 940–945. [[CrossRef](#)]
51. Jurczyszyn, K.; Kozakiewicz, M. Application of Texture and Fractal Dimension Analysis to Estimate Effectiveness of Oral Leukoplakia Treatment Using an Er:YAG Laser—A Prospective Study. *Materials* **2020**, *13*, 3614. [[CrossRef](#)]
52. Jurczyszyn, K.; Trzeciakowski, W.; Kozakiewicz, M.; Kida, D.; Malec, K.; Karolewicz, B.; Konopka, T.; Zborowski, J. Fractal Dimension and Texture Analysis of Lesion Autofluorescence in the Evaluation of Oral Lichen Planus Treatment Effectiveness. *Materials* **2021**, *14*, 5448. [[CrossRef](#)]
53. Varsha, K.S.; Krithika, C.L.; Ganesan, A.; Chandravani, A.; Jothi, A. Pre and post treatment objective evaluation of remission in oral lichen planus using fractal analysis and comparison with visual analog (vas) and thongprasom scale—a cohort study. *Int. J. Chem. Biochem. Sci.* **2023**, *23*, 177–184.
54. Chan, A.; Tuszynski, J.A. Automatic prediction of tumour malignancy in breast cancer with fractal dimension. *R. Soc. Open Sci.* **2016**, *3*, 160558. [[CrossRef](#)] [[PubMed](#)]
55. Chang, A.; Prabhala, S.; Daneshkhah, A.; Lin, J.; Subramanian, H.; Roy, H.K.; Backman, V. Early screening of colorectal cancer using feature engineering with artificial intelligence-enhanced analysis of nanoscale chromatin modifications. *Res. Sq.* **2023**, 1–25. [[CrossRef](#)]

Disclaimer/Publisher’s Note: The statements, opinions and data contained in all publications are solely those of the individual author(s) and contributor(s) and not of MDPI and/or the editor(s). MDPI and/or the editor(s) disclaim responsibility for any injury to people or property resulting from any ideas, methods, instructions or products referred to in the content.