

Myocardial deformation imaging and rare cardiomyopathies with hypertrophic phenotype: a review focused on Fabry disease, Friedreich ataxia and amyloidosis

Bahaa Fadel,¹ Luca Baldini,²
Valeria Pergola,¹ Ziad Al Bulbul,¹
Giovanni Di Salvo¹

¹King Faisal Specialist Hospital and Research Center, Heart Institute, Riyadh, Saudi Arabia; ²Pediatric Cardiology, Second University of Naples, Italy

Abstract

Tissue Doppler and deformation imaging, including Doppler-derived strain and speckle tracking, have significantly improved our understanding of cardiac mechanics in both physiological and pathological states. The various modes of left ventricular deformation (longitudinal, circumferential, radial and twist) leading to systolic contraction can nowadays be quantified. One of the best applications of deformation imaging is in the area of hypertrophic cardiomyopathies. Deformation imaging allows the evaluation of global and regional myocardial performance and the noninvasive characterization of abnormal intramural myocardial mechanics. In this review, we discuss the role of myocardial deformation imaging derived by echocardiography in the assessment of rare hypertrophic phenotype including Fabry disease, Friedreich ataxia and amyloidosis. Deformation imaging allows for early identification of myocardial dysfunction in many hypertrophic disorders, at an earlier stage than that provided by standard imaging or echocardiographic techniques. This allows for the implementation of appropriate therapy before significant disease progression has occurred and prior to the development of advanced myocardial fibrosis. Thus therapy would likely be more effective and may potentially lead to improvement in patient outcome. Additionally strain imaging allows to better monitoring the efficacy of therapy by assessing the progression and regression of myocardial involvement. Finally, findings on strain imaging carry important prognostic information in many hypertrophic disorders.

Introduction

Tissue Doppler and deformation imaging, including Doppler-derived strain and speckle

tracking, have significantly improved our understanding of cardiac mechanics in both physiological and pathological states.¹⁻³ The various modes of left ventricular (LV) deformation (longitudinal, circumferential, radial and twist) leading to systolic contraction can nowadays be quantified.^{1,3}

One of the best applications of deformation imaging is in the area of hypertrophic cardiomyopathies.^{4,6} Deformation imaging allows the evaluation of global and regional myocardial performance and the noninvasive characterization of abnormal intramural myocardial mechanics. It provides greater sensitivity than volume-derived parameters such as ejection fraction for the detection of subtle and pre-clinical myocardial dysfunction, risk stratification, monitoring of therapy, and discrimination between the various forms of hypertrophic phenotype.^{4,6} In this review, we discuss the role of myocardial deformation imaging derived by echocardiography in the assessment of rare hypertrophic phenotype including Fabry disease, Friedreich ataxia and amyloidosis.

Strain and strain rate imaging

Several comprehensive reviews have been published regarding the technical aspects and clinical applications of strain imaging.¹⁻³ Briefly, the difference between myocardial motion assessed by tissue velocities and myocardial deformation assessed by strain and strain rate may be explained by this example: a moving object will change its position (motion) over time but will not deform if all of its parts move at the same velocity. If the various parts of the object move at different velocities than the object will deform.^{1,3} Myocardial velocities and their time integral, displacement, measure object motion and thus cannot differentiate between active and passive movement of a myocardial segment.^{1,3} Conversely deformation parameters (strain and strain-rate) can distinguish active from passive myocardial tissue movement.^{1,3} For a one-dimensional object (*i.e.*, a thin bar), the only possible deformation is either lengthening or shortening and the linear strain (amount of deformation) is defined by the change in length divided by the original length.^{1,3} Since the heart is a three-dimensional structure, myocardial deformation along the three axes is more complex resulting in three normal strains (longitudinal, radial and circumferential) and six shear strains.^{1,3} Strain, *i.e.*, the amount of deformation, is a time independent parameter and is expressed in percent (%). Strain rate (SR) is the rate at which the deformation occurs and is expressed in 1/s. These two parameters are not interchangeable.^{1,3} In fact, two objects may have the same total deformation

Correspondence: Giovanni Di Salvo, Heart Centre (Dpt) – F, P.O. Box 3354 Riyadh 11211 MBC - 16, Saudi Arabia.
Tel. 014647272 - Ext: 347842 - Mobile: 0564997266.
E-mail: giodisal@yahoo.it

Key words: speckle tracking echocardiography, Fabry disease, Friedreich ataxia, amyloidosis.

Received for publication: 6 July 2012.

Revision received: 24 September 2012.

Accepted for publication: 29 September 2012.

This work is licensed under a Creative Commons Attribution NonCommercial 3.0 License (CC BY-NC 3.0).

©Copyright B. Fadel *et al.*, 2013
Licensee PAGEPress, Italy
Cardiogenetics 2013; 3:e4
doi:10.4081/cardiogenetics.2013.e4

attained at different times, and thus have different SR at a constant strain. A positive strain describes thickening or lengthening whereas a negative strain describes thinning or shortening of a myocardial segment compared to its original length. Initially, strain and SR were derived from tissue Doppler imaging (TDI). This approach has several drawbacks:^{1,3} i) ability to measure only one-dimensional strain and SR; ii) time-consuming data acquisition and post-processing; iii) necessity for expert readers; iv) low signal to noise ratio; v) inability to interrogate the tip of the LV apex; vi) requirement for good alignment between the ultrasound beam and myocardial motion (angle of interrogation <15°). For all these reasons TDI-derived strain and SR measurements are not highly reproducible with up to 15% variability.^{1,3} However in experienced and trained hands this method can be a very sensitive tool to assess early and focal myocardial contractile abnormalities.² Moreover, this technique is the only one able to fully resolve SR because of its high frame rate.²

A more recent echocardiographic approach to myocardial deformation analysis is speckle tracking. This technique is a post-processing algorithm that uses the routine bi-dimensional gray scale digital images.^{1,3} Even though several software programs are commercially available, the basic algorithm is common.^{1,3} The motion pattern of myocardial tissue is reflected by the motion pattern of acoustic markers or speckles. These are statistically equally distributed throughout the myocardium. Within the ultrasonic image speckles are automatically tracked frame to frame by a dedicated software.^{1,3} The geometric shift of each speckle represents local tissue movement and, knowing the frame rate, one can calculate their velocity.^{1,3} Strain and SR are then derived from

the velocity. Since strain information is not dependent on the Doppler angle of interrogation, which is the case with TDI-derived strain, more strain analyses are thus possible, including longitudinal, circumferential, radial, and rotational.¹⁻³ At present, the optimal frame rate for speckle tracking seems to be 50-90 frames per second (fps), substantially lower than the frame rate achieved by TDI (>200 fps).¹⁻³ This lower frame rate could, however, result in under-sampling of short-lived events, thus preventing optimal assessment of SR, isovolumic relaxation and isovolumic contraction.¹⁻³ It is also important to realize that various tracking algorithms manufactured by different vendors may produce different results.⁷ Still strain derived from speckle tracking has a better reproducibility than TDI-derived strain and its automated measurement is less time consuming, allowing for easier use in clinical practice.³

Fabry disease

Fabry disease (FD) is a rare X-linked lysosomal storage disorder caused by deficiency in the α -galactosidase A enzyme.⁸⁻⁹ It results in progressive intracellular accumulation of glycosphingolipid globotriaosylceramide in various tissues including the heart, vascular endothelium, skin, kidneys and peripheral nervous system. Substrate accumulation in cardiomyocytes leads to progressive left ventricular hypertrophy (LVH), usually symmetrical and concentric.⁸⁻⁹ The increase in wall thick-

ness may mimic the non-obstructive form of hypertrophic cardiomyopathy (HCM). In one study 3% of male subjects with LVH were found to have α -galactosidase A deficiency.¹⁰ In another study, 4% of patients referred to a tertiary center for evaluation of suspected HCM were found to have FD.¹¹ Histologically myeloid figures are noted on electron microscopy in the majority of cardiomyocytes, a characteristic finding of Fabry cardiomyopathy (FC).^{8,9}

Cardiac symptoms are the presenting manifestations of the disease in approximately 50% of affected individuals. Isolated cardiac involvement can also develop without clinical evidence of other organ involvement. Furthermore cardiac involvement is the most common cause of death in Fabry patients.^{8,9}

Standard echocardiography does not allow distinguishing FC from other causes of LVH. The *binary appearance* of the LV endocardial border is not a sensitive or specific marker of the disease.¹²⁻¹⁴ Among patients with severe asymmetrical basal septal hypertrophy and outflow obstruction suggestive of obstructive HCM, FD is unlikely.¹⁵ Similar to other forms of LVH, diastolic dysfunction is often present at an early stage of the disease with impairment of left ventricular relaxation properties.^{8,14} Left ventricular ejection fraction (LVEF) is often normal and does not decline until the late stages of the disease due to progressive myocardial fibrosis.^{8,14}

Newer echocardiographic modalities allow detection of abnormalities in myocardial function in the pre-clinical stage and prior to the development of morphological abnormalities on standard echocardiography (Table 1).¹⁴

Tissue Doppler and deformation imaging demonstrate impairment in longitudinal systolic function (reduced S', E' and strain rate) in the presence of normal LVEF^{16,17} and prior to the development of hypertrophy.¹⁸ Hypertrophy is as well associated with reduction in radial contractile parameters with an inverse correlation between wall thickness and radial strain rate values (lower strain rate in segments showing the worst hypertrophy).¹⁹

Even though myocardial involvement is often global with a concentric pattern to the hypertrophy, there is regional preponderance to the development of myocardial fibrosis. Cardiovascular magnetic resonance (CMR) data demonstrate that the initial fibrotic changes develop in the middle layer of the basal inferolateral segment with focal reduction of peak longitudinal strain in this area on deformation imaging.²⁰⁻²³ A characteristic pattern is noted on strain rate imaging consisting of an early systolic peak followed by a rapid fall and a second peak during the isovolumic relaxation phase indicative of post-systolic shortening.²⁰⁻²³ Whereas this *double peak sign* (Figure 1) is first noted in the basal inferolateral segment, it could as well be identified in other myocardial segments of FC where no fibrosis is initially detected by late enhancement on CMR.²⁰⁻²³ These segments ultimately demonstrate late enhancement indicative of fibrosis on follow-up CMR. This indicates that strain imaging is a more sensitive method than CMR for the detection of early myocardial fibrosis.²⁰⁻²³

The availability of enzyme replacement therapy (ERT) has allowed for temporal assessment of the morphological and function-

Table 1. Main features concerning standard and new echocardiographic findings in Fabry disease, Friedreich ataxia and amyloidosis.

	Fabry disease	Friedreich ataxia	Amyloidosis
Standard echocardiography	<i>Binary</i> appearance of the LV endocardial border Diastolic dysfunction often present LV ejection fraction is often normal Myocardial involvement is often global with concentric pattern Regression of hypertrophy following enzyme replacement therapy	LV localization without right ventricular involvement Variable degree and nature of LV hypertrophy LV ejection fraction is often normal or supranormal Regression of hypertrophy following therapy with idebenone	Progressive increase in biventricular wall thickness with small or normal LV chamber size Dilated atria, thickened interatrial septum, pericardial effusion Speckled or granular appearance of the myocardium Diastolic dysfunction often present
New echocardiographic technologies	Impairment in longitudinal systolic function (S', E', strain rate) <i>Double peak sign</i> Earlier improvement of strain rate values following enzyme replacement therapy	Reduced diastolic and systolic TDI velocities Uniform reduction in regional systolic and diastolic deformations even in absence of hypertrophy The reduction of myocardial deformations parameters is correlated with end-diastolic wall thickness Earlier improvement of strain rate values during treatment with idebenone	Early and marked impairment of longitudinal function Radial and circumferential strain is often normal Gradual increase in strain values from base to apex Early impairment of left atrial strain values Prognostic value of peak longitudinal systolic strain in basal anteroseptum $\leq 7.5\%$

LV, left ventricular; TDI, tissue Doppler imaging.

al changes in FC patients in response to treatment. Following ERT, regression of LVH is typically noted with improvement of LV systolic parameters including strain and strain rate values.^{23,24} However segments showing even mild degree of myocardial fibrosis on late enhancement CMR show no functional improvement following ERT as evidenced by lack of improvement in strain rate.^{23,24} This emphasizes the need for early detection of FC

and the initiation of ERT prior to the development of any myocardial fibrosis. When combined with standard echocardiographic techniques, newer imaging modalities including tissue Doppler, strain imaging and CMR provide incremental diagnostic value, allow for earlier detection of myocardial involvement and monitoring of the response to ERT. It is essential that FD patients are not misdiagnosed as HCM. Not only effective replacement

therapy that results in LVH regression is not instituted, such patients could be needlessly subjected to invasive management strategies such as catheter-based septal ablation or surgical myectomy.

Friedreich ataxia

Friedreich ataxia (FA) is an autosomal recessive neurodegenerative disorder with a prevalence of 1/50,000 in the general population.²⁵⁻²⁷ It is caused by mutations in the FA gene located on chromosome 9q13.²⁵⁻²⁷ A homozygous GAA triplet expansion in the first intron leads to reduction in gene transcription and thus a decrease in the synthesis of the gene product *frataxin*, a mitochondrial membrane protein.²⁵⁻²⁷ Its deficiency leads to mitochondrial iron accumulation causing oxidative stress and secondary deficiency in respiratory chain enzymes.²⁷ At the cellular level, myocytes hypertrophy, interstitial fibrosis, and focal myocardial necrosis ensue.²⁷ Morphologically, FA is frequently associated with a progressive hypertrophic cardiomyopathy of the LV without right ventricular involvement morphological leading to cardiac dysfunction and premature death.²⁵⁻²⁸ The degree and nature of LV hypertrophy (concentric, asymmetrical, or both) are highly variable.

The most common echocardiographic abnormality is an asymmetric LV hypertrophy with thickening of the papillary muscles, although the range of morphological abnormalities appears to be wide.^{26,28,29} Volume-based global systolic parameters such as ejec-

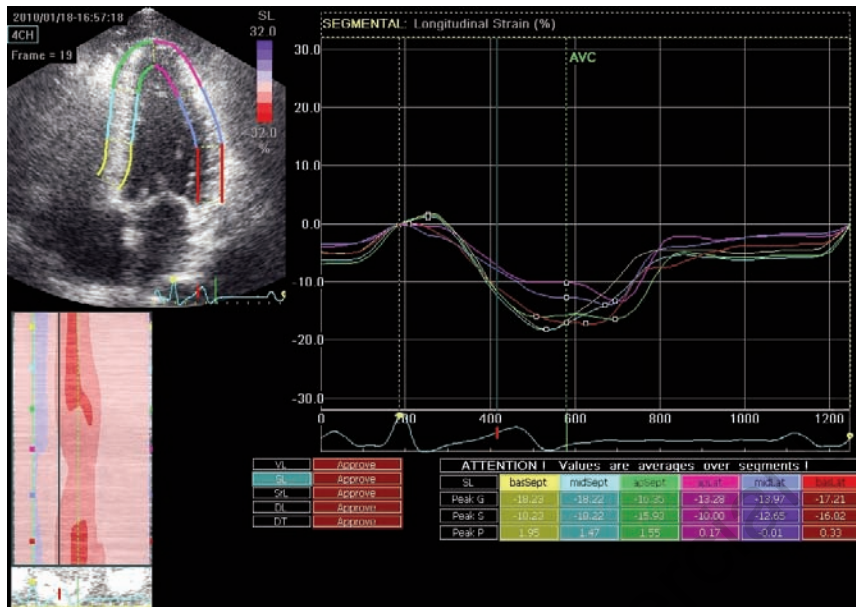


Figure 1. A case of Fabry disease showing uniformly reduced values of 2D longitudinal peak systolic strain; interestingly the segments of the lateral wall show the double peak sign.

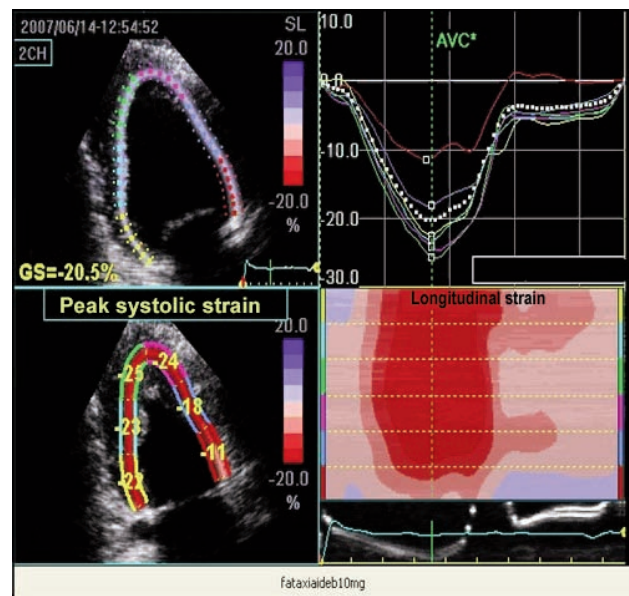
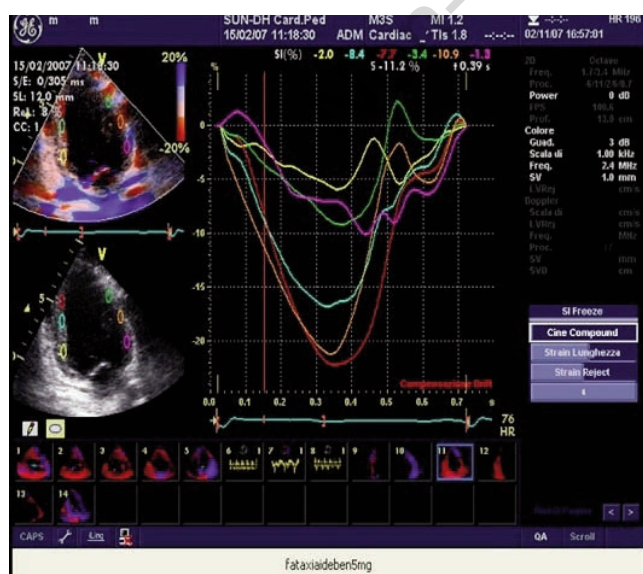


Figure 2. A and B) A case of Friedreich ataxia: of interest strain rate imaging is able to detect linear improvements in longitudinal myocardial deformation when higher dosage of idebenone were used.

tion fraction are either normal or supranormal.^{26,28,29} Nevertheless, the most common cause of death in FA patients is heart failure.^{25,26} This suggests that our traditional parameters to assess LV systolic function are not sensitive enough to follow FA patients.

The use of the new deformation indices is of great clinical value in FA. Tissue Doppler imaging demonstrates reduction in systolic and diastolic myocardial velocities in the absence of cardiac symptoms.³⁰ Interestingly, an inverse correlation is found between the number of GAA triple repeats and myocardial velocities suggesting a relationship between myocardial involvement and the severity of the genetic defect.³⁰ Strain imaging demonstrates a uniform reduction in regional systolic and diastolic deformation properties even in the absence of LVH.³⁰ This reduction is also noted equally in hypertrophied and non-hypertrophied myocardial segments despite a preserved ejection fraction. The reduction in regional deformation properties in the left ventricle correlated with end-diastolic wall thickness.³⁰ The basal anterior and lateral segments show the lowest deformation values again implying a degree of regionality to the cardiac involvement in systemic illnesses. As described with Fabry disease, regional alterations in myocardial function appear to precede the development of morphological changes in LV geometry. The absence of right ventricular involvement is probably related to a weaker pressure development and lower myocardial oxygen consumption in the right than the left ventricle, thus preventing the phenotypic expression of the genotypic disorder.³⁰

Idebenone, a quinone analogue with free-radical scavenger properties, has been proposed as a therapeutic agent for FA patients.³¹⁻³³ Its anti-oxidant action might be related to preservation or improvement of mitochondrial func-

tion.³¹ Its use is associated with a late regression in LV mass in approximately 50% of patients.³¹⁻³³ Using Doppler-derived strain and strain rate imaging, treatment with idebenone resulted in an early (4 months) and linear improvement in regional myocardial function (Figure 2) that preceded a non-linear regression of LVH that was detected after 1 year of therapy.³⁴ Interestingly, regional myocardial velocities did not improve during idebenone administration suggesting that they have no role in the monitoring of therapy.³⁴

Amyloidosis

Cardiac involvement may occur with all forms of systemic amyloidosis due to the extracellular deposition of abnormal insoluble fibrillar proteins.^{35,36} These include: i) primary (AL) amyloidosis, the most common cause of cardiac amyloidosis (CA), is associated with a light chain monoclonal gammopathy due to a blood cell dyscrasia with deposition of light chain immunoglobulin in various organs including the heart. Clinical evidence of cardiac involvement occurs in up to 50% of patients; ii) secondary amyloidosis associated with chronic infection and inflammation is becoming increasingly uncommon; iii) hereditary or familial amyloidosis, an autosomal dominant disease, results from deposition of a mutant transthyretin protein; iv) senile systemic amyloidosis results from deposition of wild-type transthyretin. Both transthyretin-related amyloidosis have a better prognosis than AL amyloidosis.³⁵⁻³⁷

Amyloid deposition occurs uniformly throughout the heart involving the myocardium, endocardium, pericardium, interatrial septum, conduction system, valves and coronary arteries. Oxidative stress with cellular

necrosis and interstitial fibrosis is probably due to a combination of *chronic* interstitial infiltration and acute toxic effect of circulating light chains.^{14,37} Morphologically, progressive increase in biventricular wall thickness (rather than true hypertrophy) ensues with small or normal LV chamber size, dilated atria, often thickened interatrial septum and a pericardial effusion.¹⁴ The previously described speckled or granular appearance of the myocardium is not specific for CA.^{14,37}

The availability of some therapies for CA particularly for the early stages of the disease coupled with the very poor prognosis, particularly with AL amyloidosis, emphasizes the need for an early diagnosis of cardiac involvement.³⁸ Unfortunately, standard echocardiographic and Doppler techniques, including tissue Doppler analysis, do not allow the detection of CA at an early stage when therapy can be most effective.³⁹ Abnormalities on 2D imaging may not develop until after the onset of heart failure symptoms.^{14,37-39} Therefore it is desirable to use more sensitive measures to detect LV early dysfunction.

Diastolic dysfunction occurs relatively early in the disease process with an impaired relaxation pattern on spectral and TDI with progression towards a restrictive pattern on spectral Doppler with further disease progression. However impaired relaxation is not a specific finding, occurring with aging and in numerous pathological states.^{14,37-39}

The subendocardial layer where longitudinally oriented fibers are predominantly located is primarily involved with the amyloid process leading to early and marked impairment of longitudinal function. This can be detected by M-mode, pulsed TDI and strain imaging demonstrating significant reduction in displacement, velocity and deformation values along the longitudinal plane.⁴⁰ Of these strain imaging is the most sensitive measure, providing the earliest clues to the presence of myocardial involvement even prior to reduction in tissue velocity parameters.⁴¹ Reduction in longitudinal strain and strain rate in all 16 LV segments can be detected in patients with AL amyloidosis without any other echocardiographic 2D or Doppler evidence of cardiac involvement and without any reduction in radial or circumferential strain.⁴⁰ This finding indicates that assessment of longitudinal function by strain imaging provides the earliest clues to the presence of myocardial dysfunction in patients with systemic amyloidosis (Figure 3). Despite the impairment in longitudinal function, left ventricular ejection fraction remains normal due to preservation or even compensatory increase in radial and circumferential function in order to maintain cardiac output.^{40,42} Not until late in the disease process that EF declines, being inversely proportional to the severity of wall thickness.^{40,42} However, the role

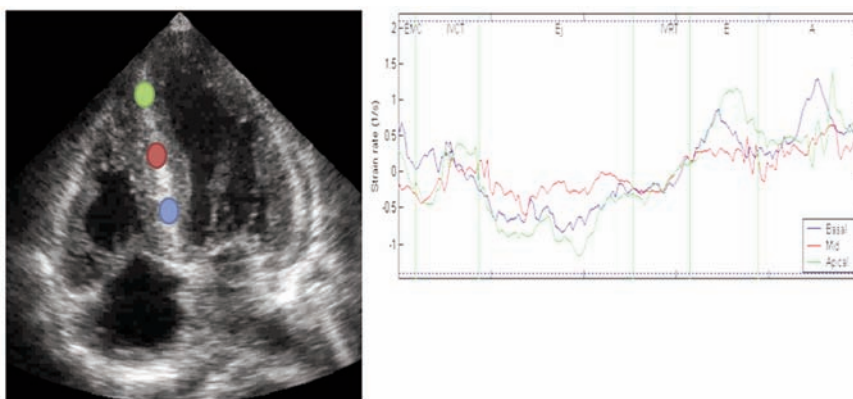


Figure 3. A case of amyloidosis showing reduced myocardial peak systolic strain rate in basal and mid segments, with a relatively preserved deformation at the apex.

of speckle tracking imaging in the early phases of cardiac amyloid infiltration and in assessing the natural history of the disease has yet to be determined.

Findings on strain imaging may also allow discriminate some forms of CA, distinguish CA from other causes of LVH and carry important prognostic implications.⁴³ For example, standard echocardiographic parameters and myocardial velocities cannot distinguish familial amyloid polyneuropathy (FAP) from AL amyloidosis.⁴³ Telling apart these forms of amyloidosis is relevant since patients with FAP have less heart failure symptoms and better prognosis with much lower cardiac mortality. Despite similar degrees of LV wall thickness, longitudinal strain is significantly lower in the basal and mid segments in patients with AL amyloidosis in spite of a preserved global systolic function.⁴³ Additionally despite similarities on 2D echocardiographic findings between CA and HCM, strain imaging allows to distinguish these 2 forms of hypertrophic phenotypes. As described above, each shows a characteristic pattern for longitudinal deformation. Whereas radial strain may be reduced in both groups of myopathies, patients with CA show a gradual increase in strain values from base to apex. In contrast, HCM patients demonstrate preservation of the physiological base to apex decrease in gradient.^{44,45}

Different patterns of LV torsion are noted in AL patients with and without evidence of cardiac involvement. Twisting and untwisting of the LV are reduced in the first group patients and are increased in the second group. This finding suggests that impairment in LV longitudinal function induces a compensatory mechanism in the early phase of the disease that fails as myocardial involvement worsens.^{46,47}

Since the atria are equally involved in CA, abnormal deformation properties are noted early in the disease process.⁴⁷ Left atrial (LA) dysfunction appears to be independent of global LV systolic and diastolic function and degree of atrial dilatation. Similar to the findings in the LV, peak systolic atrial SR was reduced in AL patients and no apparent cardiac involvement as compared to healthy subjects.⁴⁷ This further suggests the higher sensitivity of deformation imaging for the detection of myocardial involvement in the pre-clinical stage and in the setting of otherwise normal echocardiogram. Furthermore, strain imaging shows worse LA deformation properties in AL patients demonstrating heart failure than in those without suggestive of a more advanced degree of amyloid myocardial infiltration.⁴⁷

Strain imaging provides incremental prognostic information beyond those provided by clinical and standard echocardiographic assessment in patients with CA. In patients with AL amyloidosis, the mean basal strain, a

measure of longitudinal LV function, is a powerful predictor of clinical outcome and superior to standard 2D, spectral Doppler and tissue velocity parameters.⁴¹ The combination of parameters including peak longitudinal systolic strain in the basal anteroseptum ($\leq 7.5\%$), an elevated titer of brain natriuretic peptide (>493 pg/mL) and a shortened LV ejection time (<273 ms) demonstrated the independent predictor value of clinical outcome, in 249 patients with AL amyloidosis.⁴¹

Conclusions

Hypertrophic phenotype represents a widely heterogeneous group of disorders with different etiologies, manifestations, clinical outcomes and therapies. 2D echocardiography coupled with spectral Doppler and tissue velocity imaging is one of the first modalities of diagnosis. Unfortunately, traditional echocardiographic methods often fail to distinguish among these various forms of hypertrophy despite their dissimilarities, whether due to hypertension, HCM, athlete's heart, Fabry disease, Friedreich ataxia or amyloidosis. Needless to say, distinguishing apart these forms of hypertrophic phenotype has major diagnostic, therapeutic and prognostic implications. Strain imaging provides a unique tool for the assessment of such patients as it effectively helps differentiate these different types of hypertrophy. Thus it provides a non-invasive modality to physicians for better allocation of resources and minimizing invasive diagnostic strategies. As repeatedly demonstrated above, deformation imaging allows for early identification of myocardial dysfunction in many hypertrophic disorders, at an earlier stage than that provided by standard imaging or echocardiographic techniques. This allows for the implementation of appropriate therapy before significant disease progression has occurred and prior to the development of advanced myocardial fibrosis. Thus therapy would likely be more effective and may potentially lead to improvement in patient outcome. In addition strain imaging allows to better monitor the efficacy of therapy, especially for Fabry disease and Friedreich ataxia, by assessing the progression and regression of myocardial involvement. Finally, findings on strain imaging carry important prognostic information in many hypertrophic disorders.

One of the best clinical applications of cardiac strain imaging is in the field of hypertrophic phenotype. The data available from several studies are very encouraging as to the value of deformation imaging in this group of patients. In our opinion Strain imaging should be part of the echocardiographic study in patients with evidence of LVH.

It is noteworthy that, dealing with an unexplained left ventricular hypertrophy, standard and new echocardiographic findings must be carefully interpreted in the broader clinical context. Extracardiac manifestations and clinical *red flags* (for example conduction disorders, corneal opacity and proteinuria in Fabry disease, later onset of symptoms, alteration of creatine phosphokinase, aspartate aminotransferase, alanine aminotransferase, lactate dehydrogenase in neuromuscular diseases, low voltage and/or infarct pattern electrocardiogram in amyloidosis) could be of precious help in directing towards the correct differential diagnosis of hypertrophic phenotypes.

References

1. Gorcsan J 3rd, Tanaka H. Echocardiographic assessment of myocardial strain. *J Am Coll Cardiol* 2011;58:1401-13.
2. Sutherland GR, Di Salvo G, Claus P, et al. Strain and strain rate imaging: a new clinical approach to quantifying regional myocardial function. *J Am Soc Echocardiogr* 2004;17:788-802.
3. Mor-Avi V, Lang RM, Badano LP, et al. Current and evolving echocardiographic techniques for the quantitative evaluation of cardiac mechanics: ASE/EAE consensus statement on methodology and indications endorsed by the Japanese Society of Echocardiography. *Eur J Echocardiogr* 2011;12:167-205.
4. Afonso LC, Bernal J, Bax JJ, Abraham TP. Echocardiography in hypertrophic cardiomyopathy: the role of conventional and emerging technologies. *JACC Cardiovasc Imaging* 2008;1:787-800.
5. Cikes M, Sutherland GR, Anderson LJ, Bijnens BH. The role of echocardiographic deformation imaging in hypertrophic myopathies. *Nat Rev Cardiol* 2010;7:384-96.
6. Di Salvo G, Pacileo G, Limongelli G, et al. Non sustained ventricular tachycardia in hypertrophic cardiomyopathy and new ultrasonic derived parameters. *J Am Soc Echocardiogr* 2010;23:581-90.
7. Marwick TH. Consistency of myocardial deformation imaging between vendors. *Eur J Echocardiogr* 2010;11:414-6.
8. Kertész AB, Edes I. Fabry disease cardiomyopathy: from genes to clinical manifestations. *Curr Pharm Biotechnol* 2012; 13:2477-84.
9. Toyooka K. Fabry disease. *Curr Opin Neurol* 2011;24:463-8.
10. Nakao S, Takenaka T, Maeda M, et al. An atypical variant of Fabry's disease in men with left ventricular hypertrophy. *N Engl J Med* 1995;333:288-93.

11. Sachdev B, Takenaka T, Teraguchi H, et al. Prevalence of Anderson-Fabry disease in male patients with late onset hypertrophic cardiomyopathy. *Circulation* 2002;105:1407-11.
12. Pieroni M, Chimenti C, De Cobelli F, et al. Fabry's disease cardiomyopathy: echocardiographic detection of endomyocardial glycosphingolipid compartmentalization. *J Am Coll Cardiol* 2006;47:1663-71.
13. Kounas S, Demetrescu C, Pantazis AA, et al. The binary endocardial appearance is a poor discriminator of Anderson-Fabry disease from familial hypertrophic cardiomyopathy. *J Am Coll Cardiol* 2008;51:2058-61.
14. Losi MA, Nistri S, Galderisi M, et al. Echocardiography in patients with hypertrophic cardiomyopathy: usefulness of old and new techniques in the diagnosis and pathophysiological assessment. *Cardiovasc Ultrasound* 2010;8:7.
15. Ommen SR, Nishimura RA, Edwards WD. Fabry disease: a mimic for obstructive hypertrophic cardiomyopathy? *Heart* 2003;89:929-30.
16. Fiuza M, Avó LB, Oliveira EI, et al. Detection of preclinical left ventricular dysfunction in Fabry disease: the contribution of tissue Doppler. *Rev Port Cardiol* 2006;25:613-37.
17. Toro R, Perez-Isla L, Doxastaquis G, et al. Clinical usefulness of tissue Doppler imaging in predicting preclinical Fabry cardiomyopathy. *Int J Cardiol* 2009;132:38-44.
18. Zamorano J, Serra V, Pérez de Isla L, et al. Usefulness of tissue Doppler on early detection of cardiac disease in Fabry patients and potential role of enzyme replacement therapy (ERT) for avoiding progression of disease. *Eur J Echocardiogr* 2011;12:671-7.
19. Weidemann F, Breunig F, Beer M, et al. The variation of morphological and functional cardiac manifestation in Fabry disease: potential implications for the time course of the disease. *Eur Heart J* 2005;26:1221-7.
20. Weidemann F, Niemann M, Warnock DG, et al. The Fabry cardiomyopathy: models for the cardiologist. *Annu Rev Med* 2011;62:59-67.
21. Weidemann F, Linhart A, Monserrat L, Strotmann J. Cardiac challenges in patients with Fabry disease. *Int J Cardiol* 2010;141:3-10.
22. Weidemann F, Niemann M, Herrmann S, et al. A new echocardiographic approach for the detection of non-ischaemic fibrosis in hypertrophic myocardium. *Eur Heart J* 2007;28:3020-6.
23. Weidemann F, Breunig F, Beer M, et al. Improvement of cardiac function during enzyme replacement therapy in patients with Fabry disease: a prospective strain rate imaging study. *Circulation* 2003;108:1299-301.
24. Weidemann F, Niemann M, Breunig F, et al. Long-term effects of enzyme replacement therapy on Fabry cardiomyopathy: evidence for a better outcome with early treatment. *Circulation* 2009;119:524-9.
25. Rahman F, Pandolfo M. Cardiomyopathy in Friedreich's ataxia. *Acta Neurol Belg* 2011;111:183-7.
26. Bourke T, Keane D. Friedreich's ataxia: a review from a cardiology perspective. *Ir J Med Sci* 2011;180:799-805.
27. Koeppe AH. Friedreich's ataxia: pathology, pathogenesis, and molecular genetics. *J Neurol Sci* 2011;303:1-12.
28. Weidemann F, Rummey C, Bijmens B, et al. Mitochondrial Protection with Idebenone in Cardiac or Neurological Outcome (MICONOS) study group. The heart in Friedreich ataxia: definition of cardiomyopathy, disease severity, and correlation with neurological symptoms. *Circulation* 2012;125:1626-34.
29. Regner SR, Lagedrost SJ, Plappert T, et al. Analysis of echocardiograms in a large heterogeneous cohort of patients with friedreich ataxia. *Am J Cardiol* 2012;109:401-5.
30. Weidemann F, Eyskens B, Mertens L, et al. Quantification of regional right and left ventricular function by ultrasonic strain rate and strain indexes in Friedreich's ataxia. *Am J Cardiol* 2003;91:622-6.
31. Schöls L, Vorgerd M, Schillings M, et al. Idebenone in patients with Friedreich ataxia. *Neurosci Lett* 2001;306:169-72.
32. Lagedrost SJ, Sutton MS, Cohen MS, et al. Idebenone in Friedreich ataxia cardiomyopathy-results from a 6-month phase III study (IONIA). *Am Heart J* 2011;161:639-45.e1.
33. Pineda M, Arpa J, Montero R, et al. Idebenone treatment in paediatric and adult patients with Friedreich ataxia: long-term follow-up. *Eur J Paediatr Neurol* 2008;12:470-5.
34. Buyse G, Mertens L, Di Salvo G, et al. Idebenone treatment in Friedreich's ataxia: neurological, cardiac, and biochemical monitoring. *Neurology* 2003;60:1679-81.
35. Marcu CB, Niessen HW, Beek AM, et al. Cardiac involvement with amyloidosis: mechanisms of disease, diagnosis and management. *Conn Med* 2011;75:581-90.
36. Kapoor P, Thenappan T, Singh E, et al. Cardiac amyloidosis: a practical approach to diagnosis and management. *Am J Med* 2011;124:1006-15.
37. Porciani MC, Cappelli F, Perfetto F, et al. Rotational mechanics of the left ventricle in AL amyloidosis. *Echocardiography* 2010;27:1061-8.
38. Ballo P, Motto A, Corsini F, et al. Early improvement in cardiac function detected by tissue Doppler and strain imaging after melphalan-dexamethasone therapy in a 51-year old subject with severe cardiac amyloidosis. *Int J Cardiol* 2008;130:278-82.
39. Al-Zahrani GB, Bellavia D, Pellikka PA, et al. Doppler myocardial imaging compared to standard two-dimensional and Doppler echocardiography for assessment of diastolic function in patients with systemic amyloidosis. *J Am Soc Echocardiogr* 2009;22:290-8.
40. Bellavia D, Pellikka PA, Abraham TP, et al. Evidence of impaired left ventricular systolic function by Doppler myocardial imaging in patients with systemic amyloidosis and no evidence of cardiac involvement by standard two-dimensional and Doppler echocardiography. *Am J Cardiol* 2008;101:1039-45.
41. Koyama J, Falk RH. Prognostic significance of strain Doppler imaging in light-chain amyloidosis. *JACC Cardiovasc Imaging* 2010;3:333-42.
42. Bellavia D, Pellikka PA, Dispenzieri A, et al. Comparison of right ventricular longitudinal strain imaging, tricuspid annular plane systolic excursion, and cardiac biomarkers for early diagnosis of cardiac involvement and risk stratification in primary systemic (AL) amyloidosis: a 5-year cohort study. *Eur Heart J Cardiovasc Imaging* 2012;13:680-9.
43. Ogiwara F, Koyama J, Ikeda S, et al. Comparison of the strain Doppler echocardiographic features of familial amyloid polyneuropathy (FAP) and light-chain amyloidosis. *Am J Cardiol* 2005;95:538-40.
44. Baccouche H, Maunz M, Beck T, et al. Differentiating cardiac amyloidosis and hypertrophic cardiomyopathy by use of three-dimensional speckle tracking echocardiography. *Echocardiography* 2012;29:668-77.
45. Porciani MC, Lilli A, Perfetto F, et al. Tissue Doppler and strain imaging: a new tool for early detection of cardiac amyloidosis. *Amyloid* 2009;16:63-70-46. Cappelli F, Porciani MC, Bergesio F, et al. Characteristics of the left ventricular rotational mechanics in patients with systemic amyloidosis, systemic hypertension and normal left ventricular mass. *Clin Physiol Funct Imagin* 2011;31:159-65.
47. Modesto KM, Dispenzieri A, Cauduro SA, et al. Left atrial myopathy in cardiac amyloidosis: implications of novel echocardiographic techniques. *Eur Heart J* 2005;26:173-9.