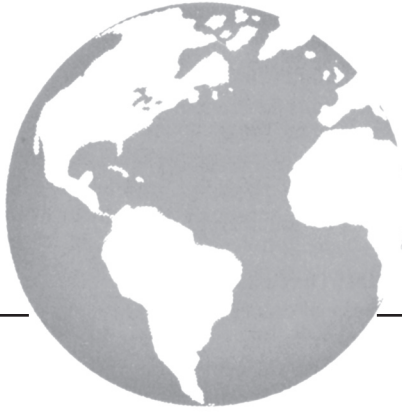



Radiotherapy for multiple myeloma with skin involvement

S.K.A. Nguyen MD and A. Dagnault MD PhD*†*

ABSTRACT

Multiple myeloma metastatic to the skin is a rare occurrence that usually reflects a high tumour burden. Here, we report the case of a woman with known multiple myeloma who developed cutaneous lesions on the right leg. Limited-field radiation treatment was successfully used to decrease her tumour bulk. Unfortunately, the patient died of complications related to systemic treatment a few months after developing the cutaneous involvement.

KEY WORDS

Multiple myeloma, skin, radiotherapy

1. INTRODUCTION

Multiple myeloma accounts for approximately 1% of all cancers and slightly more than 10% of all hematologic malignancies¹. This entity affects men more often than women and tends to occur in older adults. Only 2% of myeloma patients are younger than 40 years of age². Moreover, multiple myeloma with cutaneous involvement is uncommon. Here, we report the case of a 37-year-old woman with known multiple myeloma who developed cutaneous lesions on the right leg and who was treated with radiation therapy.

2. CASE DESCRIPTION

In March, 2009, a 37-year-old woman presented with a 3-week history of painless non-pruriginous cutaneous lesions on her swollen right ankle and leg, extending to 2 cm below the right knee. She had no history of allergic reactions, skin infection, or inflammatory disease. Her history was notable for stage IIIA immunoglobulin A-kappa (IgAκ) multiple myeloma (Durie–Salmon staging system), diagnosed a year earlier. She initially received thalidomide, but treatment was stopped early because of an acute drug-induced hepatitis. She then received 4 cycles of vincristine, doxorubicin, and dexamethasone

chemotherapy, to which she had a minor response. An autograft was consequently performed; however, during the autograft, the patient developed an acute pulmonary embolism, pneumonia, steroid myopathy, acute cholangitis, and a major depressive episode. Her skin lesions appeared 6 months after the autograft.

Her initial laboratory workup revealed a hemoglobin level of 12 g/dL, a creatinine level of 160 μmol/L (normal: 45–85 μmol/L), a calcium level of 4.3 mmol/L (normal: 2.15–2.60 mmol/L), an albumin level of 38 g/L (normal: 35–50 g/L), a β₂-microglobulin level of 3.1 mg/L (normal: 1–2.4 mg/L), and extensive lytic bone lesions. She had an excellent medullary response post transplantation, with less than 10% polyclonal plasmacytosis on bone marrow examination as compared with the 55%–60% noted when her disease was first diagnosed.

Initially, the patient's skin lesions were diagnosed as lichen planus, and a topical corticosteroid cream was prescribed to no avail. Lichen amyloidosis or papillomatose mucinosis were two other hypotheses that were raised. The lesions rapidly progressed and eventually numbered approximately 50. These firm, purplish papulonodular lesions appeared waxy and measured approximately 1–7 mm in size. They were distributed over almost the entire circumference of the right ankle and around her right proximal foot (Figure 1). The rest of her physical exam was non-contributory.

A punch biopsy of the lesions revealed cells compatible with massive myelomatous infiltration, rich in plasmablasts. The cells encountered were negative for CD45, CD20, CD10, and CD56, and positive for CD79a, CD138, MUM, Bcl2, and IgAκ compatible with the immunohistochemistry performed at initial diagnosis. There was no evidence of multiple myeloma relapse at any other site, except for a slightly higher plasma level of IgA. No systemic disease in the form of a serum monoclonal peak was found.

The patient was referred to radiation oncology to control proliferation of the lesions, because they had become painful as they increased in size. Allogeneic

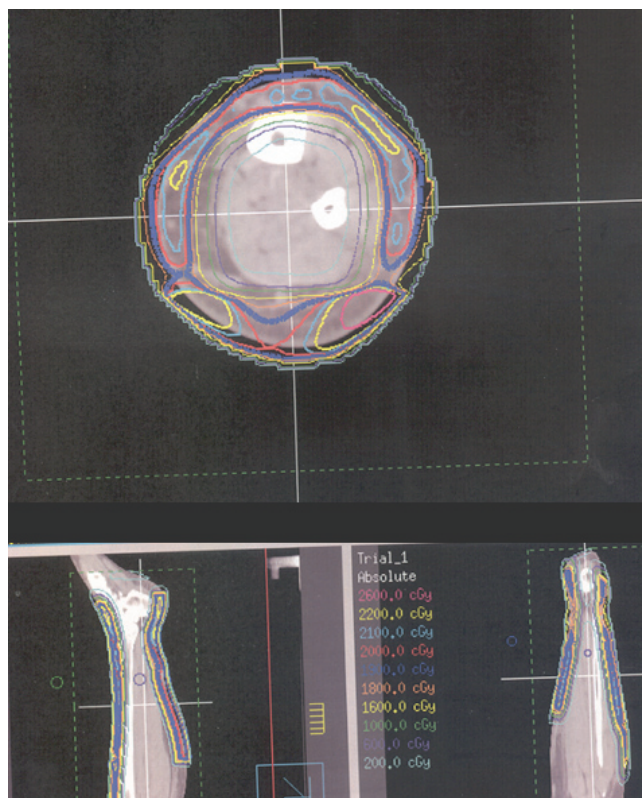


FIGURE 1 Axial planning (computed tomography) image depicting electron dosimetry.

stem-cell transplantation was considered, but did not remain an alternative because the patient relapsed early after the graft, and because her performance status was still poor because of the toxicities encountered. Given that fast relief was warranted, local treatment was preferred.

Because the lesions covered the whole circumference of this patient's right leg, electrons were used (20 Gy in 5 fractions) to adequately cover the lesions while preserving the normal underlying tissue. Conformal treatment with 5 fields (right and left lateral, right anterior oblique, right posterior oblique, and anterior) was carried out using 6 MeV electrons and a 0.5-cm bolus covering the right leg. The resulting field resembled a sock composed of electrons, warming the patient's right leg up to her knee (Figure 1). After 5 treatments, a significant decrease in the size of the lesions was noted.

At the 1 month follow-up, near-complete regression of the cutaneous lesions was observed: only 2 small lesions remained on the internal aspect of the patient's right ankle. She tolerated the treatment well and experienced only residual hyperpigmentation of the treated area (Figure 2).

Unfortunately, the lesions recurred at cutaneous sites not included in the initial radiation field, including the right foot, left ankle, right breast, left orbit,

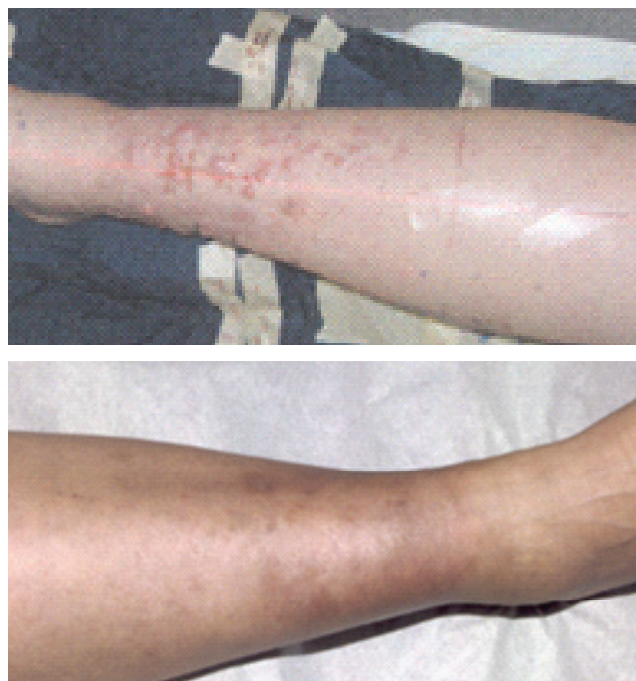

FIGURE 2 Radiation treatment of cutaneous myelomatous lesions. On the top, the myelomatous lesions before radiation treatment. On the bottom, the patient's leg 1 month after completing treatment.

and upper arm. Bortezomib with dexamethasone was initiated for 4 cycles, but the patient's pain continued, and she subsequently received photon radiation to the additional cutaneous sites at a dose of 20 Gy in 5 fractions.

Ultimately, while on lenalidomide therapy and low-dose dexamethasone, the patient developed a severe pneumonia with pancytopenia. She died October 14, 2009, of pulmonary complications.

3. DISCUSSION

Multiple myeloma is the proliferation of clonal plasma cells with monoclonal immunoglobulin production. This proliferation occurs in the bone marrow and results in skeletal destruction. Although skin metastasis from plasma cells is infrequent, it can occur. Ecotaxis (the migration of circulating cells into tissues with an appropriate microenvironment) has been suggested for lymphoid cells, which may explain the curious distribution of certain extranodal tumours. The same principle may also apply to myelomatous cells⁵.

The biology underlying skin homing for myeloma is not well understood. In a case report of subcutaneous and pelvic plasmacytoma in a woman with known immunoglobulin G (IgG)–kappa multiple myeloma, discordant lymphocyte function–associated antigen 1 (LFA-1) and intercellular adhesion molecule 1 (ICAM-1) adhesion molecules may have contributed to this pattern of growth through homing

of the LFA-1 α -positive, LFA-1 β -positive leukemic cells to positive endothelial cells⁶. Skin biopsy may therefore be warranted for patients with lesions originally diagnosed as a benign condition, but unresponsive to treatment, especially when the patient has a known malignancy.

Plasmacytomas are solitary masses of monoclonal plasma cells arising in bone (solitary bone plasmacytoma) or soft tissues (extramedullary plasmacytoma). Primary extramedullary plasmacytoma is defined by the presence of plasmacytoma without systemic or bone marrow involvement, but secondary extramedullary plasmacytoma can occur in the context of a patient with known multiple myeloma. Whether primary cutaneous plasmacytoma is an entity in itself or a manifestation of eventual multiple myeloma is a matter of debate.

Our experience is consistent with the current literature, which describes myelomatous cutaneous involvement. In a review, Kato *et al.* found that 13 of 83 cases of secondary cutaneous plasmacytoma were of the IgA subtype⁷. The IgG subtype seems to be the subtype most frequently associated with skin metastases from myeloma^{7,8}.

Skin involvement in patients with multiple myeloma usually occurs in the late stages of the disease and is often a reflection of high tumour burden⁸. Lesions tend to be non-pruriginous, large, and violaceous or erythematous; they also tend to have a wide anatomic distribution. Multiple skin lesions have also been described after prior myeloablative therapy and peripheral blood stem-cell autograft or the use of novel agents such as thalidomide to treat multiple myeloma^{9,10}. However, in an Italian longitudinal study of 1003 multiple myeloma patients, such agents did not appear to increase the risk of extramedullary disease¹¹. A few reports have described effective treatment with thalidomide or bortezomib¹², and a complete response to dexamethasone has also been reported in a patient with cutaneous myeloma¹³.

Our case illustrates the short survival once skin metastases develop. Radiation treatment was effective in clearing tumour bulk and reducing the pain associated with the lesions.

4. CONCLUSIONS

To the best of our knowledge, this is the first reported case of limited-field radiation treatment for cutaneous myeloma in a patient with a history of bone marrow plasmacytosis. Floyd *et al.* reported a case of palliative total skin electron therapy used to treat a 78-year-old man with cutaneous plasmacytoma; the therapy appeared to delay progression of the disease for a few months³. Tüting *et al.* also described a case of a 62-year-old woman who presented with a painless purple-red 2.5×5-cm plaque on her left thigh⁴. Underlying multiple myeloma was excluded

after the usual investigations. The primary plasmacytoma responded to local electron-beam radiation, but the details of the treatment were not mentioned in the report.

Treatment of cutaneous multiple myeloma is still somewhat controversial. In view of the paucity of cases, publication of all case reports is important to define the natural history and best therapeutic strategy for these patients. Multiple myeloma patients have a grave prognosis once skin metastases develop, but radiation treatment may provide worthwhile palliation. Accordingly, the primary goal of the radiation oncologist is to provide the fewest number of treatments warranted in view of the relatively high radiosensitivity of myeloma cells. This consideration is especially important in patients with limited performance status who may not tolerate further systemic treatments.

5. CONFLICT OF INTEREST DISCLOSURES

All authors declare that no financial conflicts of interest exist.

6. REFERENCES

1. Jemal A, Siegel R, Ward E, Hao Y, Xu J, Thun MJ. Cancer statistics, 2009. *CA Cancer J Clin* 2009;59:225–49.
2. Blade J, Kyle RA. Multiple myeloma in young patients: clinical presentation and treatment approach. *Leuk Lymphoma* 1998;30:493–501.
3. Floyd SR, Pantanowitz L, McDermott DF, *et al.* Plasma cell problems: case 1. Disseminated cutaneous plasmacytomas treated with total skin electron radiotherapy. *J Clin Oncol* 2005;23:3138–40.
4. Tüting T, Bork K. Primary plasmacytoma of the skin. *J Am Acad Dermatol* 1996;34:386–90.
5. Goudie RB, Macfarlane PS, Lindsay MK. Homing of lymphocytes to non-lymphoid tissues. *Lancet* 1974;1:292–3.
6. Tsutani H, Sugiyama T, Shimizu S, *et al.* Discordant LFA-1/ICAM-1 expression in a case of secondary plasma cell leukemia associated with subcutaneous plasmacytoma. *Am J Hematol* 1993;42:299–304.
7. Kato N, Kimura K, Yasukawa K, Aikawa K. Metastatic cutaneous plasmacytoma: a case report associated with IgA lambda multiple myeloma and a review of the literature of metastatic cutaneous plasmacytomas associated with multiple myeloma and primary cutaneous plasmacytomas. *J Dermatol* 1999;26:587–94.
8. Requena L, Kutzner H, Palmedo G, *et al.* Cutaneous involvement in multiple myeloma: a clinicopathologic, immunohistochemical, and cytogenetic study of 8 cases. *Arch Dermatol* 2003;139:475–86.
9. Ah-Weng A, Charles-Holmes R, Rose P, Basu S, Marsden JR, Sanders DS. Multiple cutaneous plasmacytomas following an autologous peripheral stem cell transplant. *Clin Exp Dermatol* 2002;27:293–5.
10. Yuan Y, Wiczorek R, Green DL, Cook P, Ballard H, Araten DJ. Multiple myeloma involving skin and pulmonary parenchyma

after autologous stem cell transplantation. *J Hematol Oncol* 2009;2:48.

11. Varettoni M, Corso A, Pica G, Mangiacavalli S, Pascutto C, Lazzarino M. Incidence, presenting features and outcome of extramedullary disease in multiple myeloma: a longitudinal study on 1003 consecutive patients. *Ann Oncol* 2009; 21:325–30.
12. Siniscalchi A, Fratoni S, Santeusano G, Del Poeta G, de Fabritiis P, Caravita T. Cutaneous involvement in multiple myeloma and bortezomib. *Ann Hematol* 2009;88:1137–9.
13. Gozzetti A, Defina M, Bocchia M. Cutaneous myeloma and bortezomib. *Ann Hematol* 2009;88:1045.

Correspondence to: Anne Dagnault, Département de Radio-Oncologie, Centre Hospitalier Universitaire de Québec, L'Hôtel-Dieu de Québec, 11 Côte du Palais, Quebec City, Quebec G1R 2J6.

E-mail: anne.dagnault@mail.chuq.qc.ca

* Département de Radio-Oncologie, L'Hôtel-Dieu de Québec, Centre Hospitalier Universitaire de Québec, Quebec City, QC.

† Centre de Recherche de L'Hôtel-Dieu de Québec, Centre Hospitalier Universitaire de Québec, Quebec City, QC.