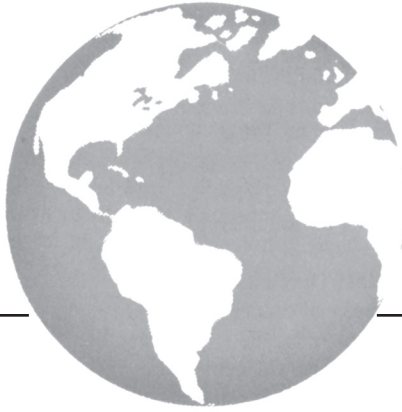



Analysis of intraprostatic therapeutic effects in prostate cancer patients using [¹¹C]-choline PET/CT after external-beam radiation therapy

J. Amanie MD, H.S. Jans PhD,[†] M. Wuest PhD,[‡] N. Pervez MD,* A. Murtha MD,* N. Usmani MD,* D. Yee MD,* R. Pearcey MD,* B. Danielson MD,* S. Patel MD,* R. Macewan MD,[‡] C. Field,[†] D. Robinson PhD,[†] J. Wilson PhD,[‡] D. Lewis RTT,* M. Parliament MD,* and A.J.B. McEwan MD[‡]*

ABSTRACT

Purpose

The objective of the present study was to analyze, with relatively high sensitivity and specificity, uptake properties of [¹¹C]-choline in prostate cancer patients by means of positron-emission tomography (PET)/computed tomography (CT) imaging using objectively defined PET parameters to test for statistically significant changes before, during, and after external-beam radiation therapy (EBRT) and to identify the time points at which the changes occur.

Methods

The study enrolled 11 patients with intermediate-risk prostate cancer treated with EBRT, who were followed for up to 12 months after EBRT. The [¹¹C]-choline PET scans were performed before treatment (baseline); at weeks 4 and 8 of EBRT; and at 1, 2, 3, 6, and 12 months after EBRT.

Results

Analysis of [¹¹C]-choline uptake in prostate tissue before treatment resulted in a maximum standardized uptake value (SUV_{max}) of 4.0 ± 0.4 (*n* = 11) at 40 minutes after injection. During week 8 of EBRT, the SUV_{max} declined to 2.9 ± 0.1 (*n* = 10, *p* < 0.05). At 2 and 12 months after EBRT, SUV_{max} values were 2.3 ± 0.3 (*n* = 10, *p* < 0.01) and 2.2 ± 0.2 (*n* = 11, *p* < 0.001) respectively, indicating that, after EBRT, maximum radiotracer uptake in the prostate was significantly reduced. Similar effects were observed when analyzing the tumour:muscle ratio (TMR). The TMR declined from 7.4 ± 0.6 (*n* = 11) before EBRT to 6.1 ± 0.4 (*n* = 11, nonsignificant) during week 8 of EBRT, to 5.6 ± 0.03 (*n* = 11, *p* < 0.05) at 2 months after EBRT, and to 4.4 ± 0.4 (*n* = 11, *p* < 0.001) at 12 months after EBRT.

Conclusions

Our study demonstrated that intraprostatic [¹¹C]-choline uptake in the 11 analyzed prostate cancer patients significantly declined during and after EBRT. The PET parameters SUV_{max} and TMR also declined significantly. These effects can be detected during radiation therapy and up to 1 year after therapy. The prognostic value of these early and statistically significant changes in intraprostatic [¹¹C]-choline PET avidity during and after EBRT are not yet established. Future studies are indicated to correlate changes in [¹¹C]-choline uptake parameters with long-term biochemical recurrence to further evaluate [¹¹C]-choline PET changes as a possible, but currently unproven, biomarker of response.

KEY WORDS

External-beam radiation therapy, EBRT, positron-emission tomography, PET, [¹¹C]-choline

1. INTRODUCTION

1.1 [¹¹C]-Choline Positron-Emission Tomography in Prostate Cancer

Positron-emission tomography (PET) has proved to be useful as a noninvasive imaging tool suitable for the diagnosis and staging of prostate cancer¹. Use of the most common PET radiotracer, [¹⁸F]-fluoro-2-deoxy-D-glucose ([¹⁸F]-FDG), has led to mixed results based on its overlapping accumulation in normal prostate tissue, benign prostatic hyperplasia, and prostate cancer tissue²⁻⁴. Furthermore, accumulation of [¹⁸F]-FDG in the urinary bladder may mask uptake in the prostate gland and pelvic nodes, limiting their assessment⁵. False-positive results were reported for prostatitis⁶ based on the accumulation of [¹⁸F]-FDG in inflamed prostate glands. Assessment of androgen

deprivation therapy showed lower standardized uptake values (SUVs) for [¹⁸F]-FDG in prostate tissue, but the effects of gemcitabine therapy were not detectable².

Alternatives to [¹⁸F]-FDG for PET imaging in prostate cancer—including [¹⁸F]-acetate^{7,8} or [¹¹C]-acetate^{9,10} and [¹⁸F]-choline^{11,12} or [¹¹C]-choline^{13,14}—have been studied using various targeting approaches. For detecting primary prostate cancer, [¹¹C]-acetate and [¹¹C]-choline have been shown to result in nearly identical uptake, leading to similar applicability¹⁵. Compared with [¹⁸F]-FDG, [¹¹C]-choline has been shown to have greater uptake in malignant prostate lesions (both primary tumour and lymph node metastases), with significantly reduced urinary excretion^{16,17}. Uptake of [¹¹C]-choline correlates with increased levels of prostate-specific antigen (PSA) in some studies, but that finding is not consistent in the literature¹. Observations during androgen deprivation therapy with bicalutamide or leuprolide provided evidence for the usefulness of [¹¹C]-choline PET when monitoring therapy in prostate cancer patients^{18,19}. A preclinical study analyzing therapy response to docetaxel has shown that [¹¹C]-choline PET may be a valuable tool for monitoring response to taxane-based chemotherapy in patients with advanced prostate cancer²⁰.

1.2 [¹¹C]-Choline PET to Objectively Evaluate Early Response to External-Beam Radiation Therapy

Specific molecular imaging approaches for prostate carcinoma may provide valuable information for the design and implementation of adaptive radiation therapy techniques and early assessment of the efficacy of novel radiation therapy approaches (such as hypofractionated radiation therapy), potentially serving as valuable surrogate endpoints²¹.

Assessment of the local control rate in prostate carcinoma has so far been accomplished by post-treatment core biopsies; however, the accuracy of this method is limited by sampling error and post-treatment changes²². Functional imaging modalities such as magnetic resonance imaging (MRI) and PET have provided evidence for improved assessment and evaluation of local control and the response of prostate cancer to treatment^{23,24}. Although the role of PET as a monitoring standard for the therapy of prostate cancer remains to be clarified, the use of PET radiotracers in therapy planning is an area of active and growing research²⁵. Promising data suggest a potential clinical role for [¹¹C]-choline PET as an imaging tool in the irradiation treatment of prostate cancer relapse²⁶. When step-section histologic analysis of prostatectomy specimens was compared with preoperative intraprostatic imaging, [¹¹C]-choline PET was shown to be more sensitive and specific than MRI in detecting primary prostate lesions^{27,28}.

The goal of the present prospective study was to evaluate the feasibility of using [¹¹C]-choline PET/CT

with relatively high sensitivity and specificity, with objectively defined PET parameters, to test for statistically significant changes before, during, and after external-beam radiation therapy (EBRT) and to identify the time points at which the changes occur.

2. METHODS

Our Institutional Research Ethics Committee approved this clinical study. All patients enrolled gave written informed consent.

2.1 Patient Population

This prospective study enrolled 11 patients (50–79 years of age) with intermediate-risk localized prostate cancer. “Intermediate risk” was defined by applying the widely used D’Amico criteria: Gleason score 7, PSA less than 20 ng/mL, and T1–T2C; or Gleason score 6, PSA 10–20 ng/mL, and T1–T2C; or Gleason score 6 or 7, PSA less than 20 ng/mL, and T2C²⁹. All patients underwent staging at diagnosis, including determination of baseline PSA level, a digital rectal exam, bone scan using [^{99m}Tc]-methylene diphosphonate, and CT imaging of abdomen and pelvis.

2.2 Radiation Treatment

All 11 patients received EBRT using intensity-modulated radiation therapy to a dose of at least 74 Gy, at 2 Gy per fraction daily, for a period of 8 weeks. None of the patients received hormonal therapy.

2.3 PET Imaging

The [¹¹C]-choline was synthesized at the Edmonton PET Centre according to a “loop” synthesis method using [¹¹C]-iodomethane³⁰. For all patients, [¹¹C]-choline PET measurements were performed on a PET/CT scanner (Gemini GS; Philips Healthcare, Best, Netherlands) dynamically in 2-minute time increments from injection to 40 minutes after injection. Patients fasted for 12 hours before each PET study and received approximately 400 MBq [¹¹C]-choline intravenously for each scan. Radiotracer injection occurred immediately after the start of the PET, which in turn commenced after acquisition of the CT images. The [¹¹C]-choline PET images were obtained before treatment (baseline), at weeks 4 and 8 of EBRT, and at 1, 2, 3, 6, and 12 months after EBRT.

2.4 Image Data Analysis

The PET data were reconstructed using the 3-dimensional row action maximum likelihood algorithm (2 iterations) with standard clinical settings, including all corrections (randoms, scatter, attenuation, decay). The reconstructed images were analyzed using

the Region of Interest Visualization, Evaluation and Image Registration software (ABX Advanced Biochemical Compounds, Radeberg, Germany). Prostate uptake was quantified by placing a spherical region (“mask”) on the prostate and querying the voxel with maximum SUV (SUV_{max}) within the mask. Tracer uptake in muscle was quantified by placing a spherical mask on muscular tissue of uniform uptake in the upper thigh; the mean SUV (SUV_{mean}) within that region was then calculated and recorded. The tumour-to-muscle ratio (TMR) was calculated as the ratio of the prostate SUV_{max} to the muscle SUV_{mean} . The SUV_{max} and TMR values were both determined at baseline and at each follow-on scan up to 60 weeks. At each time point, the SUVs and TMRs for all patients, and the standard error of the mean calculated for each of those two parameters, were averaged. The statistical analysis of SUV_{max} and TMR at each time point relative to baseline was performed using the Student *t*-test. Values of $p < 0.05$ were considered statistically significant.

3. RESULTS

3.1 SUV_{max} Before and After EBRT

Figure 1(A) depicts the patient-averaged SUV_{max} of the prostate at 40 minutes after injection for the 8 [¹¹C]-choline PET studies from baseline to 60 weeks. Images obtained before treatment resulted in a SUV_{max} of 4.0 ± 0.4 ($n = 11$). At week 8 of EBRT, the SUV_{max} declined to 2.9 ± 0.1 ($n = 11$, $p < 0.05$). At 2 months after EBRT, the SUV_{max} further declined to 2.3 ± 0.3 ($n = 10$, $p < 0.01$). Up to 12 months after EBRT, the SUV_{max} remained low [measuring 2.2 ± 0.2 ($n = 11$, $p < 0.001$)], indicating that, compared with baseline, the maximum radiotracer uptake was significantly reduced after EBRT.

3.2 TMR Before and After EBRT

The TMRs were calculated from the SUV_{max} of the tumour lesion and the subsequent SUV_{mean} of muscle tissue. Figure 1(B) shows the observed changes in TMR values over time. At the 8th week of EBRT, TMR had declined to 6.1 ± 0.4 ($n = 11$, nonsignificant). At 2 months after EBRT, the TMR had declined further to 5.6 ± 0.3 ($n = 11$, $p < 0.05$). The TMR remained low up to 12 months after EBRT, measuring 4.4 ± 0.4 ($n = 11$, $p < 0.001$).

Table 1 summarizes the SUV_{max} and TMR values for each individual study patient at week 0 (baseline scan), week 8 (8th week of EBRT), week 16 (2 months after EBRT), and week 60 (1 year after EBRT). Both parameters were reduced during and after radiation therapy and remained approximately constant (SUV_{max}) or declined even further (TMR) at the 1-year follow-up [¹¹C]-choline PET.

3.3 Correlation with PSA

Prostate-specific antigen was determined before EBRT (week 0), and at 16, 20, 32, and 60 weeks. Levels of PSA declined from a pre-treatment 13.6 ± 1.5 ng/mL ($n = 11$) to 2.1 ± 0.5 ng/mL ($n = 10$) at 16 weeks and further to 2.1 ± 0.5 ng/mL ($n = 6$) at 1 year after radiation therapy [Figure 2(A)]. No correlation between SUV_{max} and PSA was found in our patient population either at baseline or at 60 weeks [Figure 2(B)].

4. DISCUSSION

In recent years, the use of noninvasive PET/CT imaging for the detection of primary prostate cancer has increased in many centres worldwide, especially using [¹¹C]-choline and, more recently, [¹⁸F]-choline because of that isotope's longer half-life¹. Despite

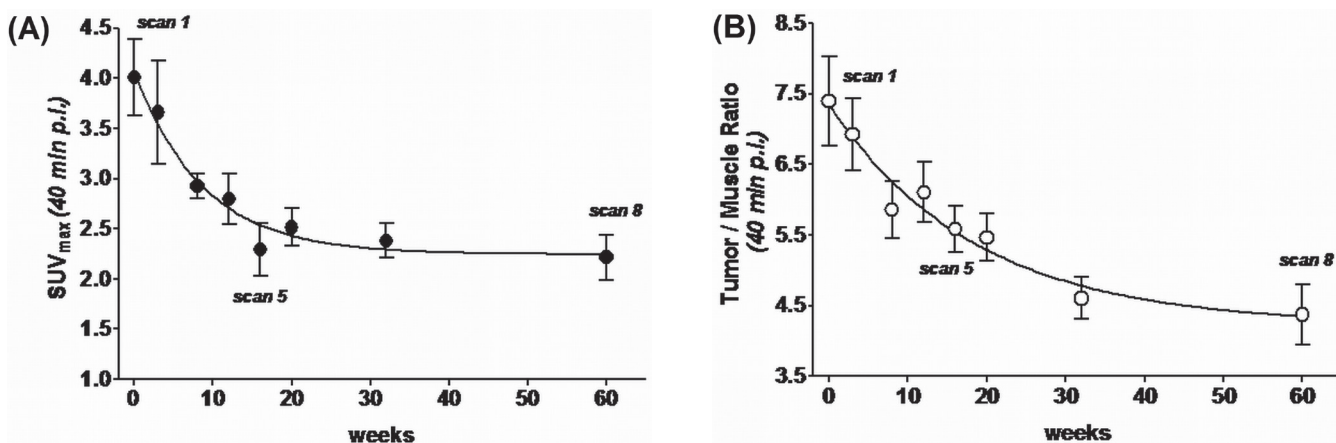


FIGURE 1 Patient-averaged values of (A) the maximal standardized uptake value (SUV_{max}) and (B) the tumour:muscle ratio for [¹¹C]-choline uptake in the dominant intraprostatic lesion from baseline to 60 weeks after external-beam radiation therapy. *mln* = mediastinal lymph nodes; *p.i.* = post injection.

TABLE 1 Overview of data recorded for the study patients

Pt ID	Age (years)	Baseline PSA (ng/mL)	Maximal standardized uptake value				Tumour:muscle ratio			
			Baseline (scan 1)	Week 8 (scan 3)	Week 16 (scan 5)	Week 60 (scan 8)	Baseline (scan 1)	Week 8 (scan 3)	Week 16 (scan 5)	Week 60 (scan 8)
1	66	12	4.4	2.8	2.9	2.5	6.9	7.1	6.1	4.6
2	71	12	6.7	3.6	2.2	2.2	8.6	5.3	5.8	3.8
3	75	18	5.2	3.0		1.4	10.0	7.9		2.8
4	75	20	3.7	2.7	2.1	2.6	7.0	5.3	5.3	5.1
5	79	17	3.5	2.5	1.6	1.0	10.4	6.1	3.6	2.6
6	64	9.0	3.6	3.5	1.7	1.4	7.0	6.3	6.3	3.1
7	70	5.6	4.3	2.9	0.9	3.6	8.9	8.6	6.9	5.0
8	77	19	2.9	2.2	2.1	2.3	3.7	4.5	5.1	6.3
9	78	13	1.9	2.7	2.9	2.1	4.4	5.0	6.4	3.9
10	50	6.4	3.3	3.0	2.4	2.1	6.8	4.1	4.2	3.8
11	61	18	4.8	3.3	3.9	3.0	7.8	7.1	6.0	7.1
Mean	70	13.6	4.0	2.9 ^a	2.3 ^b	2.2 ^c	7.4	6.1 ^d	5.6 ^a	4.4 ^c
SEM	3	1.5	0.4	0.1	0.3	0.2	0.6	0.4	0.3	0.4

^a $p < 0.05$ versus baseline mean.

^b $p < 0.01$ versus baseline mean.

^c $p < 0.001$ versus baseline mean.

^d Nonsignificant.

PSA = prostate-specific antigen; SEM = standard error of the mean.

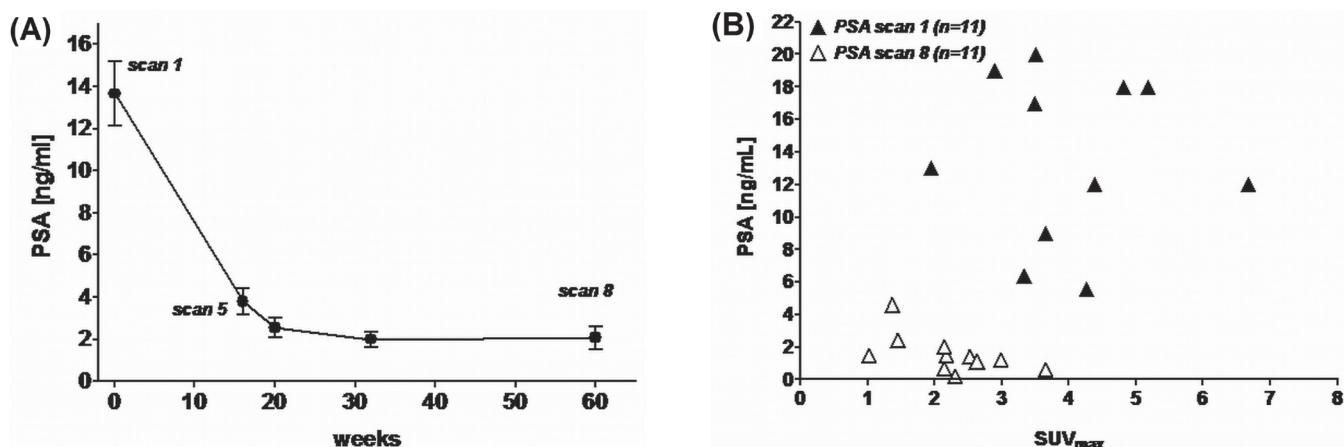


FIGURE 2 (A) Patient-averaged values of prostate-specific antigen (PSA) from baseline to 60 weeks after external-beam radiation therapy. (B) Correlation between individual-patient PSA values and the maximal standardized uptake value (SUV_{max}) for [¹¹C]-choline uptake at baseline and 60 weeks.

those trends, no final recommendations for the use of PET/CT in the diagnosis, staging, and treatment of prostate cancer have been published by either the American Urological Association or the European Association of Urology. Also, the use of [¹¹C]- and [¹⁸F]-choline for monitoring and planning prostate cancer radiotherapy has yet to be elucidated^{25,26}.

The results of the present study suggest that [¹¹C]-choline PET may be used to detect early post-treatment changes in patients with intermediate-risk prostate cancer during and after EBRT. A [¹¹C]-choline PET was able to detect statistically significant

intraprostatic changes during and up to 1 year after EBRT. The baseline SUV_{max} (4.0) observed in our study is consistent with similar results by Reske *et al.*¹⁴, who used [¹¹C]-choline PET to determine a baseline SUV_{max} of 3.5 ± 1.3 (mean ± standard deviation) based on a diagnostic study of 26 prostate cancer patients. The authors indicated a mean PSA of 14.4 ng/mL, which is similar in range to the mean PSA (13.6 ng/mL) in the present study. In comparison, Giovacchini *et al.*¹⁸ reported a higher baseline SUV_{max} of 5.4 ± 1.7 (mean ± standard deviation), with a mean PSA of 12.9 ng/mL for patients not undergoing

neoadjuvant androgen deprivation therapy. Based on the analysis by Reske *et al.*¹⁴, SUV_{max} values of 2.0, 1.7, and 2.1 were associated with benign prostatic hyperplasia, normal prostate tissue, and focal prostatitis respectively, and a SUV_{max} of 2.5 was considered the optimal threshold to distinguish between benign and malignant histopathology. A SUV_{max} of 2.2 and a PSA of 2.1 ng/mL at 1 year after EBRT in the present study is below the estimated threshold for malignant histopathology; however, the threshold needs to be confirmed with biopsies for histology and long-term follow-up of biochemical disease-free survival and local recurrence rates in this patient population. Clinical local recurrence rates for intermediate-risk prostate cancer treated with dose-escalated EBRT are generally low, and therefore the low-average post-EBRT SUV_{max} in our study is consistent with this finding.

Positive correlation between [¹¹C]-choline SUV_{max} and PSA level is controversial¹; no such correlation was found in the data from the patient population in the present study, neither at baseline, nor at 60 weeks. On the other hand, the lower SUV_{max} after 1 year does correlate with the lower PSA determined at the same time. In a recent study using [¹¹C]-choline to analyze prostate cancer recurrence, the detection rate of [¹¹C]-choline was found to increase with increasing PSA level³¹, which would suggest a possible role for [¹¹C]-choline PET in the diagnosis of localized recurrent disease as well as in disease management.

Comparisons between imaging modalities have shown that [¹¹C]-choline and [¹⁸F]-choline carry high sensitivity and specificity for diagnostic molecular imaging of primary intraprostatic lesions^{27,28} or the detection of locally recurrent or metastatic disease¹. There is still a paucity of data in the published literature about the quantitative evaluation of functional changes in the prostate after EBRT and the time interval over which those changes might occur. Local recurrences of prostate cancer are difficult to detect with transrectal ultrasound. Other imaging modalities—for example, MRI—have been proved to be more sensitive than transrectal ultrasound, but they have significant detection limits²⁴. However, PET using a variety of radiotracers has shown higher accuracy for the detection of residual and recurrent prostate cancer. Patients with PSA values below 1 ng/mL are unlikely to have detectable local recurrence by either MRI or PET after therapy, but a possible threshold PSA value of more than 2 ng/mL has been demonstrated for detection of local recurrence after radiation therapy with the use of [¹¹C]- or [¹⁸F]-choline PET²⁴. Breeuwsma *et al.* used [¹¹C]-choline PET to analyze 70 patients with biochemical recurrence (mean PSA: 12.3 ng/mL) and a disease-free period of 72 months after EBRT³². Higher [¹¹C]-choline uptake was found in 57 patients (81%), and a local recurrence site was detected in 41. The authors concluded that [¹¹C]-choline PET is

highly sensitive for detecting recurrence in prostate cancer patients with a PSA relapse after EBRT.

The present study was designed to evaluate [¹¹C]-choline intraprostatic uptake during and after EBRT with the aim of determining how soon functional changes occur. It demonstrated that a decrease in SUV_{max} and TMR was detectable during EBRT and that, before the end of radiation therapy, the changes reached statistical significance. Long-term observation (up to 1 year after therapy) saw a further decrease in SUV_{max} and TMR. Longer follow-up to correlate the early changes in objective imaging parameters with biochemical disease-free survival is indicated and may provide avenues for early salvage treatment of specific patients after EBRT if these statistically significant and early [¹¹C]-choline PET changes are found to demonstrate response.

5. CONCLUSIONS

The present study demonstrated that intraprostatic [¹¹C]-choline uptake in prostate cancer (which has relatively high sensitivity and specificity) is significantly reduced during EBRT according to the objectively defined PET parameters SUV_{max} and TMR, and that it remains reduced for up to 1 year after EBRT. The current data support the use of [¹¹C]-choline PET for the detection of early functional changes in intraprostatic tumour tissue during and after EBRT. The prognostic implications of these statistically significant early functional intraprostatic changes are not established. It is important to note that the findings in the present study are not sufficient to show that [¹¹C]-choline is a biomarker of response. Future studies are indicated to correlate changes in specific [¹¹C]-choline uptake parameters with long-term biochemical recurrence. Further evaluation of [¹¹C]-choline response is warranted as a possible (but currently unproven) method to risk-stratify patients for early salvage treatment based on PET response after EBRT.

6. ACKNOWLEDGMENTS

Preliminary results of this work were presented at the 25th Annual Scientific Meeting of the Canadian Association of Radiation Oncology; Winnipeg, Manitoba, Canada; September 14–17, 2011.

We thank Lai Schrader for her expertise and invaluable assistance in the accrual and data management for this study, and Merlita Lamadrid for data management. We thank David Clendening, Jayden Sader, and Blake Lazurko from the Edmonton PET Centre for radionuclide production and excellent technical support.

7. CONFLICT OF INTEREST DISCLOSURES

The authors have no financial conflicts of interest to declare.

8. REFERENCES

- Jadvar H. Prostate cancer: PET with ^{18}F -FDG, ^{18}F - or ^{11}C -acetate, and ^{18}F - or ^{11}C -choline. *J Nucl Med* 2011;52:81–9.
- Effert PJ, Bares R, Handt S, Wolff JM, Büll U, Jakse G. Metabolic imaging of untreated prostate cancer by positron emission tomography with ^{18}F fluorine-labeled deoxyglucose. *J Urol* 1996;155:994–8.
- Hofer C, Laubenbacher C, Block T, Breul J, Hartung R, Schwaiger M. Fluorine-18–fluorodeoxyglucose positron emission tomography is useless for the detection of local recurrence after radical prostatectomy. *Eur Urol* 1999;36:31–5.
- Salminen E, Hogg A, Binns D, Frydenberg M, Hicks R. Investigations with FDG PET scanning in prostate cancer show limited value for clinical practice. *Acta Oncol* 2002;41:425–9.
- Liu JJ, Zafar MB, Lai YH, Segall GM, Terris MK. Fluorodeoxyglucose positron emission tomography studies in diagnosis and staging of clinically organ-confined prostate cancer. *Urology* 2001;57:108–11.
- Kao PF, Chou YH, Lai CW. Diffuse FDG uptake in acute prostatitis. *Clin Nucl Med* 2008;33:308–10.
- Matthies A, Ezziddin S, Ulrich EM, *et al.* Imaging of prostate cancer metastases with ^{18}F -fluoroacetate using PET/CT. *Eur J Nucl Med Mol Imaging* 2004;31:797.
- Ponde DE, Dence CS, Oyama N, *et al.* ^{18}F -Fluoroacetate: a potential acetate analog for prostate tumor imaging—in vivo evaluation of ^{18}F -fluoroacetate versus ^{11}C -acetate. *J Nucl Med* 2007;48:420–8.
- Oyama N, Miller TR, Dehdashti F, *et al.* ^{11}C -Acetate PET imaging of prostate cancer: detection of recurrent disease at PSA relapse. *J Nucl Med* 2003;44:549–55.
- Cimitan M, Bortolus R, Morassut S, *et al.* [^{18}F]Fluorocholine PET/CT imaging for the detection of recurrent prostate cancer at PSA relapse: experience in 100 consecutive patients. *Eur J Nucl Med Mol Imaging* 2006;33:1387–98.
- Beheshti M, Imamovic L, Broinger G, *et al.* ^{18}F Choline PET/CT in the preoperative staging of prostate cancer in patients with intermediate or high risk of extracapsular disease: a prospective study of 130 patients. *Radiology* 2010;254:925–33.
- Hara T, Kosaka N, Kishi H. PET imaging of prostate cancer using carbon-11–choline. *J Nucl Med* 1998;39:990–5.
- Kotzerke J, Prang J, Neumaier B, *et al.* Experience with carbon-11 choline positron emission tomography in prostate carcinoma. *Eur J Nucl Med* 2000;27:1415–19.
- Reske SN, Blumstein NM, Neumaier B, *et al.* Imaging prostate cancer with ^{11}C -choline PET/CT. *J Nucl Med* 2006;47:1249–54.
- Kotzerke J, Volkmer BG, Glatting G, *et al.* Intraindividual comparison of [^{11}C]acetate and [^{11}C]choline PET for detection of metastases of prostate cancer. *Nuklearmedizin* 2003;42:25–30.
- de Jong IJ, Pruim J, Elsinga PH, Vaalburg W, Mensink HJ. Visualization of prostate cancer with ^{11}C -choline positron emission tomography. *Eur Urol* 2002;42:18–23.
- Picchio M, Messa C, Landoni C, *et al.* Value of [^{11}C]choline-positron emission tomography for re-staging prostate cancer: a comparison with [^{18}F]fluorodeoxyglucose-positron emission tomography. *J Urol* 2003;169:1337–40.
- Giovacchini G, Picchio M, Coradeschi E, *et al.* [^{11}C]Choline uptake with PET/CT for the initial diagnosis of prostate cancer: relation to PSA levels, tumour stage and anti-androgenic therapy. *Eur J Nucl Med Mol Imaging* 2008;35:1740–1.
- De Waele A, Van Binnebeek S, Mottaghy FM. Response assessment of hormonal therapy in prostate cancer by [^{11}C] choline PET/CT. *Clin Nucl Med* 2010;35:701–3.
- Krause BJ, Souvatzoglou M, Herrmann K, *et al.* [^{11}C]Choline as pharmacodynamic marker for therapy response assessment in a prostate cancer xenograft model. *Eur J Nucl Med Mol Imaging* 2010;37:1861–8.
- Mageras GS, Mechalakos J. Planning in the IGRT context: closing the loop. *Semin Radiat Oncol* 2007;17:268–77.
- Boukaram C, Hannoun-Levi JM. Management of prostate cancer recurrence after definitive radiation therapy. *Cancer Treat Rev* 2010;36:91–100.
- Pucar D, Sella T, Schröder H. The role of imaging in the detection of prostate cancer local recurrence after radiation therapy and surgery. *Curr Opin Urol* 2008;18:87–97.
- Martino P, Scattoni V, Galosi AB, *et al.* Role of imaging and biopsy to assess local recurrence after definitive treatment for prostate carcinoma (surgery, radiotherapy, cryotherapy, HIFU). *World J Urol* 2011;29:595–605.
- Lucignani G, Zaidi H. PET-guided prostate cancer radiotherapy: technological innovations for dose delivery optimization. *Eur J Nucl Med Mol Imaging* 2010;37:1426–9.
- Picchio M, Giovannini E, Crivellaro C, *et al.* Clinical evidence on PET/CT for radiation therapy planning in prostate cancer. *Radiother Oncol* 2010;96:347–50.
- Yamaguchi T, Lee J, Uemura H, *et al.* Prostate cancer: a comparative study of ^{11}C -choline PET and MR imaging combined with proton MR spectroscopy. *Eur J Nucl Med Mol Imaging* 2005;32:742–8.
- Farsad M, Schiavina R, Castellucci P, *et al.* Detection and localization of prostate cancer: correlation of ^{11}C -choline PET/CT with histologic step-section analysis. *J Nucl Med* 2005;46:1642–9.
- D'Amico AV, Whittington R, Malkowicz SB, *et al.* Biochemical outcome after radical prostatectomy, external beam radiotherapy, or interstitial radiation therapy for clinically localized prostate cancer. *JAMA* 1998;280:969–74.
- Wilson AA, Garcia A, Jin L, Houle S. Radiotracer synthesis from [^{11}C]iodomethane: a remarkable simply captive solvent method. *Nucl Med Biol* 2000; 27:529–32.
- Krause BJ, Souvatzoglou M, Tuncel M, *et al.* The detection rate of [^{11}C]choline-PET/CT depends on the serum PSA-value in patients with biochemical recurrence of prostate cancer. *Eur J Nucl Med Mol Imaging* 2008;35:18–23.
- Breeuwsma AJ, Prium J, van der Berg ACM, *et al.* Detection of local, regional and distant recurrence in patients with PSA relapse after external-beam radiotherapy using ^{11}C -choline positron emission tomography. *Int J Radiat Oncol Biol Phys* 2010;77:160–4.

Correspondence to: John Amanie, Division of Radiation Oncology, Cross Cancer Institute, 11560 University Avenue, Edmonton, Alberta T6G 1Z2.
E-mail: john.amanie@albertahealthservices.ca

* Division of Radiation Oncology, Department of Oncology, University of Alberta, Cross Cancer Institute, Edmonton, AB.

† Division of Medical Physics Division of Oncologic Imaging, Department of Oncology,

University of Alberta, Cross Cancer Institute, Edmonton, AB.

‡ Division of Oncologic Imaging, Department of Oncology, University of Alberta, Cross Cancer Institute, Edmonton, AB.