



Successful use of metronomic vinblastine and fluorothymidine PET imaging for the management of intramedullary spinal cord anaplastic oligoastrocytoma in a child

R. Demlova MD PhD,^{*†a} K. Melicharkova MD,^{‡a}
Z. Rehak MD PhD,^{§†} L. Kren MD PhD,^{||}
H. Oslejskova MD PhD,[#] and J. Sterba MD PhD^{†‡}

ABSTRACT

Background

Children with high-grade glioma still have a poor prognosis despite the use of multimodal therapy including surgery, radiotherapy, and chemotherapy. New therapeutic strategies and methods evaluating such therapies are needed.

Observation

Here we describe a child with anaplastic oligodendroglioma of the spinal cord who was unable to tolerate standard chemoradiotherapy and who had still-vital residual tumour during therapy. A good response was obtained with low-dose metronomic treatment containing vinblastine. The treatment was guided according to gradual response assessed using various positron-emission tomography tracers.

Conclusions

Metronomic treatment guided by positron-emission tomography could be a reasonable option in some high-risk pediatric tumours.

KEY WORDS

Metronomic chemotherapy, PET imaging, biomarkers, vinblastine, pediatric glioma

1. INTRODUCTION

Intramedullary spinal cord tumours make up 3%–5% of pediatric CNS tumours, with 70% being gliomas¹. The prognosis for children with high-grade glioma remains poor despite the use of multimodal therapy including surgery, radiotherapy, and chemotherapy².

Exploration of new therapeutic options and management strategies is an ongoing need.

2. CASE DESCRIPTION

An 11-year-old girl had a history of progressive low back pain, incontinence, and paraparesis of both lower extremities lasting 4 months before her diagnosis with an intramedullary spinal cord tumour at the T9–10 level. Sensory irritative paresthesia with prurigo and perception changes led to intensive scratching and a bacterial superinfection resembling scabies. Histopathology revealed an anaplastic oligoastrocytoma, World Health Organization grade 3 as assessed by two board-certified pathologists.

Subsequent follow-up with array-based comparative genomic hybridization studies revealed a total loss of 1p and 19q. Magnetic resonance imaging (MRI) showed tumour involvement of the whole diameter of spine without any signs of metastatic disease, but complete resection was deemed impossible by several neurosurgeons.

Treatment was commenced according to the ACNS0126 protocol with temozolomide (90 mg/m²) for 42 days with concomitant radiotherapy (45 Gy) to the tumour bed³. Because of grade 4 myelosuppression lasting 5 weeks and the reappearance of clinical symptoms, that treatment protocol was stopped. The patient was then offered low-dose COMBAT metronomic chemotherapy (temozolomide, etoposide, celecoxib, retinoic acid)⁴, which contained COMBAT II (plus vitamin D and fenofibrate) and COMBAT III⁵ (plus bevacizumab) for 31 months, using temozolomide 30 mg/m² daily for 42 days and etoposide 25 mg/m² daily. However, that dosing schedule had to be reduced by 50% because of grades 3 and 4 bone marrow toxicity. Tumour assessment by MRI after 30 months of metronomic treatment revealed stable disease, with very high avidity on both ¹⁸F-fluorodeoxyglucose (FDG) positron-emission tomography (PET) and ¹⁸F-fluorothymidine (FLT) PET (Figure 1).

^a These authors contributed equally to the present work.

Because of myelosuppression during the COMBAT regimen, we considered a treatment change to vinblastine as a single agent at the standard dose 6 mg/m² weekly⁶. Decisions about treatment options were always discussed with the patient and her family, who accepted the suggested changes. However, a vinblastine dose reduction was needed to avoid grade 3 and higher myelosuppression. At a vinblastine dose of 2 mg/m² weekly, the patient was free from grades 3 and 4 hematologic toxicity and was able to continue treatment for 12 months.

Tumour status was repeatedly reassessed. We observed a gradual decrease of the FLT PET avidity, with complete FLT negativity achieved after 12 months of the low-dose vinblastine treatment. At that time, MRI continued to report stable disease, with post-contrast enhancement. Based on the FLT PET negativity (Figure 2), anticancer therapy was discontinued 3 months later—that is, after 16 months of vinblastine treatment and 51 months of overall antineoplastic treatment (Figure 3).

At 20 months after treatment cessation, FLT and FDG PET imaging were both still negative (Figure 2). The girl is using a wheelchair, but is able to control her sphincter physiology and has a high quality of life, participating in various activities and social interests. She is working as a beautician.

3. DISCUSSION

The unsatisfactory results of current treatment approaches for high-grade glioma in children are well known. Our case report documents two major learnings. First, we observed a very good effect of prolonged low-dose vinblastine after prolonged metronomic treatment with COMBAT for this particular subtype of high-grade glioma, with imaging showing a gradual decline in the metabolic activity of the tumour. Second, innovative diagnostic approaches for assessing the efficacy of antiangiogenic and metronomic treatment regimens are needed, because the standard Response Evaluation Criteria in Solid Tumors^{7,8} are not sufficiently reliable or predictive to guide treatment decisions. In our case, FDG PET and, specifically, FLT PET were substantially helpful in assessing disease activity.

The efficacy and toxicity of the COMBAT regimens were recently reported^{4,9}, and so here we focus on vinblastine, which was the most successful part of our patient's treatment. Vinblastine belongs to the group of vinca alkaloids derived from leaf extracts of the periwinkle plant¹. It is used in the treatment of recurrent anaplastic large cell lymphoma¹⁰, Hodgkin disease¹¹, low-grade glioma in children¹², and germ-cell tumours¹³. Although vinblastine is a lipophilic agent, animal studies showed low brain penetration and a low concentration in brain tissue and cerebrospinal fluid. One explanation for the activity of vinblastine in gliomas could be in its antiangiogenic

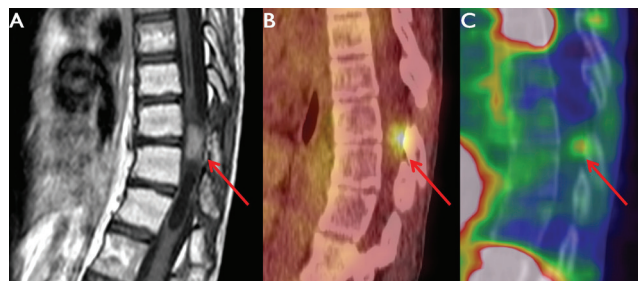


FIGURE 1 Tumour staging before vinblastine treatment. (A) T1-weighted turbo spin-echo magnetic resonance imaging. (B) Combined fluorodeoxyglucose positron-emission tomography and low-dose computed tomography. (C) Combined fluorothymidine positron-emission tomography and low-dose computed tomography. Corresponding transverse slides show high uptake of both fluorodeoxyglucose and fluorothymidine in an intramedullary localized tumour.

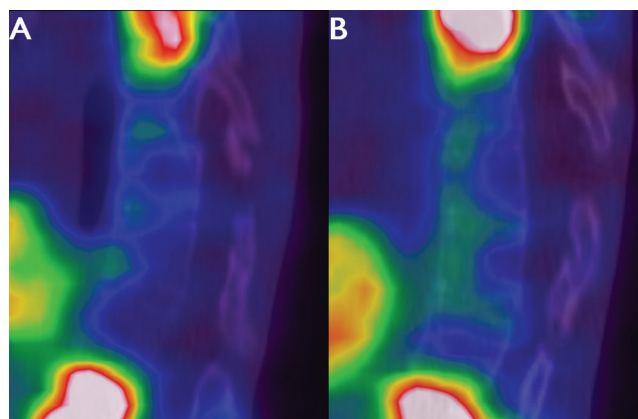


FIGURE 2 Combined fluorothymidine positron-emission tomography and low-dose computed tomography (A) at the end of vinblastine treatment and (B) 20 months after cessation of vinblastine treatment, showing negative fluorothymidine uptake.

activity through endothelium-directed toxicity^{6,12}, a concept that is supported by preclinical data showing antiangiogenic activity with low-dose vinblastine^{14,15}.

Clinical use of vinblastine as single-agent therapy for CNS tumours is based on principles of metronomic low-dose therapy. A phase II study of weekly vinblastine in recurrent low-grade glioma demonstrated very good results, with an excellent toxicity profile in comparison with alternative strategies⁶. It might even be speculated that low-dose vinblastine was not only acting as an antiangiogenic agent, but might also have activated dendritic cells¹⁶. The only negative aspect of the treatment was the absence of an age-appropriate oral formulation and the need for repeated intravenous injections, which necessitated prolonged placement of a V-port in our patient.

Magnetic resonance imaging has become the standard for staging and response evaluation in children with CNS tumours. It shows the structure of tissues, albeit with a limited capability to characterize the metabolic activity of lesions. Functional imaging

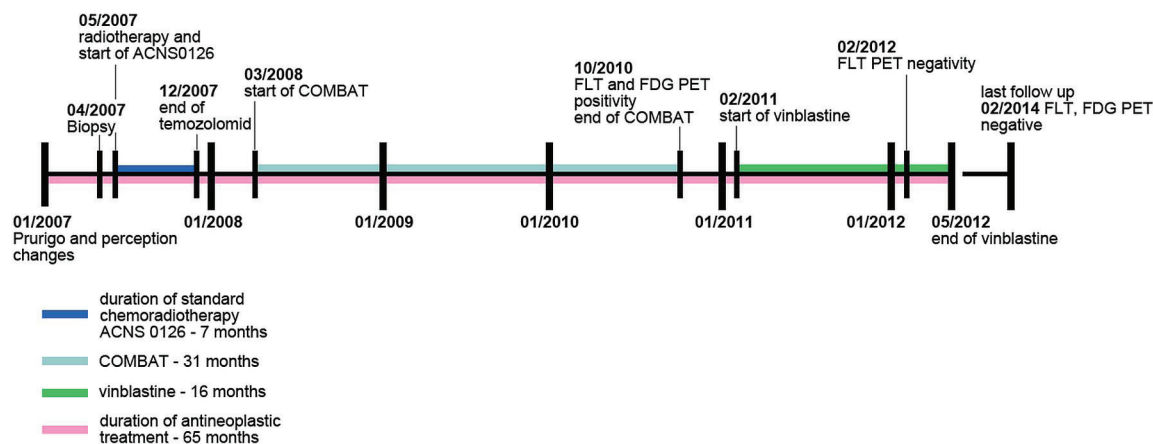


FIGURE 3 Timeline of diagnosis and treatment. ACNS0126 = temozolomide; COMBAT = temozolomide, etoposide, celecoxib, vitamin D, fenofibrate, retinoic acid; FLT = fluorothymidine; FDG = fluorodeoxyglucose; PET = positron-emission tomography.

techniques such as PET and magnetic resonance spectroscopy (MRS) are important for planning surgery in CNS tumours and also for comparing postoperative changes and assessing residual viable tumour. Results of FDG PET have prognostic value and correlate with the histology of CNS tumours at the beginning of treatment¹⁷. However, FDG PET also has its own limitations. It is not specific for malignancy, which can lead to false-positive results. It also has limited sensitivity for detecting lesions smaller than 10 mm¹⁸. Successful use of various PET tracers such as amino acids and nucleosides (¹¹C-methionine, FLT) has been reported in glial tumours¹⁹. The uptake values in FLT PET accurately reflect tumour grade and provide a good estimate of cellular proliferation activity in human gliomas; they were also reported to significantly correlate with the choline:creatinine ratio in tumours assessed by MRS²⁰. (Using MRS, accurate quantitative assessments of the spatial distribution of tissue metabolites such as creatinine, choline, amino acids, nucleotides, lactate, and lipids are possible; however, that method was not available for our studies.) Still, no one cancer signature registers on MRS; rather, certain MRS patterns are seen more often in various malignancies^{21,22}.

Our case study demonstrates the clinical utility of FLT PET imaging, which could serve as a relevant biomarker of tumour proliferation activity and subsequent inhibition induced by treatment. In our case, results from FLT PET were shown to be useful as outcome predictors after chemotherapy²³.

4. CONCLUSIONS

Our case demonstrates very good efficacy for prolonged metronomic vinblastine and the clinical usefulness of functional FLT PET imaging as a marker of tumour proliferation for assessing the biologic activity of a target lesion. The use of FLT PET provided treatment guidance where the residual measurable radiologic abnormality of the target lesion remained unchanged.

5. ACKNOWLEDGMENTS

This work was supported by the European Regional Development Fund (RECAMO: CZ.1.05/2.1.00/03.0101) and the ACIU (LM2011017).

6. CONFLICT OF INTEREST DISCLOSURES

The authors have no financial conflicts of interest to declare.

7. REFERENCES

1. Pizzo PA, Poplack DG. *Principles and Practice of Pediatric Oncology*. Philadelphia, PA: Wolters Kluwer Health/Lippincott Williams and Wilkins; 2011.
2. Pollack IF. The role of surgery in pediatric gliomas. *J Neurooncol* 1999;42:271–88.
3. Cohen KJ, Pollack IF, Zhou T, *et al*. Temozolomide in the treatment of high-grade gliomas in children: a report from the Children's Oncology Group. *Neuro Oncol* 2011;13:317–23.
4. Sterba J, Valik D, Mudry P, *et al*. Combined biodifferentiating and antiangiogenic oral metronomic therapy is feasible and effective in relapsed solid tumors in children: single-center pilot study. *Onkologie* 2006;29:308–13.
5. Zapletalova D, André N, Deak L, *et al*. Metronomic chemotherapy with the COMBAT regimen in advanced pediatric malignancies: a multicenter experience. *Oncology* 2012;82:249–60.
6. Bouffet E, Jakacki R, Goldman S, *et al*. Phase II study of weekly vinblastine in recurrent or refractory pediatric low-grade glioma. *J Clin Oncol* 2012;30:1358–63.
7. Persijn van Meerten EL, Gelderblom H, Bloem JL. RECIST revised: implications for the radiologist. A review article on the modified RECIST guideline. *Eur Radiol* 2010;20:1456–67.
8. Gehan EA, Tefft MC. Will there be resistance to the RECIST (Response Evaluation Criteria in Solid Tumors)? *J Natl Cancer Inst* 2000;92:179–81.
9. Pasquier E, Kieran MW, Sterba J, *et al*. Moving forward with metronomic chemotherapy: meeting report of the 2nd

- International Workshop on Metronomic and Anti-Angiogenic Chemotherapy in Paediatric Oncology. *Transl Oncol* 2011;4:203–11.
10. Brugieres L, Pacquement H, Le Deley MC, *et al.* Single-drug vinblastine as salvage treatment for refractory or relapsed anaplastic large-cell lymphoma: a report from the French Society of Pediatric Oncology. *J Clin Oncol* 2009;27:5056–61.
 11. Bonadonna G, Zucali R, Monfardini S, De Lena M, Uslenghi C. Combination chemotherapy of Hodgkin's disease with adriamycin, bleomycin, vinblastine, and imidazole carboxamide versus MOPP. *Cancer* 1975;36:252–9.
 12. Lafay-Cousin L, Holm S, Qaddoumi I, *et al.* Weekly vinblastine in pediatric low-grade glioma patients with carboplatin allergic reaction. *Cancer* 2005;103:2636–42.
 13. Baranzelli MC, Bouffet E, Quintana E, Portas M, Thyss A, Patte C. Non-seminomatous ovarian germ cell tumours in children. *Eur J Cancer* 2000;36:376–83.
 14. Vacca A, Iurlaro M, Ribatti D, *et al.* Antiangiogenesis is produced by nontoxic doses of vinblastine. *Blood* 1999;94:4143–55.
 15. Klement G, Baruchel S, Rak J, *et al.* Continuous low-dose therapy with vinblastine and VEGF receptor-2 antibody induces sustained tumor regression without overt toxicity. *J Clin Invest* 2000;105:R15–24.
 16. Tanaka H, Matsushima H, Nishibu A, Clausen BE, Takashima A. Dual therapeutic efficacy of vinblastine as a unique chemotherapeutic agent capable of inducing dendritic cell maturation. *Cancer Res* 2009;69:6987–94.
 17. Borgwardt L, Højgaard L, Carstensen H, *et al.* Increased fluorine-18 2-fluoro-2-deoxy-D-glucose (FDG) uptake in childhood CNS tumors is correlated with malignancy grade: a study with FDG positron emission tomography/magnetic resonance imaging coregistration and image fusion. *J Clin Oncol* 2005;23:3030–7.
 18. Kumar R, Shandal V, Shamim SA, Halanaik D, Malhotra A. Clinical applications of PET and PET/CT in pediatric malignancies. *Expert Rev Anticancer Ther* 2010;10:755–68.
 19. Chandrasekaran S, Hollander A, Xu X, *et al.* ¹⁸F-Fluorothymidine-PET imaging of glioblastoma multiforme: effects of radiation therapy on radiotracer uptake and molecular biomarker patterns. *ScientificWorldJournal* 2013;2013:796029.
 20. Kawai N, Shishido H, Yamamoto Y, Nishiyama Y, Tamiya T. Evaluation of brain tumor metabolism with proton magnetic resonance spectroscopy (¹H-MRS) and positron emission tomography (PET) with ¹⁸F-fluorothymidine (FLT) [abstract 1986]. *J Nucl Med* 2012;53(suppl 1):.
 21. Van der Graaf M. *In vivo* magnetic resonance spectroscopy: basic methodology and clinical applications. *Eur Biophys J* 2010;39:527–40.
 22. Torigian DA, Huang SS, Houseni M, Alavi A. Functional imaging of cancer with emphasis on molecular techniques. *CA Cancer J Clin* 2007;57:206–24.
 23. Schwarzenberg J, Czernin J, Cloughesy TF, *et al.* 3'-deoxy-3'-¹⁸F-fluorothymidine PET and MRI for early survival predictions in patients with recurrent malignant glioma treated with bevacizumab. *J Nucl Med* 2012;53:29–36.
- Correspondence to:** Jaroslav Sterba, Department of Pediatric Oncology, University Hospital Brno, Cernopolni 9, Brno, 625 00, Czech Republic.
E-mail: jsterb@fnbrno.cz
- * Department of Pharmacology, Masaryk University School of Medicine, Brno, Czech Republic.
† Regional Center for Applied Molecular Oncology, Brno, Czech Republic.
‡ Department of Pediatric Oncology, University Hospital Brno, Brno, Czech Republic.
§ Department of Nuclear Medicine, Masaryk Memorial Cancer Institute, Brno, Czech Republic.
|| Department of Pathology, University Hospital Brno, Brno, Czech Republic.
Department of Pediatric Neurology, University Hospital Brno, Brno, Czech Republic.