

Azacitidine-induced pyoderma gangrenosum at injection sites in a patient with myelodysplastic syndrome

C. Roy MD,*† J.P. Adam PharmD,‡§ F. Morin MD,*|| É. Lemieux-Blanchard MD,†§ S. Doucet MD,†§
D. Friedmann MD,|| A. Belisle MD,‡# and D. Charpentier MD†§

ABSTRACT

Pyoderma gangrenosum (PG) is a rare neutrophilic dermatosis characterized by painful necrotic ulceration affecting preferentially the lower extremities. Diagnosis is challenging, and a thorough workup (including biopsy) is required. In this case report, we describe a 67-year-old patient with a diagnosis of myelodysplastic syndrome (MDS) who developed fever and PG two days after the first cycle of subcutaneous azacitidine (Vidaza; Celgene Corporation, Summit, NJ, USA). On physical examination, the patient had four erythematous plaques at sites of subcutaneous injections of azacitidine on the arms, as well as three other plaques in proximity. A skin biopsy demonstrated a dense neutrophilic interstitial infiltrate in the dermis. After the diagnosis of PG, prednisone 1 mg/kg was started and the fever subsided rapidly. This was followed by the resolution of the cutaneous lesions. Changing the route of administration of azacitidine from subcutaneous to intravenous and adding a daily dose of prednisone during the treatment allowed the patient to receive a total of 10 cycles of azacitidine. This is the second case reported in the literature. Because azacitidine is frequently used in MDS and acute myeloid leukemia, clinicians should be aware of this rare cutaneous adverse event. Our approach can be used to avoid the recurrence of PG when continuing azacitidine treatment.

Key Words Azacitidine, pyoderma gangrenosum, neutrophilic dermatosis, myelodysplastic syndrome

Curr Oncol. 2018 Feb;25(1):e103-e105

www.current-oncology.com

INTRODUCTION

Azacitidine is a DNA methyltransferase inhibitor which has been shown to prolong progression-free survival and overall survival in patients with myelodysplastic syndrome (MDS) with an intermediate-2 or high risk according to the International Prognostic Scoring System (IPSS) compared with a conventional care regimen¹. Following subcutaneous administration, cutaneous reactions such as local erythema can be observed at the site of injection in 85 to 97% of patients, but these rarely limit administration of the treatment². Here, we report the case of a patient with MDS who developed pyoderma gangrenosum (PG) at the sites of subcutaneous injections of azacitidine. This is a rare adverse effect with only one previous case reported in the literature.

CASE DESCRIPTION

A 67-year-old male was referred to our centre for thrombocytopenia and anemia. The patient had a past medical

history of hypertension, hypothyroidism, pulmonary embolism, and recurrent deep venous thrombosis. His medications were warfarin, atenolol, levothyroxine, and pantoprazole. His blood count showed a hemoglobin of 95 g/L, a platelet count of $139 \times 10^9/L$, and a neutrophil count of $1.29 \times 10^9/L$. A bone marrow aspiration and biopsy were performed and showed 8% and 16% blasts, respectively, with a complex karyotype. A diagnostic of refractory anemia with excess blast-2 (RAEB-2) MDS was made according to the World Health Organisation (WHO) classification and was further classified as high-risk according to the revised IPSS (IPSS-R). The patient was then started on subcutaneous azacitidine at a standard dose of 75 mg/m² given in two injections daily, for seven consecutive days every four weeks.

The patient developed a fever of 38.5°C and erythematous plaques at four sites of subcutaneous injections of azacitidine on the arms as well as three other plaques in proximity. His blood count showed a deterioration of his anemia and thrombocytopenia with a hemoglobin and platelet count of 75 g/L and $44 \times 10^9/L$, respectively. His

Correspondence to: Claudie Roy, Hôpital Maisonneuve-Rosemont, Department of Internal Medicine, 5305 boul. de l'Assomption, Montréal, Québec H1T 2M4
E-mail: claudie.roy.1@umontreal.ca ■ DOI: <https://doi.org/10.3747/co.25.3779>

neutrophil count remained normal at $2.75 \times 10^9/L$. The patient was given ertapenem followed by meropenem for an initial suspicion of cellulitis. Despite a broad-spectrum antibacterial treatment, the lesions progressed to infiltrated painful erythematous plaques with superimposed pustules. Over a few days, purplish plaques with a central flaccid bullae and a maximal diameter of 5 cm (Figure 1) were observed and subsequently became erosive. No other cutaneous lesions were noted elsewhere on the body.

A skin biopsy was performed and demonstrated a dense, diffuse neutrophilic interstitial infiltrate in the dermis (Figure 2). Both the microorganism stains and tissue culture were negative. A magnetic resonance imaging of the upper arms revealed no abscess and no involvement of the muscle or fascia. There were no other infectious foci on the gallium scan or on the computerized tomography of the thorax and abdomen. Since the thrombocytopenia persisted more than two weeks after the last azacitidine injection, hemopathic fever due to transformation to acute myeloid leukemia (AML) was ruled out by a bone marrow aspiration, which showed only 6% blasts. Considering these results, a diagnosis of PG was made. Prednisone 1 mg/kg po daily and clobetasol cream on the lesions were initiated. The fever subsided rapidly, in less than 24 hours, and the cutaneous lesions resorbed within a few days.

The next cycle of azacitidine was delayed because of an episode of deep venous thrombosis, and a therapeutic dose of subcutaneous enoxaparin was started. The patient had previously been on warfarin but the drug had been withheld because of thrombocytopenia after the first cycle. The decision was made to resume azacitidine treatment at half of the initial dose with an intravenous administration in 100 mL of NaCl 0.9% over 15 minutes for seven days. Oral prednisone was continued to reduce the risk of recurrence of PG and he began his second cycle on day 56 with a good tolerance.

However, on day 86, only a few days after the prednisone was tapered, he presented again with a fever of 40°C. There was no recurrence of the PG or evidence of

infectious disease. The fever resolved promptly with IV methylprednisolone and prednisone was restarted at 35 mg daily.

On his third cycle, azacitidine was increased to full dose. Prednisone was then slowly lowered to 10 mg daily over the next months. He completed a total of 10 cycles of chemotherapy without any recurrence of PG. With this treatment, he achieved a stable response and was considered for an allogeneic stem cell transplant research protocol. Unfortunately, fourteen months after the initial diagnosis, the fever reappeared while the patient was still on oral prednisone. He had an elevated peripheral blast count and was diagnosed with a transformation to AML. Subcutaneous cytarabine was started as a palliative treatment, and the patient died of cerebral haemorrhage after one cycle.

DISCUSSION

Pyoderma gangrenosum is a rare neutrophilic dermatosis (ND) characterized by painful, necrotic ulceration preferentially affecting the lower extremities³. Half of the patients have associated systemic diseases, including myeloproliferative disorders such as MDS and AML⁴. The presence of ND in these patients is associated with transformation to AML, poor prognosis, and shortened survival⁴.

In our case, the most likely cause of PG was considered to be azacitidine. First, the temporal relationship between the introduction of the drug and the development of lesions at the injection sites is suggestive of an adverse drug reaction. Second, alternative causes of PG were considered less likely. Transformation to AML, infection, contamination of the drug vial, and inadequate injection technique were ruled out. However, a paraneoplastic phenomenon secondary to MDS cannot be completely excluded. Nonetheless, it was considered less likely because of the localization of the lesions at the sites of injection of azacitidine. An additional contribution of a pathergy phenomenon at the sites of subcutaneous injection is possible but is unlikely to be

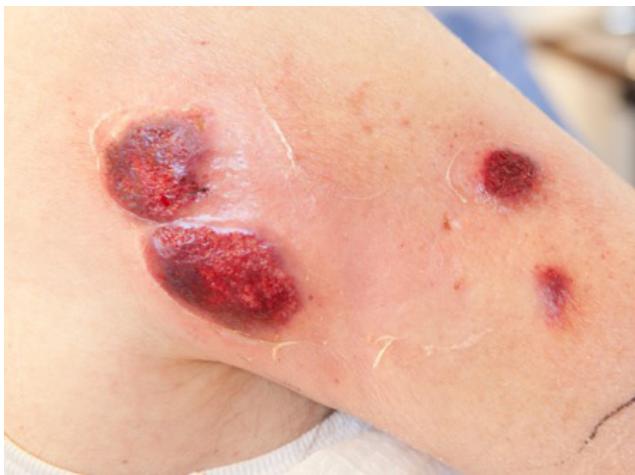

FIGURE 1 Cutaneous lesions at the site of azacitidine injection demonstrating purplish plaques with a central flaccid bulla and a maximal diameter of five centimetres.

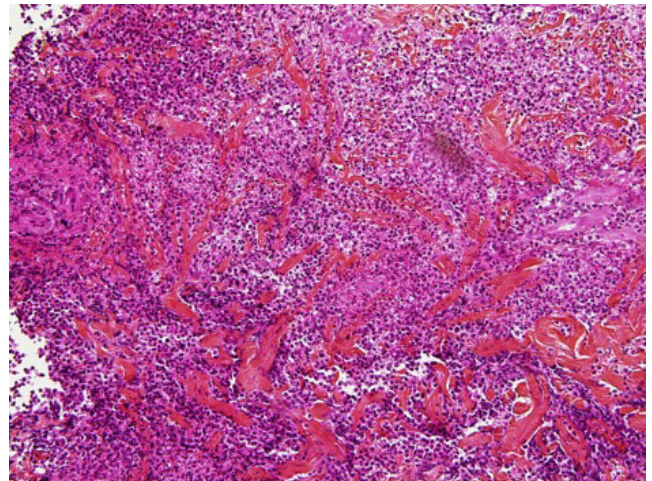


FIGURE 2 Biopsy of the cutaneous lesion at the site of azacitidine injection showing a dense, diffuse neutrophilic interstitial infiltrate in the dermis compatible with pyoderma gangrenosum.

the sole explanation for development of PG. A skin pathergy test was not performed. However, the patient received subcutaneous injections of enoxaparin and cytarabine without recurrence of PG. Also, patients with PG secondary to paraneoplastic phenomena tend to have an atypical presentation with vesiculobullous lesions or ulcers appearing at unusual sites such as the hands. Sweet syndrome, another ND, has been associated with azacitidine and was reported in eight cases in the literature. However, it was considered less likely than PG because of the morphology and the distribution of the lesions. Also, the occurrence of lesions at sites of injection suggested a pathergy phenomenon which is not characteristic of sweet syndrome. The diffuse and confluent dermal neutrophilic infiltrate seen in our patient's biopsy favoured PG. Sweet syndrome usually presents with a less confluent interstitial neutrophilic infiltrate and papillary dermis edema.

Only one case of PG secondary to azacitidine has been previously described in the literature. A 66-year-old female with a very high risk MDS, during her second cycle of azacitidine, developed violaceous lesions at injection sites on the arms but also on her lips and nose⁵. She responded to a treatment of colchicine and prednisone. The lesions relapsed upon re-challenge with subcutaneous azacitidine, but she was able to complete five cycles with concurrent treatment with prednisone and colchicine. Likewise, in our case, the patient was able to complete his azacitidine treatment with a maintenance dose of oral prednisone to prevent recurrence of PG. Furthermore, azacitidine was reintroduced by IV route because the patient refused to receive sub-cutaneous injections of the drug given the severity of the reaction, thereby limiting pathergy. Because few therapeutic options are available in MDS, it is desirable to manage the adverse reactions.

CONCLUSIONS

We report a second case of PG triggered by azacitidine in a patient with MDS. The interest of this case lies in the ability of the patient to tolerate his azacitidine treatment with IV administration and oral prednisone without recurrence of

PG. Because the diagnosis is challenging, clinicians should be aware of this rare cutaneous adverse reaction and we propose a potential approach to avoid the recurrence of PG.

CONFLICT OF INTEREST DISCLOSURES

We have read and understood *Current Oncology's* policy on disclosing conflicts of interest and declare the following interests: ELB has received fees as an advisory committee member for Celgene and speaker fees from Amgen and Jansens. SD has received consultant fees from Celgene. The other authors report no conflict of interest.

AUTHOR AFFILIATIONS

*Faculté de médecine, Université de Montréal, Montréal, Québec, Canada; [†]Département de médecine interne, Service d'hématologie-oncologie et banque de sang, Centre hospitalier de l'Université de Montréal, Montréal, Québec, Canada; [‡]Département de pharmacie, Centre hospitalier de l'Université de Montréal, Montréal, Québec, Canada; [§]Centre de recherche du centre hospitalier de l'Université de Montréal, Montréal, Québec, Canada; ^{||}Département de dermatologie, Centre hospitalier de l'Université de Montréal, Montréal, Québec, Canada; and [#]Département de pathologie, Centre hospitalier de l'Université de Montréal, Montréal, Québec, Canada.

REFERENCES

1. Fenaux P, Mufti GJ, Hellstrom-Lindberg E, *et al.* Efficacy of azacitidine compared with that of conventional care regimens in the treatment of higher-risk myelodysplastic syndromes: a randomised, open-label, phase III study. *Lancet Oncol* 2009;10(3):223–32.
2. Santini V, Fenaux P, Mufti GJ, *et al.* Management and supportive care measures for adverse events in patients with myelodysplastic syndromes treated with azacitidine. *Eur J Haematol* 2010;85(2):130–8.
3. Patel F, Fitzmaurice S, Duong C, *et al.* Effective strategies for the management of pyoderma gangrenosum: a comprehensive review. *Acta Derm Venereol* 2015;95(5):525–31.
4. Jacobs P, Palmer S, Gordon-Smith EC. Pyoderma gangrenosum in myelodysplasia and acute leukaemia. *Postgrad Med J* 1985;61(718):689–94.
5. Tseng E, Alhusayen R, Sade S, Buckstein R, Prica A. Pyoderma gangrenosum secondary to azacitidine in myelodysplastic syndrome. *Br J Haem* 2015;169(4):461.