

Review

Per Oral Pyloromyotomy for Gastroparesis: A Systematic Review of the Current Literature and Future Recommendations

Luis O. Chavez ¹, Gian Galura ¹, Alejandro Robles ¹, Marco A. Bustamante-Bernal ²
and Richard McCallum ^{2,*}

¹ Department of Internal Medicine, Texas Tech University Health Sciences Center, El Paso, TX 79430, USA; Luis.O.Chavez@ttuhsc.edu (L.O.C.); Gian.Galura@ttuhsc.edu (G.G.); Alejandro.Robles@ttuhsc.edu (A.R.)

² Division of Gastroenterology, Texas Tech University Health Sciences Center, El Paso, TX 79430, USA; Marco.A.Bustamante@ttuhsc.edu

* Correspondence: Richard.Mccallum@ttuhsc.edu; Tel.: +1-(915)-215-5191; Fax: +1-(915)-545-6634

Received: 8 October 2020; Accepted: 19 October 2020; Published: 26 October 2020



Abstract: Background: Gastric per oral endoscopic myotomy (GPOEM) was developed as a therapeutic option for gastroparesis after the pylorus was identified as a key target for gastroparesis management. This study includes a systematic literature review of studies in which GPOEM was utilized as therapy for gastroparesis. Methods: A literature search was conducted in three databases (MEDLINE, Scopus and Embase) of articles that included the keywords “GPOEM”, “Gastric per oral endoscopy myotomy” or “per oral pyloromyotomy” and “Gastroparesis” in the abstract or title. The search covered articles published until 29 February 2020. Results: A total of 139 articles were identified. Only 15 articles met the final inclusion criteria and were retrieved for qualitative data synthesis. Conclusion: GPOEM for gastroparesis is shown to have a high success rate among the studies but data interpretations are limited because of small sample sizes and short follow-up. Subjective and objective data prior to and post-GPOEM will be mandatory to establish credibility. The procedure is technically feasible and safe based on the limited studies available.

Keywords: G-POEM; POP; gastric per oral endoscopic myotomy; per oral pyloromyotomy; gastroparesis

1. Introduction

Gastroparesis is a condition of delayed gastric emptying with complex pathophysiology characterized by gastric motility impairment in the absence of mechanical obstruction. The loss of interstitial cells of Cajal (ICC) in the smooth muscle of the gastric body, antrum, and the pyloric sphincter, are major findings in patients with this condition. Other factors that contribute to delay in gastric emptying are autonomic dysfunction, decreased fundus accommodation and antral hypomotility. Recent research has shown that the pylorus is crucial for effective gastric emptying and its dysfunction plays a major role in gastroparesis [1,2].

Pyloric dysfunction has been reported in the settings of impaired relaxation or vigorous contractions (pylorospasm). The pyloric tone determines the outlet phase of gastric motility and anatomical factors such as diameter, cross-sectional area, and compliance are also involved in gastric emptying. Any disruption of the pyloric function may affect gastric emptying [3–5]. Pyloric relaxation is mediated extrinsically by the vagus nerve and intrinsically by nitric oxide release. In post-surgical gastroparesis, injury to the vagus nerve decreases pyloric relaxation. In patients with diabetic gastroparesis, pylorospasm is an important component of the pathophysiology [6,7]. Recent data from our research team have shown that the pyloric smooth muscle in severe gastroparesis patients has a depletion of ICC to a greater degree than antral smooth muscle and, in addition, interstitial fibrosis

is present [8,9]. Both findings help explain the poor compliance and loss of relaxation of the pyloric sphincter in gastroparesis.

There are therapeutic options targeting the pylorus in the management of gastroparesis. Intrapyloric botulinum injection, surgical pyloroplasty and transpyloric stenting have been utilized to try to improve symptoms and gastric emptying time. Since positive outcomes were demonstrated with surgical pyloroplasty, per oral endoscopic pyloromyotomy (POP), also known as gastric per oral endoscopic myotomy (GPOEM), was developed as a treatment option for gastroparesis [8–10].

The background for the technique came from the “per oral endoscopy myotomy” (POEM) used in achalasia. The procedure is based on dissecting the pyloric smooth muscle, entering the submucosal space of the distal antrum. Kashab MA et al. successfully performed the first case in a patient in 2013 at John Hopkins Hospital [11,12]. In this first procedure, an initial mucosal incision was performed on the anterior gastric wall; however, due to difficult angulation, a better entrance was obtained from the posterior gastric wall 5 cm pre-pylorus. The endoscope was advanced and tunneled through the submucosal space by dissecting the submucosal fibers with a triangular tip knife. The tunnel extended 5 mm into the duodenal bulb. Pyloric myotomy was then performed, starting 2 cm proximal to the pylorus. The mucosal incision was then closed with endoscopic clips [11].

While there is no standardized technique for the procedure, there are fundamental steps developed based on the POEM experience and additional considerations are incorporated. The initial approach may be more challenging than POEM due to the curvature of the stomach, and the pyloric ring is harder to identify than the lower esophageal sphincter. The mucosal incision site is not constant among endoscopists; however, after achieving the incision, the sub-mucosal tunnelization is the next goal. The depth of pyloric myotomy also varies; initially, a full-thickness dissection was performed, and now, studies have shown that a safer approach with equal outcomes may be selective circular myotomy to decrease the risk of perforation. Another key aspect of GPOEM is that it must extend into the duodenum—perhaps an estimated 1 cm—to produce efficacy (Figure 1 illustrates the procedure).

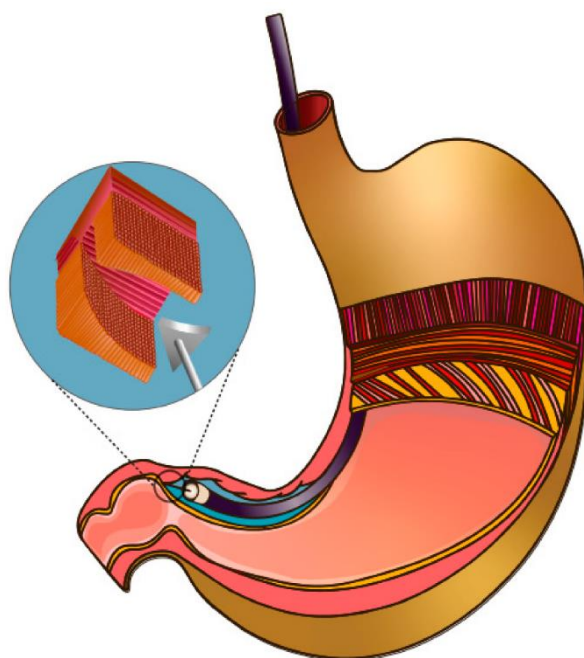


Figure 1. Illustration of the Gastric per oral endoscopic myotomy (GPOEM) procedure.

The procedure risks include perforation, pneumoperitoneum, infection and bleeding. However, since it is a less invasive procedure than surgical pyloroplasty, the procedure has a safer profile. Some considerations to prevent complications are placing the patient on a clear liquid diet for 48–72 h prior to and after the procedure, antibiotic administration (prophylactically and in some cases during the endoscopy),

adequate irrigation to the mucosal incision site and careful placement of the endoscopic clips to achieve successful closure and no bleeding.

We performed a systematic literature review of studies in which GPOEM is used as therapy for gastroparesis. The purpose of this systematic literature review was to summarize the current state of knowledge regarding the use of GPOEM including the etiology of gastroparesis in which the procedure is used, the outcomes and efficacy, technical aspects of the procedure, adverse events and follow-up timing described in the studies.

2. Methodology

An independent search of the medical literature was performed by two authors (LC and GG) in three databases (MEDLINE, Scopus and Embase) of articles that included the keywords “GPOEM”, “Gastric per oral endoscopy myotomy” or “per oral pyloromyotomy” and “Gastroparesis” in the abstract or title. The search covered articles published until 29 February 2020. All types of articles (reviews, meta-analysis, randomized controlled trials, case series and case reports) were screened. Abstracts were read for relevant content identification and selected as eligible for further review.

Inclusion criteria for further review were articles (retrospective/prospective studies) that included patients with gastroparesis treated with GPOEM. Exclusion criteria for data synthesis were preclinical studies on animals, review articles, and publications in a different language than English or Spanish. After an independent search from two authors (LC and GG) and elimination of duplicate studies, a third author (MB) reviewed the selected articles and resolved any controversies regarding the eligibility of a study for further review based on the relevance of content material. Additionally, articles were excluded for insufficient data or lack of relevance for the purpose of our review.

The data synthesis of each study was performed after screening and retrieving the retrospective and prospective studies. The studies were divided by type, and information was gathered from each article based on a predetermined form that included the year of publication, authors, study design, number of patients, gastroparesis and refractory gastroparesis definition, etiology of gastroparesis, procedure details, outcome measures, outcome measurement tools (gastroparesis cardinal symptom index, gastric emptying study), and adverse events. Finally, the data from each section was summarized and entered in a table form. No statistical analysis was performed.

Figure 2 shows a flowchart for study selection following the Preferred Reporting Items for Systematic reviews and Meta-Analyses (PRISMA) recommendations.

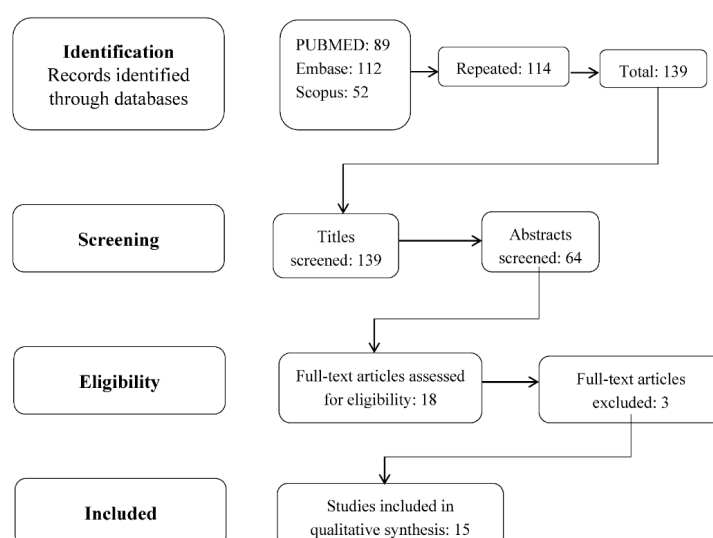


Figure 2. Flowchart for study selection following the Preferred Reporting Items for Systematic reviews and Meta-Analyses (PRISMA) recommendations.

3. Results and Data Synthesis

A total of 139 articles were identified using the three databases after duplicates were removed. Of those identified, 64 articles were screened and 18 contained relevant information for the review purpose. Of those 18 articles with relevant information, three articles were excluded due to lack of clarity in the data synthesis. Only 15 articles met the final inclusion criteria and were retrieved for qualitative data synthesis. The types of studies included were 11 retrospective, 2 prospective, 1 case series and 1 single-center cohort study. A total of 460 patients from all studies retrieved had GPOEM procedures performed for gastroparesis (Table 1).

Table 1. Study types and # of patients included in each.

Study	Type	# Patients
Kashab 2013 [11]	Retrospective	30
Malik 2018 [12]	Case Series	13
Gonzalez 2017 [13]	Retrospective	29
Xue 2017 [14]	Single-center cohort	14
Rodriguez 2017 [15]	Prospective	100
Kahaleh 2018 [16]	Retrospective	33
Shlomovitz 2015 [17]	Retrospective	7
Dacha 2017 [18]	Retrospective	16
Allemang 2017 [19]	Retrospective	57
Jacques 2019 [20]	Prospective	20
Mekaroonkamol 2019 [21]	Retrospective	40
Mekaroonkamol 2018 [22]	Retrospective	30
Hedberg 2019 [23]	Retrospective	17
Strong 2019 [24]	Retrospective	38
Xu 2018 [25]	Retrospective single center	16

The most common etiology of gastroparesis was idiopathic (40%) followed by diabetes (30%) and post-surgical gastroparesis (24%) other causes (6%) were autoimmune, and post-infectious [11–22].

The most common outcome measure used among the studies was the gastroparesis cardinal symptoms index (GCSI) followed by gastric emptying scintigraphy (GES). Malik et al. [12] also used the Patient Assessment of Gastrointestinal Symptoms (PAGI-SYM) and Endoscopic functional luminal imaging probe (EndoFLIP); while Dacha and Mekaroonkamol additionally utilized the standardized short form 36 (SF36) to assess the quality of life changes in these patients [18,21,22]. All studies reported efficacies of more than 70% with a significant clinical response rate based on symptom improvement. Nausea and vomiting were the most common symptoms improved in most studies and the follow-up ranged from 3 to 18 months (Table 2).

Based on GCSI score improvement, Gonzalez et al. [13] reported an efficacy of 69% at 6 months while Jacques et al. [20] reported 100% using the same outcome measure with a follow up of 3 months. The most common validated tool utilized was the GCSI scoring system, which includes post-prandial fullness, nausea/vomiting and bloating. Gastric emptying scintigraphy (GES) was also used to evaluate the efficacy of the procedure despite the fact that gastric emptying results have not been well correlated with gastroparesis symptoms.

In the study from Rodriguez et al. [26], the overall improvement of GCSI score was from 3.82 +/- 0.86 to 2.54 +/- 1.2 ($p < 0.001$) demonstrating improvement in all subscales (post-prandial fullness, nausea/vomiting and bloating) when comparing preoperatively GCCSI and post GPOEM procedure GCSI of 100 patients after 3 months. In the study by Malik et al. (which included 13 patients with gastroparesis) 11 completed a

post-GPOEM follow-up symptom assessment questionnaire and 8 reported symptomatic improvement, while two patients reported worsening of abdominal distention and pain. Follow up ranged from 3 months in three studies [12,20,26] up to 18 months in one study [21].

Table 2. Etiologies, GPOEM efficacy and symptom resolution.

Study	Etiologies	Outcome Measures	Efficacy	Symptom Resolution	Follow up (Months)
Kashab [11]	11 Diabetic 12 post-surgical 7 idiopathic	GES Gastroparesis symptoms	26/30 pts	Nausea 29/30 Vomiting 19/30 Abdominal pain 22/30 Weight improvement 28/30	5.5
Malik [12]	1 Diabetic 8 Post-surgical 4 idiopathic	GES PAGI-SYMEndoFLIP	8/13 pts	Vomiting 4/13 Appetite improvement 4/13	3
Gonzalez [13]	7 Diabetic 5 post-surgical 15 idiopathic 2 other	GES GCSI	23/29 pts	All GCSI	6
Rodriguez [15]	12 Diabetic 8 post-surgical 27 idiopathic	GES GCSI	Not documented	All GCSI	3
Kahaleh [16]	7 Diabetic 12 post-surgical 13 idiopathic 1 other	GES GCSI	28/33 pts	All GCSI	11.5
Schlomovitz [17]	2 post-surgical 4 idiopathic 1 other	GES Gastroparesis Symptoms	6/7 pts	Nausea 7/7	6.5
Dacha [18]	9 Diabetic 1 post-surgical 5 idiopathic 1 post-infectious	GES GCSI SF36	13/16 pts	nausea and vomiting and early satiety significantly improved but not bloating	12
Jacques [20]	10 diabetic 1 post-surgical 4 idiopathic 5 other	GES GCSI	20/20 pts	All GCSI	3
Mekaroonkamol [22]	12 Diabetic 5 post-surgical 12 idiopathic 1 post-infectious	GES GCSISF36	24/30 pts	Nausea and early satiety	18

Characteristics of the procedures were described in six studies, including GPOEM duration, myotomy length, length of hospital stay and adverse events (Table 3). GPOEM technique varied among endoscopists; the mean duration of the procedure ranged from 47 up to 255 min [13,16].

The reported adverse events were pneumoperitoneum/perforation, pulmonary embolism, GI bleeding, peri-gastric abscess, pre-pyloric stricture and ulcer. Only one study, which included 20 patients, reported a 20% incidence of perforation [20]. Some recommendations that should be taken into consideration when carrying out GPOEM is to perform a selective circular pyloric myotomy and to minimize extension into the duodenum to decrease the risk of perforation. Pneumoperitoneum was commonly reported due to the nature of the procedure, which includes tunnelization at the pylorus. Gonzalez et al reported 5/47 patients with pneumoperitoneum. Management is usually conservative or needle decompression may be attempted when compromising the hemodynamics. Bleeding was a reported adverse event (Kahaleh 3%, Shlomovitz 14%, Gonzalez 6.8%), which can present as an immediate—procedural related—or secondary to ulcers (pre-pyloric) [13,16,17]. Patients with bleeding were controlled medically (majority with proton pump inhibitors) and endoscopically through the placement of “clips” without significant morbidity or mortality.

Table 3. Procedure description and adverse events.

Study	Gpoem Duration (min)	Myotomy Length (cm)	Hospital Stay (Days)	Adverse Events
Kashab [11]	72 ± 42	2.6 ± 2.3	3.3	1 pneumoperitoneum 1 pre-pyloric ulcer
Malik [12]	119 ± 23	3.5 ± 0.8	2.5 ± 1.4	1 pulmonary embolism
Gonzalez [13]	47	not documented	not documented	5 pneumoperitoneum 2 bleeding 1 perigastric abscess 1 pre-pyloric stricture
Kahaleh [16]	77.6 (37–255)	3.34	5.4	1 bleeding 1 ulcer
Schlomovitz [17]	90–120	not documented	not documented	1 pre-pyloric ulcer 1 bleeding
Mekaroonkamol [22]	48.3 ± 16.5	not documented	2.4 ± 1	1 pneumoperitoneum

4. Discussion

GPOEM of the pylorus for gastroparesis is shown to have a high technical success rate among the included studies. Even though most studies reported promising results, it is important to take into consideration that the inclusion criteria varied among the 15 studies and great heterogeneity existed when comparing outcomes.

The outcome measurements across the different studies vary widely. To measure clinical success, a combination of objective and subjective measurements was used. Scoring systems such as GCSI, PAGY-SYM and SF36 report different symptomatological improvements. Some studies use gastric emptying scintigraphy as part of the measurements to determine clinical success; however, this tool may not always correlate with symptomatology. Despite the high technical success reported, it is worth noting that the majority of the procedures were performed by a skilled proceduralist with previous POEM experience.

The effectiveness and safety of the procedure still need to be further assessed. There are no current randomized clinical trials evaluating GPOEM for gastroparesis. There are only a small number of studies in the current literature including both post-procedure GES and symptomatic improvement assessment. Most of the studies in this literature review are retrospective studies. The safety of GPOEM also needs further investigation. Despite the low incidence of complications reported in most studies, the number of studies included in this literature review is relatively small. The reported complications range from 1–20% but follow-ups were relatively short in most studies.

Important limitations of this review are the lack of randomized clinical trials, the relatively small number of studies included, the major differences in outcome measures used throughout the studies and the fact that most of the study designs are retrospective. In addition, the sample size in most studies of our literature review was too small and there were relatively short follow-ups as stated above.

5. Future Recommendations and Conclusions

Future studies should emphasize patient follow-up for longer periods and we suggest at least 1 year after the intervention to demonstrate long-lasting efficacy. The investigators should evaluate subjective parameters with the use of questionnaires including GCSI, SF36, PAGA-SYM. Objective outcomes can be assessed with a 4-h GES using the “gold standard” scintigraphic meal as well as EndoFLIP. Other important parameters to follow in addition to the standard are the quality of life, rate of hospitalizations, employment status, and overall ranking of improvement.

The EndoFLIP device has been recently utilized to assess the original POEM technique for achalasia. This device measures pressure, compliance, cross-sectional area and distensibility of the gastrointestinal sphincters. We suggest that the application of EndoFLIP should become universal in all patients with gastroparesis pre- and post-intervention. Assessing the pyloric sphincter profile of compliance and diameter prior to GPOEM will help identify the best candidates for the procedure. The use

of EndoFLIP after the procedure will objectively evaluate the success of the intervention and correlate this with symptom improvement and acceleration of gastric emptying.

Some of the ongoing trials listed in the US National Institutes of Health clinical trials registry (clinicaltrials.gov) are assessing long term results, with a larger population, randomized and prospective (Clinical trial.gov identifiers NCT04024709, NCT03876288, NCT033560667, NCT02732821). This future research will provide important information that is not available at this stage of GPOEM development.

Author Contributions: Conceptualization, L.O.C. and R.M.; Methodology, L.O.C. and A.R.; Investigation/data curation, L.O.C. and G.G. and M.A.B.-B.; Writing-reviewing and editing, L.C. and A.R. and R.M. All authors have read and agreed to the published version of the manuscript.

Funding: This research received no external funding.

Conflicts of Interest: The authors declare no conflict of interest.

References

- Oh, J.H.; Pasricha, P.J. Recent advances in the pathophysiology and treatment of gastroparesis. *J. Neurogastroenterol. Motil.* **2013**, *19*, 18–24. [[CrossRef](#)] [[PubMed](#)]
- Avalos, D.J.; Sarosiek, I.; Loganathan, P.; McCallum, R.W. Diabetic gastroparesis: Current challenges and future prospects. *Clin. Exp. Gastroenterol.* **2019**, *29*, 127–137. [[CrossRef](#)] [[PubMed](#)]
- Huzinga, J.D.; Lammers, W.J. Gut peristalsis is governed by a multitude of cooperating mechanisms. *Am. J. Physiol. Gastrointest. Liver Physiol.* **2009**, *296*, G1–G8. [[CrossRef](#)] [[PubMed](#)]
- Malik, Z.; Sankineni, A.; Parkman, H.P. Assessing pyloric sphincter pathophysiology using EndoFLIP in patients with gastroparesis. *Neurogastroenterol. Motil.* **2015**, *27*, 524–531. [[CrossRef](#)]
- Snape, W.J.; Lin, M.S.; Agarwal, N.; Shaw, R.E. Evaluation of the pylorus with concurrent intraluminal pressure and EndoFLIP in patients with nausea and vomiting. *Neurogastroenterol. Motil.* **2016**, *28*, 758–764. [[CrossRef](#)]
- Rivera, L.R.; Poole, D.P.; Thacker, M.; Furness, J.B. The involvement of nitric oxide synthase neurons in enteric neuropathies. *Neurogastroenterol. Motil.* **2011**, *23*, 980–988. [[CrossRef](#)]
- Mearin, F.; Camilleri, M.; Malagelada, J.R. Pyloric dysfunction in diabetics with recurrent nausea and vomiting. *Gastroenterology* **1986**, *90*, 1919–1925. [[CrossRef](#)]
- Davis, B.R.; Sarosiek, I.; Bashashati, M.; Alvarado, B.; McCallum, R.W. The Long-Term Efficacy and Safety of Pyloroplasty Combined with Gastric Electrical Stimulation Therapy in Gastroparesis. *J. Gastrointest. Surg.* **2017**, *21*, 222–227. [[CrossRef](#)]
- Sarosiek, I.; Forster, J.; Lin, Z.; Cherry, S.; Sarosiek, J.; McCallum, R. The addition of pyloroplasty as a new surgical approach to enhance effectiveness of gastric electrical stimulation therapy in patients with gastroparesis. *Neurogastroenterol. Motil.* **2013**, *25*, 134–e80. [[CrossRef](#)]
- Arts, J.; Holvoet, L.; Caenepeel, P.; Verbeke, K.; Janssens, J.; Tack, J. Influence of intrapyloric botulinum toxin injection on gastric emptying and meal-related symptoms in gastroparesis patients. *Aliment. Pharmacol. Ther.* **2006**, *24*, 661–667. [[CrossRef](#)]
- Khashab, M.A.; Stein, E.; Clarke, J.O.; Saxena, P.; Kumbhari, V.; Chander Roland, B.; Kalloo, A.N.; Stavropoulos, S.; Pasricha, P.; Inoue, H. Gastric per oral endoscopic myotomy for refractory gastroparesis; First human endoscopic pyloromyotomy (with video). *Gastrointest. Endosc.* **2013**, *78*, 764–768. [[CrossRef](#)] [[PubMed](#)]
- Malik, Z.; Kataria, R.; Modayil, R.; Ehrlich, A.C.; Shcey, R.; Parkman, H.P.; Stavropoulos, S.N. Gastric Per Oral Endoscopic Myotomy (G-POEM) for the treatment of Refractory Gastroparesis: Early Experience. *Dig. Dis. Sci.* **2018**, *63*, 2405–2412. [[CrossRef](#)] [[PubMed](#)]
- Gonzalez, J.M.; Benezech, A.; Vitton, V.; Barthet, M. G-POEM with antro-pyloromyotomy for the treatment of refractory gastroparesis: Mid-term follow-up and factors predicting outcome. *Aliment Pharmacol. Ther.* **2017**, *46*, 364–370. [[CrossRef](#)]
- Xue, H.B.; Fan, H.Z.; Meng, X.M.; Cristofaro, S.; Mekaroonkamol, P.; Dacha, S.; Li, L.Y.; Fu, X.L.; Zhan, S.H.; Cai, Q. Fluoroscopy-guided gastric peroral endoscopic pyloromyotomy (G-POEM): A more reliable and efficient method for treatment of refractory gastroparesis. *Surg. Endosc.* **2017**, *31*, 4617–4624. [[CrossRef](#)] [[PubMed](#)]

15. Rodriguez, J.H.; Haskins, I.N.; Strong, A.T.; Plescia, R.L.; Allemang, M.T.; Butler, R.S.; Cline, M.S.; El-Hayek, K.; Ponsky, J.L.; Kroh, M.D. Per oral endoscopic pyloromyotomy for refractory gastroparesis: Initial results from a single institution. *Surg. Endosc.* **2017**, *31*, 5381–5388. [[CrossRef](#)]
16. Kahaleh, M.; Gonzalez, J.M.; Xu, M.M.; Andalib, I.; Gaidhane, M.; Tyberg, A.; Saumoy, M.; Marchena, A.J.B.; Barthet, M. Gastric peroral endoscopic myotomy for the treatment of refractory gastroparesis: A multicenter international experience. *Endoscopy* **2018**, *50*, 1053–1058. [[CrossRef](#)]
17. Shlomovitz, E.; Pescarus, R.; Cassera, M.A.; Sharata, A.M.; Reavis, K.M.; Dunst, C.M.; Swanström, L.L. Early human experience with per-oral endoscopic pyloromyotomy (POP). *Surg. Endosc.* **2015**, *29*, 543–551. [[CrossRef](#)]
18. Dacha, S.; Mekaroonkamol, P.; Li, L.; Shahnava, N.; Sakaria, S.; Keilin, S.; Willingham, F.; Christie, J.; Cai, Q. Outcomes and quality-of-life assessment after gastric per-oral endoscopic pyloromyotomy (with video). *Gastrointest. Endosc.* **2017**, *86*, 282–289. [[CrossRef](#)] [[PubMed](#)]
19. Allemang, M.T.; Strong, A.T.; Haskins, I.N.; Rodriguez, J.; Ponsky, J.L.; Kroh, M. How I Do It: Per-Oral Pyloromyotomy (POP). *J. Gastrointest. Surg.* **2017**, *21*, 1963–1968. [[CrossRef](#)]
20. Jacques, J.; Pagnon, L.; Hure, F.; Legros, R.; Crepin, S.; Fauchais, A.L.; Palat, S.; Ducrotté, P.; Marin, B.; Fontaine, S. Peroral endoscopic pyloromyotomy is efficacious and safe for refractory gastroparesis: Prospective trial with assessment of pyloric function. *Endoscopy* **2019**, *51*, 40–49. [[CrossRef](#)]
21. Mekaroonkamol, P.; Patel, V.; Shah, R.; Li, B.; Luo, H.; Shen, S.; Chen, H.; Shahnava, N.; Dacha, S.; Keilin, S.; et al. Association between duration or etiology of gastroparesis and clinical response after gastric per-oral endoscopic pyloromyotomy. *Gastrointest. Endosc.* **2019**, *89*, 969–976. [[CrossRef](#)] [[PubMed](#)]
22. Mekaroonkamol, P.; Patel, V.; Shah, R.; Li, T.; Li, B.; Tao, J.; Guan, Q.; Chen, H.; Shahnava, N.; Sakaria, S.; et al. 838 duration of the disease rather than the etiology of gastroparesis is the key predictive factor for clinical response after gastric per oral endoscopy pyloromyotomy (GPOEM). *Gastrointest. Endosc.* **2018**, *87*, AB119–AB120. [[CrossRef](#)]
23. Hedberg, H.M.; Carbray, J.; Ujiki, M.B. Initial Experience with Endoscopic Pyloromyotomy, with Description and Video Technique. *J. Gastrointest. Surg.* **2019**, *23*, 1706–1710. [[CrossRef](#)]
24. Strong, A.T.; Landreneau, J.P.; Cline, M.; Kroh, M.D.; Rodriguez, J.H.; Ponsky, J.L.; El-Hayek, K. Per-Oral Pyloromyotomy (POP) for medically refractory post-surgical gastroparesis. *J. Gastrointest. Surg.* **2019**, *23*, 1095–1103. [[CrossRef](#)] [[PubMed](#)]
25. Xu, J.; Chen, T.; Elkholy, S.; Xu, M.; Zhong, Y.; Zhang, Y.; Chen, W.; Qin, W.; Cai, M.; Zhou, P. Gastric Peroral Endoscopic Myotomy (G-POEM) as a Treatment for Refractory Gastroparesis: Long-Term Outcomes. *Can. J. Gastroenterol. Hepatol.* **2018**, *2018*, 6409698. [[CrossRef](#)] [[PubMed](#)]
26. Rodriguez, J.; Strong, A.T.; Haskins, I.N.; Landreneau, J.P.; Allemang, M.T.; El-Hayek, K.; Villamere, J.; Tu, C.; Cline, M.S.; Kroh, M.; et al. Per-oral Pyloromyotomy (POP) for Medically Refractory Gastroparesis: Short term results from the First 100 Patients at a High Volume Center. *Ann. Surg.* **2018**, *268*, 421–430. [[CrossRef](#)]

Publisher's Note: MDPI stays neutral with regard to jurisdictional claims in published maps and institutional affiliations.



© 2020 by the authors. Licensee MDPI, Basel, Switzerland. This article is an open access article distributed under the terms and conditions of the Creative Commons Attribution (CC BY) license (<http://creativecommons.org/licenses/by/4.0/>).