

Case Report

Hemophagocytic Syndrome in a Patient with ALL: Morphology Still Matters

Andrea Duminuco ^{1,*} , Giuseppe A. M. Palumbo ² , Bruno Garibaldi ¹, Rosario Foti ³ ,
Francesco Di Raimondo ², Cinzia Maugeri ², Elisa Mauro ², Paolo F. Fiumara ² and Calogero Vetro ² 

¹ Post Graduation School of Hematology, University of Catania, A.O.U. "Policlinico-San Marco", Via S. Sofia 78, 95123 Catania, Italy; brunga93@gmail.com

² Division of Hematology, A.O.U. "Policlinico-San Marco", Via S. Sofia 78, 95123 Catania, Italy; palumbo.ga@gmail.com (G.A.M.P.); diraimon@unict.it (F.D.R.); maugericinzia@hotmail.com (C.M.); elixmauro@hotmail.it (E.M.); paolo.fiumara@virgilio.it (P.F.F.); c.vetro@policlinico.unict.it (C.V.)

³ Division of Reumathology, A.O.U. "Policlinico-San Marco", 95123 Catania, Italy; rosfoti@tiscali.it

* Correspondence: andrea.duminuco@gmail.com; Tel.: +39-095-378-1997; Fax: +39-095-378-2977



Citation: Duminuco, A.; Palumbo, G.A.M.; Garibaldi, B.; Foti, R.; Di Raimondo, F.; Maugeri, C.; Mauro, E.; Fiumara, P.F.; Vetro, C. Hemophagocytic Syndrome in a Patient with ALL: Morphology Still Matters. *Hemato* **2021**, *2*, 347–352. <https://doi.org/10.3390/hemato2020020>

Academic Editor: Francesco Buccisano

Received: 28 April 2021

Accepted: 27 May 2021

Published: 1 June 2021

Publisher's Note: MDPI stays neutral with regard to jurisdictional claims in published maps and institutional affiliations.

Correction Statement: This article has been republished with a minor change. The change does not affect the scientific content of the article and further details are available within the back-matter of the website version of this article.



Copyright: © 2021 by the authors. Licensee MDPI, Basel, Switzerland. This article is an open access article distributed under the terms and conditions of the Creative Commons Attribution (CC BY) license (<https://creativecommons.org/licenses/by/4.0/>).

Abstract: We report a case of a young patient suffering from very-high risk B-acute lymphoblastic leukemia (ALL) refractory to first-line therapy with early central nervous system relapse, sequentially treated with inotuzumab. At this timepoint, the patient showed persistent transfusion-refractory thrombocytopenia (platelets < 5000/uL), fever and cytomegalovirus infection. A bone marrow reevaluation showed complete remission of ALL, but hemophagocytic elements and activated macrophages were present. At physical examination, the spleen was palpable. Blood chemistry showed hyperferritinemia (1419 ng/mL, normal range 24–336), NK cells suppression (11 cells/microL, minimum value 90) and IL-6 increase (119.1 pg/dL, normal values < 1.8). Triglycerides and fibrinogen were normal. A diagnosis of hemophagocytic lymphohistiocytosis (HLH) was made according to HLH-2004 criteria. The patient was treated with the IL-1 inhibitor anakinra at escalating dosage. After an initial improvement in altered HLH parameters, a clinical worsening occurred with progressing thrombocytopenia and anemia and a remarkable increase in ferritin (4066 ng/mL). The patient then underwent rituximab-based salvage treatment but died due to HLH and B-ALL progression. HLH could be a rare complication in ALL patients. Despite increasing biological knowledge, prognosis remains poor, and more efforts are needed in order to improve survival in these patients.

Keywords: hemophagocytic lymphohistiocytosis; acute lymphoblastic leukemia; morphology; IL-1 receptor antagonist; anakinra

1. Introduction

Hemophagocytic lymphohistiocytosis (HLH) is a rare disease of the immune system, due to a disorder of the immunoregulatory-cell capacity. Additionally, known as macrophage activation syndrome (MAS), it is characterized by a non-physiological proliferation of T-lymphocytes and a marked activation of macrophages. These hyperactive cells secrete high quantities of cytokines responsible for a potentially fatal hyperinflammatory state if not promptly diagnosed and treated. Clinically, it occurs with persistent high fever, hepatosplenomegaly, lymphadenopathy, hemorrhagic manifestations and neurological symptoms. Blood count and serology tests can include pancytopenia, coagulation disorders, hypertriglyceridemia, hypofibrinogenemia and hyperferritinemia [1]. HLH is in turn divided into primary and secondary. Primary or familial HLH is an inherited disease, due to the mutation of a broad spectrum of genes [2–7], while secondary HLH is associated with other diseases, including infections (in particular, cytomegalovirus and Epstein Barr virus) [8], autoimmune diseases such as juvenile dermatomyositis, systemic lupus erythematosus, systemic juvenile idiopathic arthritis, and Kawasaki disease [9], immunodeficiencies [2] and hematological diseases [10]. Recognition of HLH and early

treatment are important, as they are the key to improve the HLH-associated morbidity and mortality.

Several authors have studied the association of HLH with cancer diseases, in particular hematological malignancies (malignancy-associated hemophagocytic syndrome, MAHS) [11–14]. In particular, in a study based on patients with ALL [15], it was seen how 6 out of 971 patients developed hemophagocytic lymphohistiocytosis (T-ALL/MAHS) or Langerhans cell histiocytosis (T-ALL/LCH) (approximately 0.03% of treated T-ALL/year). Four patients developed MAHS and two LCH. All patients with MAHS showed multi-organ involvement, while the LCH patients had only local disease. Only the LCH patients survived, while the outcome was poor for patients with HLH. HLH in B-cell malignancies is less common: there are few cases described in the literature of the association of these conditions (especially with B-ALL), most of them in pediatric age [16].

2. Case Presentation

Here, we report a case of a 23-years-old male patient, native of Sri Lanka, affected by very-high risk B-acute lymphoblastic leukemia (B-ALL). According to Bassan et al. [17], the patient was enrolled in a GIMEMA trial with the usage of pediatric-like chemotherapy, but was declared off-study early due to precocious extramedullary central nervous system (CNS) relapse. In post-first induction bone-marrow reevaluation, we reported complete morphological and immunophenotypic remission, but minimal residual disease (MRD) and the persistence of the localization of cerebrospinal fluid (CSF) disease, with associated neurological symptoms, i.e., left sided hemiparesis, eradicated after repeated lumbar punctures medicated with methotrexate (MTX), dexamethasone and Ara-C.

After the completion of the third consolidation cycle, based on high dose MTX and Ara-C, neurological symptomatology reappeared, flow-cytometric analysis of cerebrospinal fluid was again positive for leukemic cells. Bone marrow re-evaluation showed 8% of lymphoid blasts. The patient also developed a persistent thrombocytopenia (PLT < 5000/uL, normal range > 150,000/uL), with relative normal values regarding hemoglobin (Hb) and white blood cells (WBC), refractory to the transfusion support, notwithstanding the presence of megakaryocytes at bone marrow evaluation. In the hypothesis of immune-mediated thrombocytopenia, he underwent steroid treatment followed by intravenous immunoglobulins. Since refractoriness, we continued with eltrombopag at increasing dosages, but without improvement of the platelet count. Considering the positivity at CNS for disease localization and the positivity at flow-cytometry for CD22, the patient underwent treatment with inotuzumab [18]. After one course of therapy, the patient showed an increase in bilirubin (3.5 mg/dL, mainly direct, normal value 0.2 e 1.1 mg/dL), creating the suspicion of inotuzumab-related hepatic sinusoidal obstruction syndrome (SOS) [19], which was not confirmed on the following abdominal ultrasound exam and measurement of the hepatic venous pressure gradient, with subsequent normalization of bilirubin values. During this period, the patient developed an increasingly worsening fatigue and headache. On brain computed tomography (CT) examination, a subdural hematoma was found and treatment with steroids was promptly started. Cranial and spinal magnetic resonance imaging (MRI) confirmed the occurrence of the subdural hematoma and central location of disease.

Since the low platelet count (fixed at 0/uL) did not respond to the aforementioned therapies, cytomegalovirus (CMV) reactivation was hypothesized. Indeed, in a study involving 734 plasma samples from 95 patients affected by acute leukemia undergoing chemotherapy, CMV was the most commonly detected virus in the different phases of chemotherapy (19.4%), and this, together HHV-6 infection, may contribute to the development of serious clinical manifestations with profound pancytopenia, pneumonia rash and increased risk for bacterial and fungal co-infections [20]. The clinical suspicion was confirmed by laboratory tests (5000 DNA copies); therefore, therapy with ganciclovir was begun, which unfortunately did not have noteworthy results. Bone marrow aspiration was performed for morphological and immunophenotypic evaluation, confirming the complete

remission of the disease (even if with significantly reduced cellularity), but hemophagocytic elements and activated macrophages were observed (Figure 1A–D).

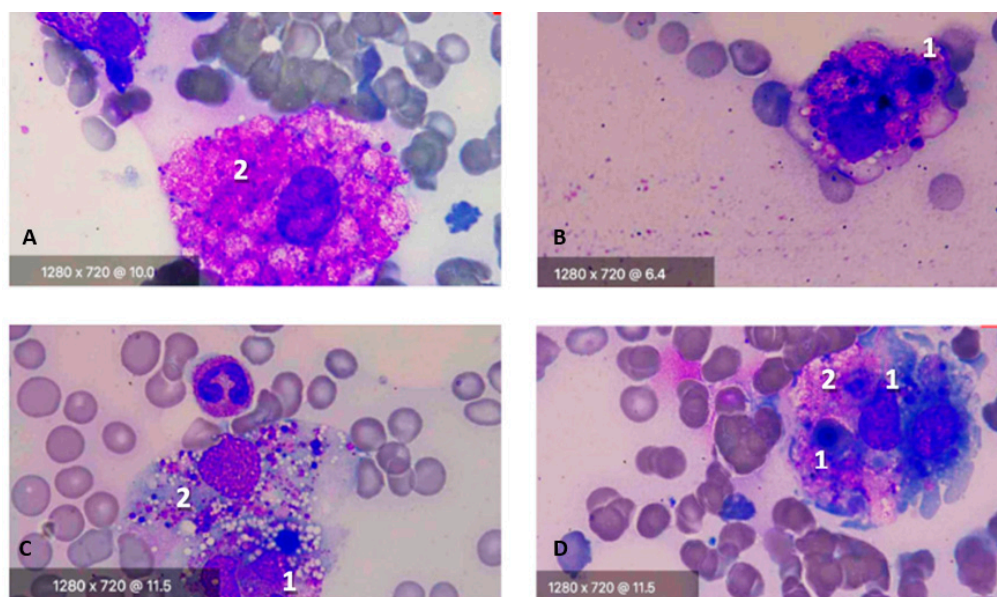


Figure 1. (A–D) Evidence of hemophagocytic elements and activated macrophages observed in bone marrow aspiration: macrophage with presence of phagocytized nucleated cells within the cytoplasm (1) and, above all, platelets (2) (100× magnification).

On physical abdominal examination, spleen was palpable. Blood chemistry tests reported increased ferritinemia (1419 ng/mL), NK-cells were suppressed (11/uL, normal range superior to 60/uL), there was persistent pancytopenia (Hb 8.7 g/dL; neutrophils: 250/uL; PLT 0/uL), IL-6 = 119.1 pg/dL (normal value 5–15 pg/mL), normal values of triglycerides (94 mg/dL), fibrinogen (229 mg/dL) and other liver function tests were normal. The EBV viral load was negative. According to the 2004 criteria of Histiocyte Society [21], these signs and symptoms were diagnostic, thus, for hemophagocytic lymphohistiocytosis (Table 1). The pathogenesis of HLH involves a state of hyperinflammation, which leads to high levels of interleukin. It has been demonstrated that this is a determining factor for both the transient decreased cytotoxic activities of NK cells and the granule exocytosis. The primary mechanisms of HLH could be triggered by the elevated activities of infective agents or autoimmune diseases, thus producing a prolonged immune-activation, mainly by cytotoxic T-cells and macrophages. This dysfunction leads to hyperimmune responses and a cytokine storm. Cytokines are protein molecules usually produced in response to a stimulus, and induce new activities such as cells growth, differentiation and death. The most important cytokines of these processes are interferon gamma (IFN γ), tumor necrosis factor-alpha (TNF-alpha), IL-2, IL-1, IL-6 and IL-18 [1].

Table 1. 2004 criteria of Histiocyte Society for HLH diagnosis.

2004 Criteria of Histiocyte Society for HLH Diagnosis (At Least 5 of the Following 8 Criteria)

- (1) Fever (peak temperature of >38.5 °C for >7 days)
 - (2) Splenomegaly (spleen palpable > 3 cm below costal margin)
 - (3) Cytopenia involving > 2 cell lines (hemoglobin < 9 g/dL, absolute neutrophil count < 100/mcL, platelets < 100,000/mcL)
 - (4) Hypertriglyceridemia (>177 mg/dL) or hypofibrinogenemia (fibrinogen < 150 mg/dL)
 - (5) Hemophagocytosis (in biopsy samples of bone marrow, spleen, or lymph nodes)
 - (6) Low or absent natural killer cell activity
 - (7) Serum ferritin > 500 ng/mL
 - (8) Elevated soluble interleukin-2 (CD25) levels (>2400 U/mL or very high for age)
-

HLH therapy, as already mentioned, must be set as soon as possible. Typically, the first-line treatment consists in corticosteroids (CCS). A common first approach entails high-dose pulse methylprednisolone (1 g/d for 3–5 consecutive days) [22]. When patients are shown to have an insufficient immediate response, cyclosporine (CSA, 2–7 mg/kg per day) may be added, along with IL-1 blocking therapy with anakinra. Lastly, in patients with serious active disease or CNS implication, even if they are treated with steroids, CSA, and/or anakinra, a smaller dose of etoposide (50–100 mg/m² once weekly) could be efficient [23].

In our case, due to the non-responsiveness to high-dose corticosteroids, we asked ourselves about the choice between etoposide and anakinra. Based on HLH management guidelines that exist in the literature [21], considering the genesis attributable to CMV infection and not specifically malignancy-associated (at this time blast clearance, with complete morphological and flow-cytometer remission), in order not to further depress the patient's immune system, our choice was anakinra.

Anakinra, a recombinant IL-1 receptor antagonist, is currently approved by Agenzia Italiana del Farmaco (AIFA) for the treatment of rheumatoid arthritis and neonatal-onset multisystem inflammatory disease, and has been used to treat a variety of autoinflammatory diseases [24]. An American study showed intravenous infusion of high dose anakinra (from 0.25 mg/kg/h a maximum of 2 mg/kg/h) to successfully revert the cytokine storm in four out of five patients [25]. As such, it appears that anakinra may be regarded as an emerging effective choice of therapy in HLH therapy.

Therapy with anakinra in intravenous continuous infusion was administered for 3 days at the minimum dosage and subsequently increased, and gave initial laboratory results: at day +7 from the beginning of the treatment, ferritin decreased to 1060 ng/mL, the triglycerides remained at low limits, the WBC count increased to 7420/mm³ (neutrophils = 3050/mm³), the spleen's size decreased slightly and the patient no longer had feverish episodes. However, after this initial laboratory improvement in altered HLH parameters, a clinical worsening occurred with progressing thrombocytopenia, anemia (minimum limit 5 g/dL) and a remarkable increase in ferritin (4066 ng/mL). Additionally, the patient underwent increasingly frequent episodes of epileptic seizures and a paresis of the upper limbs, which subsequently also spread to the lower limbs, probably due to central location of disease previously discussed and reevaluated in control MRI, unfortunately not treatable with lumbar punctures due to the persistent thrombocytopenia.

The patient then underwent rituximab-based salvage treatment but died due to MAS progression on day +8 from the start of anakinra therapy.

3. Discussion and Conclusions

HLH in ALL patients is a rare and fatal condition requiring prompt diagnosis and appropriate treatment with CCS or biological drugs. Anakinra is under the magnifying glass at this time because of several trials evaluating the efficacy of this drug in patients with COVID-19 infection (e.g., CORIMUNO-ANA) [26]. Anakinra is only approved for subcutaneous administration, but intravenous therapy has been documented in several studies in the scientific literature (e.g., Shakoory B et al. [27], Yang BB et al. [28], Clark SR et al. [29], Mehta Puja et al. [30]). Our choice (continuous IV anakinra infusions in higher doses in patients with HLH related to ALL-B) was based on Monteagudo et al. [25], according to the evidence in four patients (out of five) that the rapid escalation of IL-1 inhibitor can successfully reverse the cytokine storm responsible for the hyperinflammatory state, when other modalities had failed. The anakinra infusion rate should be no less than 5 mL/h and each bag should end at a maximum of 8 h, protecting the tubing from light. In our experience, anakinra was administered for 3 days at minimum dosage and subsequently increased at 1.5 mg/kg/h, with the aim of achieving the total maximum daily dose in a period of approximately 3 weeks, until the disease was stable, changing, thus, the daily administration of 100 mg of subcutaneous anakinra. Our purpose failed to decrease the high quantities of cytokines, despite initial improvement in altered parameters, because

of the principal cause of HLH (ALL-B disease with CNS localization was not curable). Anakinra and other biological drugs have an extremely important and favorable role in the treatment of MAS, but certainly, the current literature is limited and risk–benefit studies are needed. The immediate recognition of MAS, however, is the key to favorable prognosis and, according to recommendations of the Histiocyte Society, morphology plays a pivotal role in assessing diagnosis and addressing the treatment, avoiding potentially fatal complications for the patients.

Author Contributions: Conceptualization, A.D. and C.V.; methodology, R.F.; resources, C.M., E.M., P.F.F. and B.G.; writing—original draft preparation, A.D.; writing—review and editing, A.D. and C.V.; supervision, G.A.M.P. and F.D.R. All authors have read and agreed to the published version of the manuscript.

Funding: This research received no external funding.

Institutional Review Board Statement: Not applicable.

Informed Consent Statement: Written informed consent for participation in the trial was obtained from the patients at the time of enrollment.

Data Availability Statement: Not applicable.

Conflicts of Interest: The authors declare no conflict of interest.

References

- Lerkvaleekul, B.; Vilaiyuk, S. Macrophage activation syndrome: Early diagnosis is key. *Open Access Rheumatol. Res. Rev.* **2018**, *10*, 117–128. [[CrossRef](#)] [[PubMed](#)]
- Bode, S.F.N.; Ammann, S.; Al-Herz, W.; Bataneant, M.; Dvorak, C.C.; Gehring, S.; Gennery, A.; Gilmour, K.C.; Gonzalez-Granado, L.I.; Groß-Wieltsch, U.; et al. The syndrome of hemophagocytic lymphohistiocytosis in primary immunodeficiencies: Implications for differential diagnosis and pathogenesis. *Haematologica* **2015**, *100*, 978–988. [[CrossRef](#)]
- Schmid, J.P.; Canioni, D.; Moshous, D.; Touzot, F.; Mahlaoui, N.; Hauck, F.; Kanegane, H.; Lopez-Granados, E.; Mejstrikova, E.; Pellier, I.; et al. Clinical similarities and differences of patients with X-linked lymphoproliferative syndrome type 1 (XLP-1/SAP deficiency) versus type 2 (XLP-2/XIAP deficiency). *Blood* **2011**, *117*, 1522–1529. [[CrossRef](#)]
- Bryceson, Y.T.; Pende, D.; Maul-Pavicic, A.; Gilmour, K.C.; Ufheil, H.; Vraetz, T.; Chiang, S.C.; Marcenaro, S.; Meazza, R.; Bondzio, I.; et al. A prospective evaluation of degranulation assays in the rapid diagnosis of familial hemophagocytic syndromes. *Blood* **2012**, *119*, 2754–2763. [[CrossRef](#)]
- Kogawa, K.; Lee, S.M.; Villanueva, J.; Marmer, D.; Sumegi, J.; Filipovich, A.H. Perforin expression in cytotoxic lymphocytes from patients with hemophagocytic lymphohistiocytosis and their family members. *Blood* **2002**, *99*, 61–66. [[CrossRef](#)] [[PubMed](#)]
- Marsh, R.A.; Bleesing, J.J.; Filipovich, A.H. Using flow cytometry to screen patients for X-linked lymphoproliferative disease due to SAP deficiency and XIAP deficiency. *J. Immunol. Methods* **2010**, *362*, 1–9. [[CrossRef](#)]
- Sepulveda, F.E.; de Saint Basile, G. Hemophagocytic syndrome: Primary forms and predisposing conditions. *Curr. Opin. Immunol.* **2017**, *49*, 20–26. [[CrossRef](#)] [[PubMed](#)]
- Rouphael, N.G.; Talati, N.J.; Vaughan, C.; Cunningham, K.; Moreira, R.; Gould, C. Infections associated with haemophagocytic syndrome. *Lancet Infect. Dis.* **2007**, *7*, 814–822. [[CrossRef](#)]
- Wysocki, C.A. Comparing hemophagocytic lymphohistiocytosis in pediatric and adult patients. *Curr. Opin. Allergy Clin. Immunol.* **2017**, *17*, 405–413. [[CrossRef](#)] [[PubMed](#)]
- Wang, H.; Xiong, L.; Tang, W.; Zhou, Y.; Li, F. A systematic review of malignancy-associated hemophagocytic lymphohistiocytosis that needs more attentions. *Oncotarget* **2017**, *8*, 59977–59985. [[CrossRef](#)] [[PubMed](#)]
- Takahashi, T.; Matsuguma, M. Refractory hemophagocytic syndrome in a patient with acute myelocytic leukemia. *Blood* **2013**, *121*, 2820. [[CrossRef](#)]
- Daver, N.; McClain, K.; Allen, C.E.; Parikh, S.A.; Otrrock, Z.; Rojas-Hernandez, C.; Blechacz, B.; Wang, S.; Minkov, M.; Jordan, M.B.; et al. A consensus review on malignancy-associated hemophagocytic lymphohistiocytosis in adults. *Cancer* **2017**, *123*, 3229–3240. [[CrossRef](#)]
- Khadanga, S.; Solomon, B.; Dittus, K. Hemophagocytic lymphohistiocytosis (HLH) associated with T-cell lymphomas: Broadening our differential for fever of unknown origin. *N. Am. J. Med. Sci.* **2014**, *6*, 484–486. [[CrossRef](#)]
- Devitt, K.; Cerny, J.; Switzer, B.; Ramanathan, M.; Nath, R.; Yu, H.; Woda, B.A.; Chen, B.J. Hemophagocytic lymphohistiocytosis secondary to T-cell/histiocyte-rich large B-cell lymphoma. *Leuk. Res. Rep.* **2014**, *3*, 42–45. [[CrossRef](#)]
- Trebo, M.M.; Attarbaschi, A.; Mann, G.; Minkov, M.; Kornmüller, R.; Gadner, H. Histiocytosis following T-acute lymphoblastic leukemia: A BFM study. *Leuk. Lymphoma* **2005**, *46*, 1735–1741. [[CrossRef](#)] [[PubMed](#)]
- O'Brien, M.M.; Lee-Kim, Y.; George, T.I.; McClain, K.L.; Twist, C.J.; Jeng, M. Precursor B-cell acute lymphoblastic leukemia presenting with hemophagocytic lymphohistiocytosis. *Pediatr. Blood Cancer* **2008**, *50*, 381–383. [[CrossRef](#)] [[PubMed](#)]

17. Sequential Chemotherapy and Blinatumomab to Improve MRD Response and Survival in Acute Lymphoblastic Leukemia—Full Text View—ClinicalTrials.gov. Available online: <https://clinicaltrials.gov/ct2/show/NCT03367299> (accessed on 31 May 2021).
18. Marks, D.I.; Kebriaei, P.; Stelljes, M.; Gökbuget, N.; Kantarjian, H.; Advani, A.S.; Merchant, A.; Stock, W.; Cassaday, R.D.; Wang, T.; et al. Outcomes of allogeneic stem cell transplantation after inotuzumab ozogamicin treatment for relapsed or refractory acute lymphoblastic leukemia. *Biol. Blood Marrow Transplant.* **2019**, *25*, 1720–1729. [[CrossRef](#)] [[PubMed](#)]
19. Kebriaei, P.; Cutler, C.; De Lima, M.; Giral, S.; Lee, S.J.; Marks, D.; Merchant, A.; Stock, W.; Van Besien, K.; Stelljes, M. Management of important adverse events associated with inotuzumab ozogamicin: Expert panel review. *Bone Marrow Transplant.* **2018**, *53*, 449–456. [[CrossRef](#)] [[PubMed](#)]
20. Handous, I.; Achour, B.; Marzouk, M.; Rouis, S.; Hazgui, O.; Brini, I.; Khelif, A.; Hannachi, N.; Boukadida, J. Co-infections of human herpesviruses (CMV, HHV-6, HHV-7 and EBV) in non-transplant acute leukemia patients undergoing chemotherapy. *Virol. J.* **2020**, *17*, 1–15. [[CrossRef](#)]
21. La Rosée, P.; Horne, A.C.; Hines, M.; Greenwood, T.V.B.; Machowicz, R.; Berliner, N.; Birndt, S.; Gil-Herrera, J.; Girschikofsky, M.; Jordan, M.B.; et al. Recommendations for the management of hemophagocytic lymphohistiocytosis in adults. *Blood* **2019**, *133*, 2465–2477. [[CrossRef](#)]
22. Carter, S.J.; Tattersall, R.S.; Ramanan, A.V. Macrophage activation syndrome in adults: Recent advances in pathophysiology, diagnosis and treatment. *Rheumatology* **2019**, *58*, 5–17. [[CrossRef](#)] [[PubMed](#)]
23. Gavand, P.E.; Serio, I.; Arnaud, L.; Costedoat-Chalumeau, N.; Carvelli, J.; Dossier, A.; Hirschberger, O.; Mouthon, L.; Le Guern, V.; Korganow, A.S.; et al. Clinical spectrum and therapeutic management of systemic lupus erythematosus-associated macrophage activation syndrome: A study of 103 episodes in 89 adult patients. *Autoimmun. Rev.* **2017**, *16*, 743–749. [[CrossRef](#)] [[PubMed](#)]
24. Available online: https://www.ema.europa.eu/en/documents/product-information/kineret-epar-product-information_it.pdf (accessed on 31 May 2021).
25. Monteagudo, L.A.; Boothby, A.; Gertner, E. Continuous intravenous anakinra infusion to calm the cytokine storm in macrophage activation syndrome. *ACR Open Rheumatol.* **2020**, *2*, 276–282. [[CrossRef](#)]
26. CORIMUNO-ANA: Trial Evaluating Efficacy of Anakinra in Patients with Covid-19 Infection—Full Text View—ClinicalTrials.gov. Available online: <https://www.clinicaltrials.gov/ct2/show/NCT04341584> (accessed on 31 May 2021).
27. Shakoory, B.; Carcillo, J.A.; Chatham, W.W.; Amdur, R.L.; Zhao, H.; Dinarello, C.A.; Cron, R.Q.; Opal, S.M. Interleukin-1 receptor blockade is associated with reduced mortality in sepsis patients with features of macrophage activation syndrome: Reanalysis of a prior phase III trial. *Crit. Care Med.* **2016**, *44*, 275–281. [[CrossRef](#)]
28. Yang, B.B.; Baughman, S.; Sullivan, J.T. Pharmacokinetics of anakinra in subjects with different levels of renal function. *Clin. Pharmacol. Ther.* **2003**, *74*, 85–94. [[CrossRef](#)]
29. Clark, S.R.; McMahon, C.J.; Gueorguieva, I.; Rowland, M.; Scarth, S.; Georgiou, R.; Tyrrell, P.J.; Hopkins, S.J.; Rothwell, N.J. Interleukin-1 receptor antagonist penetrates human brain at experimentally therapeutic concentrations. *J. Cereb. Blood Flow Metab.* **2008**, *28*, 387–394. [[CrossRef](#)] [[PubMed](#)]
30. Mehta, P.; Cron, R.Q.; Hartwell, J.; Manson, J.J.; Tattersall, R.S. Silencing the cytokine storm: The use of intravenous anakinra in haemophagocytic lymphohistiocytosis or macrophage activation syndrome. *Lancet Rheumatol.* **2020**, *2*, e358–e367. [[CrossRef](#)]