

# Romidepsin controls chronic lymphocytic leukemia in a patient with mycosis fungoides

David. M. Lemchak,<sup>1</sup> Oleg. E. Akilov<sup>2</sup>

<sup>1</sup>University of Pittsburgh Medical Center Altoona, PA; <sup>2</sup>Department of Dermatology, University of Pittsburgh, Pittsburgh, PA, USA

## Abstract

Romidepsin belongs to a class of medications called histone deacetylase inhibitors and is currently approved for treatment of cutaneous and peripheral T-cell lymphomas. Romidepsin was previously investigated for the treatment of chronic lymphocytic leukemia (CLL), and demonstrated potential benefit, but interest in its use declined following phase I clinical trials that showed poor tolerance of a significant side effect profile. We presented a patient with a history of stage II CLL, referred to dermatology for treatment of new-onset mycosis fungoides (MF), who was treated with romidepsin over seven months. The patient achieved a partial response with 50% decrease in body surface area occupied by MF, thinning of remaining plaques, and near complete response in his CLL. His absolute lymphocyte count remained within the normal range for four months following discontinuation of romidepsin. Side effects were well-tolerated and did not limit therapy. Current literature on romidepsin is reviewed and compared to existing treatments for CLL.

## Introduction

Romidepsin (depsipeptide, Istodax<sup>TM</sup>) is a histone deacetylase inhibitor approved by the US Food and Drug Administration for cutaneous and peripheral T-cell lymphoma.<sup>1</sup> While this medication is not currently recommended for chronic lymphocytic leukemia (CLL), several studies have demonstrated activity of romidepsin against CLL.<sup>2,3</sup> Unfortunately, the results of a phase I clinical trial of romidepsin in CLL did not provide sufficient optimism for the continuation of Phase II due to poor side-effect profile.<sup>4</sup> Since that time, significant information was obtained on the side-effect profile and the preventative measures in the other hematologic malignancies. We observed near complete response lasting for four months to romidepsin in a patient with CLL stage II who received 11 cycles of this medication as a treatment for his mycosis fungoides (MF).

## Case Report

A 66 year-old male was referred to the cutaneous lymphoma clinic at the University of Pittsburgh Medical Center for evaluation of a rash of six-month duration that had been diagnosed as mycosis fungoides and confirmed histologically. There were erythematous with bluish hue mildly pruritic patches and plaques on his upper and lower extremities bilaterally, occupying 15% of body surface area (Figure 1A,B). The patient also had a known diagnosis of CLL stage II (Rai) without B symptoms of 18 year duration, for which he had never received treatment. CT scan demonstrated mildly enlarged axillary, upper abdominal, bilateral external iliac, obturator, and inguinal lymph nodes bilaterally. Lymphadenopathy had been present originally at his diagnosis of CLL 18 years prior. Moderate splenomegaly was noted and consistent with his past history of splenomegaly due to CLL. Flow cytometry demonstrated a monotypic CD19+, CD20+, CD5+, CD10-, CD23+, partially FMC7+ population with positive IgH clone that was 48% of total B cells (11,136 cells/mm<sup>3</sup>). In this B cell population, 40% were zap70+, 0.2% were CD49d+, and 0.3% were CD38+. There was also a small population of atypical T cells that were 26.4% of CD3+ T cells (440 cells/mm<sup>3</sup>) with the following phenotype CD3+, CD45 bright+, CD4+, CD8-, CD7-. CD25 was present on 38% of the CD3+ T-cells, CD26 was not detected on 36% of the CD4+ T-cells, and CD7 was not detected on 62% of the CD4 T-cells. Based on these findings, his MF was staged as stage II disease (T2N1M0B1). The patient was started on romidepsin administered over a 21 day cycle, two weeks on followed by one off week. The patient received eleven cycles of romidepsin over seven months, with the dose starting at 10 mg/m<sup>2</sup> and being increased to 14 mg/m<sup>2</sup> in later cycles. The patient demonstrated partial response of his MF with 50% decrease in body surface area and thinning of the remaining plaques limited to the abdomen, back, and preauricular region. The patient demonstrated near complete response in his CLL. His absolute lymphocyte count (ALC) decreased over this period: from 10.5×10<sup>9</sup>/L to 5.76×10<sup>9</sup>/L after the first cycle, and went below 4.0×10<sup>9</sup>/L after cycle 4, and continued to remain within this range with subsequent cycles (Figure 1C). Hemoglobin remained stable above 12 g/dL during treatment. The patient had transient thrombocytopenia (below 100×10<sup>9</sup>/L), which always recovered during the rest week. After two cycles of romidepsin, there was an absence of lymphadenopathy and splenomegaly on physical examination, and both remained absent throughout the course of treatment. During treatment with romidepsin, the patient did

Correspondence: Oleg E. Akilov, Department of Dermatology, University of Pittsburgh, 5th Floor, Suite 500.68, 3708 Fifth Avenue, Pittsburgh, PA 15213, USA.  
Tel.: +1.412.647.4200 - Fax: +1.412.864.3736.  
E-mail: akilovoe@upmc.edu

Key words: Chronic lymphocytic leukemia; Histone deacetylase inhibitors; Romidepsin,

Contributions: OEA has been the lead physician handling care of this patient's CTCL, responsible for composition, data analysis, and editing of the manuscript; DML, contributed to the composition, data analysis, and editing of the case report.

Conflict of interest: the authors declare no potential conflict of interest.

Received for publication: 16 August 2016.

Accepted for publication: 11 October 2016.

This work is licensed under a Creative Commons Attribution-NonCommercial 4.0 International License (CC BY-NC 4.0).

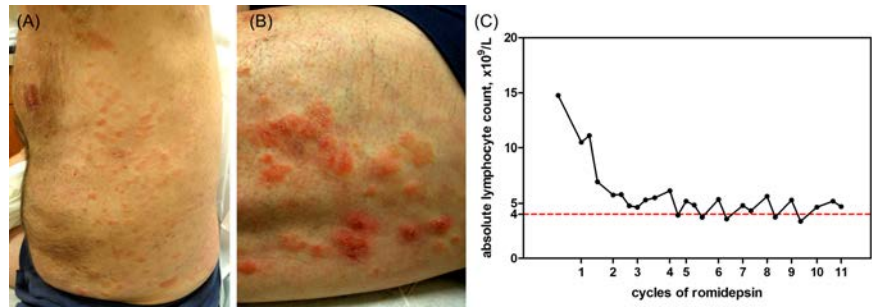
©Copyright D.M. Lemchak and O. E. Akilov, 2016  
Licensee PAGEPress, Italy  
Hematology Reports 2016; 8:6840  
doi:10.4081/hr.2016.6840

report dysgeusia and dose-dependent asthenia lasting 24-48 hours after infusion. Interestingly, he managed to improve his asthenia by forcing himself to eat in spite of dysgeusia. Due to clinical improvement after 11 cycles of romidepsin, treatment of his MF was switched to bexarotene and narrow band UVB therapy in an attempt at adequate disease management with agents that had less burden of adverse effects. After discontinuation of romidepsin, his ALC rose four months later to 6.75×10<sup>9</sup>/L. Flow cytometry performed 13 months after discontinuation of romidepsin demonstrated a persistent population of B-lymphocytes with an immunophenotype of CD19+, CD20+, CD5+, CD23+, CD200+, CD10-, and FMC-7+. This population was 14% of total B lymphocytes (770 cells/mm<sup>3</sup>), representing a 93% decrease prior initiation of the therapy with romidepsin. No population of atypical T cells was demonstrated in the peripheral blood 13 months after romidepsin discontinuation.

## Discussion

There are multiple treatment options currently available for CLL depending on patient's age, symptoms, and phenotype of the leukemic population.<sup>3,5</sup> Frequently, the first-line agents, fludarabine and rituximab, are used in combination with other drugs. Multiple clinical trials

of those combinations have demonstrated promising results.<sup>3,5</sup> For example, the phase II clinical trial of combined rituximab with fludarabine and cyclophosphamide showed an overall response rate (ORR) of 95% and complete response in 72%.<sup>5</sup> Halek *et al.* recommended this combination as a first-line treatment for patients with active or Rai III-IV disease who are in good physical condition.<sup>5</sup> Adverse effects of this combination include fatigue, nausea, thrombocytopenia, neutropenia, and increased risk for infection.<sup>3,5</sup> More recently, Bruton's tyrosine kinase inhibitors, like ibrutinib, and BCL-2 antagonists, like venetoclax, have shown benefit in treating CLL. Ibrutinib was recommended as first-line treatment for active or Rai III-IV disease with p53 mutation or del(17p).<sup>5</sup> A three-year follow-up study of Ibrutinib for CLL showed only mild toxicity, most commonly diarrhea (58%), that was tolerated well enough to allow for continuous infusion for long treatment periods, with an ORR of 84% and complete remission in 7%.<sup>6</sup> A Phase II study of the combination of ibrutinib and rituximab showed a progression-free survival of 78% at 18 months, with 30-40% experiencing bleeding events or nausea/vomiting that were graded no worse than Grade 2.<sup>5</sup> In a phase III trial of venetoclax for 84 patients, 79% had an ORR, with side effects including diarrhea (37%), nausea (36%), and neutropenia (35%).<sup>5</sup> Only 10.5% discontinued therapy due to adverse effects.<sup>5</sup> Romidepsin is a histone deacetylase inhibitor currently approved by the US Food and Drug Administration for the treatment of CTCL and PTCL.<sup>1</sup> A phase II trial of Romidepsin for patients with CTCL demonstrated an ORR of 34%.<sup>7</sup> The dose given in this trial was 14 mg/m<sup>2</sup> given on days 1, 8, and 15 of a 28-day cycle, and was raised to 17.5 mg/m<sup>2</sup> if no adverse effects had presented.<sup>7</sup> Of those with an ORR (46 patients), only five withdrew from the study due to adverse effects, despite 41% of patients experiencing fatigue and 54% developing an infection.<sup>7</sup> 20-52% of patients had systemic symptoms, including nausea, fatigue, anorexia, and vomiting.<sup>7</sup> Hematologic side effects were seen in 21-39% of patients, and included leukopenia, granulocytopenia, thrombocytopenia, and anemia, with most of these returning to baseline by the time of administration of the next cycle of romidepsin.<sup>7</sup> Currently, romidepsin is not an approved treatment for CLL, but there is evidence to suggest it has therapeutic benefit for CLL. Romidepsin has been shown to induce apoptosis in CLL cells through both, the FAS receptor leading to activation of caspase 8, which differs from pathways used by other CLL treatments, and by TNF-related apoptosis-inducing ligand (TRAIL).<sup>3,8</sup> A phase I trial performed by Byrd *et al.* demonstrated that patients with CLL who were treated with romidepsin had on average



**Figure 1.** Clinical presentation of mycosis fungoides. Symmetrical confluent eczematous patches and plaques on the flanks (A) and upper thighs (B). Treatment with Romidepsin caused significant improvement of lesions, as well as a substantial decrease in absolute lymphocyte count that was sustained with subsequent cycles (C).

over a 50% decrease in their leukocyte count within a few days at a dose of 13 mg/m<sup>2</sup> given as an IV infusion over four hours, three days a month in a monthly cycle.<sup>4</sup> However, of the ten patients in this trial, six stopped treatment after 1-2 cycles due to adverse effects of nausea, anorexia, and fatigue.<sup>4</sup> Decreasing the dose to limit these side effects produced either no clinical improvement or worsening of their CLL.<sup>4</sup> Further, none of the patients using romidepsin met grade 3 of the NCI criteria for partial response.<sup>4</sup> The combination of not meeting these criteria and adverse effects ended the further investigation of romidepsin for treating CLL, despite the benefit from continued treatment, different dosing schedule, or use in combination with rituximab.<sup>4</sup> Similar constitutional and hematologic symptoms were seen in a phase I trial done by Marshall *et al.* of romidepsin as a treatment in several advanced cancers.<sup>9</sup> These symptoms were not dose-limiting at the 13.3 mg/m<sup>2</sup> dose.<sup>9</sup> The use of antiemetics was found to be helpful in relieving some side effects during treatment.<sup>9</sup>

## Conclusions

The patient in our case was able to tolerate eleven cycles of romidepsin, with clinical improvement of both his MF and CLL. During treatment, the patient developed dysgeusia, asthenia, and transient thrombocytopenia, but none of these led to discontinuation of his treatment. The cycle of romidepsin this patient underwent used a similar dosage to the previous phase I and II trials discussed, but with a shorter cycle length of three weeks. Interestingly, at doses of 13-14 mg/m<sup>2</sup>, side effects limited treatment in the majority of CLL patients in the phase I study, but rarely led to discontinuation of treatment in the CTCL patients of the phase II study, in patients with advanced cancers, and did not limit treatment in our patient.<sup>4,7,9</sup> Thus, romidepsin can be used as alternative medication in patients with CLL and secondary malignancy.

## References

1. Valdez BC, Brammer JE, Li Y, et al. Romidepsin targets multiple survival signaling pathways in malignant T cells. *Blood Cancer J* 2015;5:e357.
2. Byrd JC, Shinn C, Ravi R, et al. Depsipeptide (FR901228): a novel therapeutic agent with selective, in vitro activity against human B-cell chronic lymphocytic leukemia cells. *Blood* 1999;94:1401-8.
3. Aron JL, Parthun MR, Marcucci G, et al. Depsipeptide (FR901228) induces histone acetylation and inhibition of histone deacetylase in chronic lymphocytic leukemia cells concurrent with activation of caspase 8-mediated apoptosis and down-regulation of c-FLIP protein. *Blood* 2003;102:652-8.
4. Byrd JC, Marcucci G, Parthun MR, et al. A phase I and pharmacodynamic study of depsipeptide (FK228) in chronic lymphocytic leukemia and acute myeloid leukemia. *Blood* 2005;105:959-67.
5. Hallek M. Chronic lymphocytic leukemia: 2015. Update on diagnosis, risk stratification, and treatment. *Am J Hematol* 2015;90:446-60.
6. Byrd JC, Furman RR, Coutre SE, et al. Three-year follow-up of treatment-naïve and previously treated patients with CLL and SLL receiving single-agent ibrutinib. *Blood* 2015;125:2497-506.
7. Piekars RL, Frye R, Turner M, et al. Phase II multi-institutional trial of the histone deacetylase inhibitor romidepsin as monotherapy for patients with cutaneous T-cell lymphoma. *J Clin Oncol* 2009;27: 5410-7.
8. Inoue S, Harper N, Walewska R, et al. Enhanced Fas-associated death domain recruitment by histone deacetylase inhibitors is critical for the sensitization of chronic lymphocytic leukemia cells to TRAIL-induced apoptosis. *Mol Cancer Ther* 2009;8:3088-97.
9. Marshall JL, Rizvi N, Kauh J, et al. A phase I trial of depsipeptide (FR901228) in patients with advanced cancer. *J Exp Ther Oncol* 2002;2:325-32.