



Case Report

# Fine-Needle Aspiration Is Suitable for Breast Cancer *BRCA* Molecular Assessment: A Case Report

Francesco Pepe <sup>1,†</sup>, Pasquale Pisapia <sup>1,†</sup> , Gianluca Russo <sup>1</sup> , Mariantonia Nacchio <sup>1</sup>, Elena Vigliar <sup>1</sup> , Mario Giuliano <sup>2</sup>, Umberto Malapelle <sup>1</sup> , Giancarlo Troncone <sup>1,\*</sup> and Claudio Bellevicine <sup>1</sup>

<sup>1</sup> Department of Public Health, University of Naples Federico II, 80131 Naples, Italy; francesco.pepe4@unina.it (F.P.); pasquale.pisapia@unina.it (P.P.); gianlucar93@libero.it (G.R.); mariantonia.nacchio@unina.it (M.N.); elena.vigliar@unina.it (E.V.); umberto.malapelle@unina.it (U.M.); claudio.bellevicine@unina.it (C.B.)

<sup>2</sup> Department of Clinical Medicine and Surgery, University of Naples Federico II, 80131 Naples, Italy; mario.giuliano@unina.it

\* Correspondence: giancarlo.troncone@unina.it

† These authors contributed equally.

**Abstract:** Breast cancer is the most common cause of cancer-related deaths in the female population worldwide. To the best of our knowledge, breast cancer (*BRCA*)1/2 gene mutations have not been described yet on breast cancer cytological specimens. Here we describe the case of a 38-year old woman with a family and personal history for breast cancer, who underwent a fine needle aspiration (FNA) procedure for a novel 30 mm lesion located in the external quadrants of the contralateral (left) breast. Cytological findings and ancillary immunostaining confirmed the diagnosis of a triple negative NST carcinoma. *BRCA*1/2 molecular assessment was carried out on DNA extracted from cytological (November 2020), biopsy (December 2014) and surgical resection (July 2015) specimens, as well as on the resection of a benign fibroadenoma, by using a next generation sequencing approach. Molecular analysis showed a pathogenic *BRCA*1 insertion (c.5266dupC; p.Q1756PfsTer74) in the cytological specimen (allelic fraction 92.0%), biopsy (allelic fraction 84.2%), surgical resection (allelic fraction 87.8%) and fibroadenoma (58.9%), demonstrating a germinal *BRCA* mutated status.

**Keywords:** breast cancer; molecular cytopathology; FNA; *BRCA*1/2; PARPi; NGS



**Citation:** Pepe, F.; Pisapia, P.; Russo, G.; Nacchio, M.; Vigliar, E.; Giuliano, M.; Malapelle, U.; Troncone, G.; Bellevicine, C. Fine-Needle Aspiration Is Suitable for Breast Cancer *BRCA* Molecular Assessment: A Case Report. *J. Mol. Pathol.* **2021**, *2*, 319–324. <https://doi.org/10.3390/jmp2040028>

Academic Editor: Caterina Marchiò

Received: 27 October 2021

Accepted: 30 November 2021

Published: 3 December 2021

**Publisher's Note:** MDPI stays neutral with regard to jurisdictional claims in published maps and institutional affiliations.



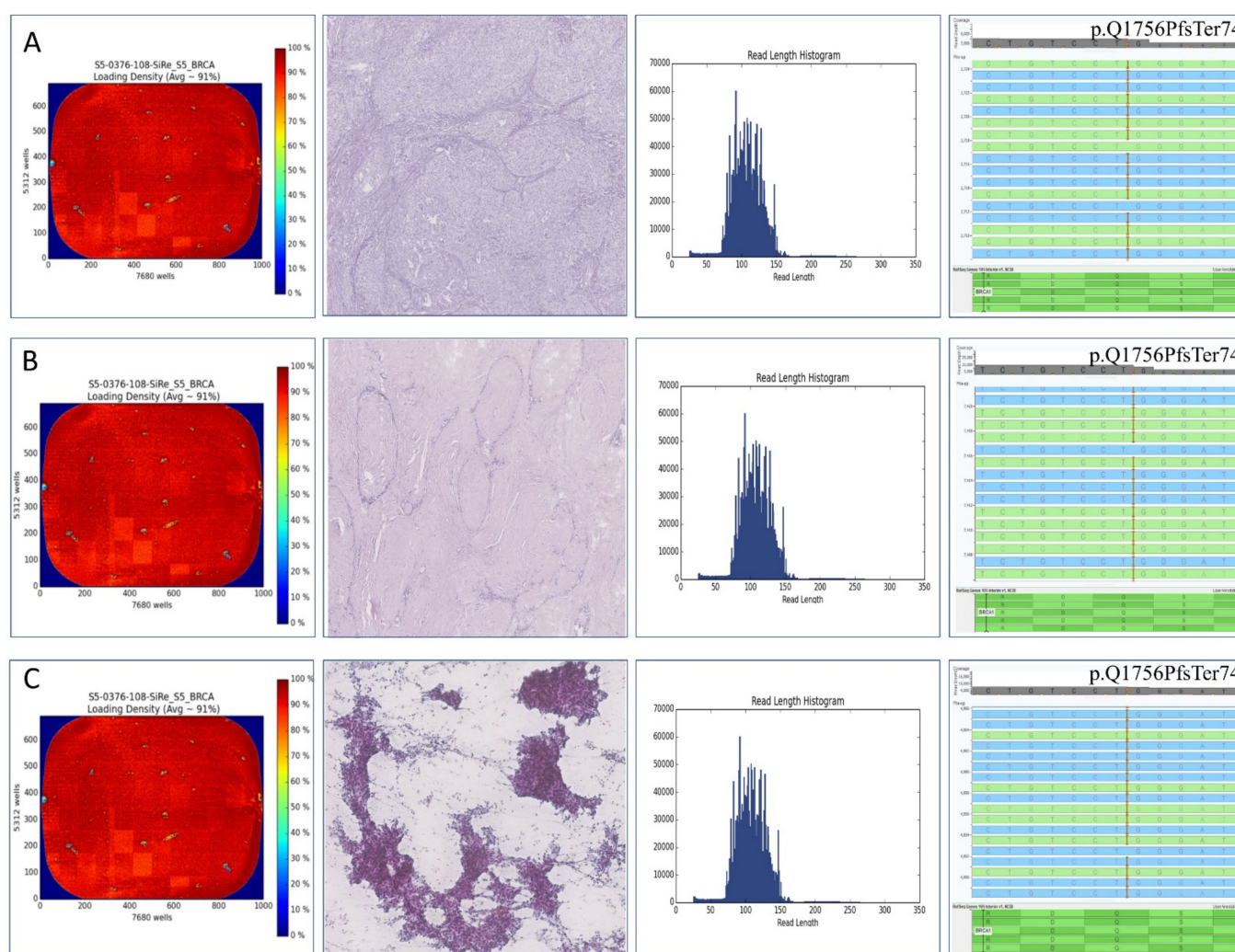
**Copyright:** © 2021 by the authors. Licensee MDPI, Basel, Switzerland. This article is an open access article distributed under the terms and conditions of the Creative Commons Attribution (CC BY) license (<https://creativecommons.org/licenses/by/4.0/>).

## 1. Introduction

Breast cancer represents the most common cause of cancer-related deaths in the female population worldwide, with a dramatically increasing numbers [1]. Despite the improvements in the screening and therapeutic management of breast cancer patients, the advanced stages of disease are still difficult to treat [2]. Beyond standard systemic therapies, an additional arrow in the quiver of oncologists is represented by poly (adenosine diphosphate-ribose) polymerase inhibitors (PARPi) [3]. To date, two PARPi monotherapies, olaparib and talazoparib have, in the United States Food and Drug Administration (FDA) and European Medicines Agency (EMA), obtained approval for advanced stages germline breast cancer (*BRCA*) 1/2 genes-mutated, human epidermal growth factor receptor 2 (HER2)-negative, in breast cancer patients [4–7]. In advanced stages of the disease, a minimal invasive fine needle aspiration (FNA) approach for primitive or metastatic lesions plays a key role in the morphological and molecular evaluation of different solid tumors, including breast cancer [8–10]. Nowadays, next generation sequencing (NGS) represents a valid approach for *BRCA* tumor testing in breast cancer patients [11]. However, *BRCA*1/2 mutations on cytological specimens have not been described yet. Here we report a case harboring a *BRCA*1 mutation, identified through an NGS approach in both cytological and histological specimens.

## 2. Case Report

In November 2014, a 38-year old woman with a family history for breast cancer underwent a fine needle aspiration (FNA) procedure at the University of Naples “Federico II” on a right, under-areolar, breast lesion of 33 mm of diameter. The US-guided procedure was performed by a trained interventional cytopathologist, as previously reported [9]. Smears were readily fixed in 95% ethanol and subsequently stained with Papanicolaou. An additional pass was taken and rinsed in formalin to ensure a cell block (CB) preparation. The direct smears showed a necrotic background with occasional histiocytes, and numerous solid groups of epithelial cells feature striking nuclear abnormalities. The immunocytochemical (ICC) analysis performed on CB showed negativity for estrogen (ER clone SP1, Ventana, Oro Valley, AZ, USA), progesterone (PR clone 1E2, Ventana) receptors and Human Epidermal Growth Factor Receptor 2 (HER2, Dako test, Agilent Technologies, Santa Clara, CA, USA). Ki67 (clone 30-9, Ventana) was expressed by 40% of the cells. A diagnosis of high grade, triple negative, breast carcinoma of no special type (NST) was carried out. Subsequently, the histological evaluation performed on both a core biopsy (December 2014) and surgical resection (July 2015), confirmed the evidence of an invasive, high grade, triple negative, breast NST carcinoma. Concurrently, a benign fibroadenoma was also resected. The patient was then administered with sequential chemotherapy, which included a combination of anthracyclines and taxanes. During the follow-up, in November 2020, a second FNA was requested upon the evidence of a novel 30 mm lesion located in the external quadrants of the contralateral (left) breast. The cytological and ICC features overlapped with that of the FNA from the primary lesion. Thus, a metastasis from the previous triple negative NST carcinoma was diagnosed. Due to the lack of receptor expressions on ICC, the aggressive clinical course and a family history for breast cancer, the patient underwent a molecular analysis for *BRCA 1/2* alterations. To this end, next generation sequencing (NGS) analysis was carried out on DNA extracted from cytological smear (November 2020), biopsy (December 2014) and surgical resection (July 2015) specimens. To evaluate the presence of the genomic alteration at the germinal level, DNA extracted from the concurrent benign lesion (fibroadenoma) was also tested. The analysis was carried out by adopting a commercially available NGS 2-pool panel (OncoPrint™ *BRCA* Research Assay, Thermo Fisher Scientific, Waltham, MA, USA) able to cover 100% of the coding sequences in *BRCA1/2* genes, including all coding splice site and acceptor sites, with an average of 64 bp extension into adjoining introns on Ion Torrent S5 (Thermo Fisher Scientific). Data inspection was automatically carried out using Ion Reporter Torrent Suite version 5.18.0.1 with a dedicated analysis workflow optimized for somatic annotation of *BRCA* alterations. In detail, a minimum depth of 500×, a quality score  $\geq 20$  and an allele mutation frequency for  $\geq 5\%$  were required to successfully identify *BRCA1/2* mutations. In addition, BAM files were visually inspected with the Golden Helix Genome Browser v.2.0.7 (Bozeman, MT, USA). Variant annotation was performed according to Human Genome Variation Society nomenclature. Variants were classified as pathogenic or likely pathogenic (collectively termed pathogenic) according to the American College of Medical Genetics and Genomics (ACMG) recommendations with the inspection of Evidence-based Network for the Interpretation of Germline Mutant Alleles (ENIGMA) and ClinVar (NCBI) databases. Molecular analysis showed a pathogenic *BRCA1* insertion (c.5266dupC; p.Q1756PfsTer74) in the cytological specimen (allelic fraction 92.0%, number of mapped reads: 1934441, uniformity of amplicon coverage: 7003), biopsy (allelic fraction 84.2%, number of mapped reads: 1177566, uniformity of amplicon coverage: 5369), surgical resection (allelic fraction 87.8%, number of mapped reads: 1229612, uniformity of amplicon coverage: 4016) and fibroadenoma (58.9%, number of mapped reads: 9027266, uniformity of amplicon coverage: 5065), demonstrating a germinal *BRCA* mutated status (Figure 1). No other clinically relevant alterations were found. Thus, since the *BRCA* mutation was also retrieved as germinal alteration in the fibroadenoma, the patient was referred to the oncologist for the PARPi therapy.



**Figure 1.** From left to right, Ion Sphere Particles (ISPs) density, morphological features, mean read length and visual inspection of generated reads for the surgical resection (A), fibroadenoma (B) and cytological smear (C).

### 3. Discussion

Here we showed the technical feasibility of the *BRCA1/2* molecular assessment on FNA from a metastatic breast lesion. Given its cost-effectiveness and tolerability, FNA for breast solid lesions is still employed to guide clinicians and surgeons for the best treatment approach [12]. To date, the introduction of the Yokohama System for Reporting Breast FNA by the International Academy of Cytology has improved the diagnostic value of this minimal invasive approach by standardizing the morphological report [13]. From a molecular point of view, cytological samples represent a suitable starting material to carry out NGS molecular analysis for predictive purposes and to refine the risk of malignancy of indeterminate cytological diagnosis [14,15]. Less is known about the feasibility of NGS analysis on breast cytological samples for *BRCA1/2* genomic assessment. To date, the analysis of *BRCA1/2* genes has acquired relevant clinical importance due to the FDA and EMA approval of two PARPi monotherapies, olaparib and talazoparib, for advanced stage, germline *BRCA1/2* genes-mutated, HER2-negative, breast cancer patients [4–7]. In this setting, the absence of surgical resection or of tissue biopsy specimens due to the high invasiveness, risks and discomfort for patients, may be associated with a clinical bias for treatment decision making. Conversely, the minimal invasive FNA may be a valid solution to overcome these limitations. In addition, cytological smears do not suffer from the issue related to formalin fixation that impact on the quality of extracted nucleic acids in histological samples [16]. However, in the present case, the histological material from



the first occurrence of the cancer was available and we were able to verify the presence of *BRCA1* mutation on both the primary and benign lesion, thus confirming the germline origin of the *BRCA1* mutation. It has been widely demonstrated that among patients with HER2-negative metastatic breast cancer harboring a germline *BRCA* mutation, olaparib or talazoparib monotherapy determine a significant clinical outcome respect to standard therapies [17,18]. In the OlympiA clinical trial high-risk, HER2-negative early breast cancer and germline *BRCA1/2* pathogenic or likely pathogenic variants, received adjuvant olaparib with the evidence of a significant improvement in progression free survival respect to placebo group [19]. Another possible clinical application of PARPi is the association with immunotherapy in advanced stage, triple negative breast cancer patients. Vinayak et al. [20] and Domchek et al. [21] highlighted that the association of niraparib plus pembrolizumab and olaparib and durvalumab showed promising antitumour activity and safety.

The main limitations of this study lie in the absence of control samples to check the reproducibility of NGS experiments and the absence of blood sample-derived DNA to confirm the germinal origin of the detected alteration. However, further studies by our group are ongoing to evaluate the role of our NGS approach for the identification of *BRCA1/2* gene alterations in diagnostic routine practice. However, we speculate that the detected alteration has a germline origin due to identification in either malignant (allelic fraction of about 100%) or benign (allelic fraction of about 50%) lesions.

In conclusion, to the best of our knowledge, this is the first report describing the NGS assessment of *BRCA1/2* on cytological samples obtained from breast cancer, confirming the suitability of minimal invasive FNA as a valuable biospecimen for molecular-based predictive tests. Further studies are needed to confirm the suitability of cytology specimens for detecting *BRCA1/2* molecular alterations by using NGS.

**Author Contributions:** Conceptualization, F.P., P.P., G.T. and C.B.; methodology, F.P., P.P., G.R., M.N., E.V., M.G., U.M., G.T., C.B.; software, F.P., P.P., G.R., M.N., E.V., M.G., U.M., G.T., C.B.; validation, F.P., P.P., G.R., M.N., E.V., M.G., U.M., G.T., C.B.; formal analysis, F.P., P.P., G.R., M.N., E.V., M.G., U.M., G.T., C.B.; investigation, F.P., P.P., G.R., M.N., E.V., M.G., U.M., G.T., C.B.; resources, F.P., P.P., G.R., M.N., E.V., M.G., U.M., G.T., C.B.; data curation, F.P., P.P., G.R., M.N., E.V., M.G., U.M., G.T., C.B.; writing—original draft preparation, F.P., P.P. and C.B.; writing—review & editing, F.P., P.P., G.R., M.N., E.V., M.G., U.M., G.T., C.B.; visualization, all authors; supervision, G.T. and C.B.; project administration, C.B. All authors have read and agreed to the published version of the manuscript.

**Funding:** The authors have not declared a specific grant for this research from any funding agency in the public, commercial or not-for-profit sectors.

**Institutional Review Board Statement:** Written informed consent was obtained from all patients and documented in accordance with the general authorization to process personal data for scientific research purposes from “The Italian Data Protection Authority” (<http://www.garanteprivacy.it/web/guest/home/docweb/-/docwebdisplay/export/2485392>, accessed on 27 October 2021). All information regarding human material was managed using anonymous numerical codes, and all samples were handled in compliance with the Helsinki Declaration (<https://www.wma.net/fr/news-post/en-matiere-de-transfert-des-taches-la-securite-des-patients-et-la-qualite-des-soins-devraient-etre-primordiales/>, accessed on 27 October 2021). According to the aforementioned national guidelines, the double-blinded study did not require an Ethical Committee approval since it did not affect the clinical management of the involved patients’ samples.

**Informed Consent Statement:** Informed consent was obtained from the patient involved in the study.

**Data Availability Statement:** The data presented in this study are available on request from the corresponding author.

**Conflicts of Interest:** Elena Vigliar has received personal fees (as consultant and/or speaker bureau) from Diaceutics, unrelated to the current work. Umberto Malapelle has received personal fees (as consultant and/or speaker bureau) from Boehringer Ingelheim, Roche, MSD, Amgen, Thermo Fisher Scientifics, Eli Lilly, Diaceutics, GSK, Merck and AstraZeneca, unrelated to the current work. Giancarlo Troncone reports personal fees (as speaker bureau or advisor) from Roche, MSD, Pfizer,

Boehringer Ingelheim, Eli Lilly, BMS, GSK, Menarini, AstraZeneca, Amgen and Bayer, unrelated to the current work. The other authors have nothing to disclose.

## References

1. Heer, E.; Harper, A.; Escandor, N.; Sung, H.; McCormack, V.; Fidler-Benaoudia, M.M. Global burden and trends in premenopausal and postmenopausal breast cancer: A population-based study. *Lancet Glob. Health* **2020**, *8*, e1027–e1037. [CrossRef]
2. Thill, M.; Jackisch, C.; Janni, W.; Müller, V.; Albert, U.S.; Bauerfeind, I.; Blohmer, J.; Budach, W.; Dall, P.; Diel, I.; et al. AGO Recommendations for the Diagnosis and Treatment of Patients with Locally Advanced and Metastatic Breast Cancer: Update 2019. *Breast Care* **2019**, *14*, 247–255. [CrossRef] [PubMed]
3. Cortesi, L.; Rugo, H.S.; Jackisch, C. An Overview of PARP Inhibitors for the Treatment of Breast Cancer. *Target Oncol.* **2021**, *16*, 255–282. [CrossRef] [PubMed]
4. FDA Approves Olaparib for Germline BRCA-Mutated Metastatic Breast Cancer. Available online: <https://www.fda.gov/drugs/resources-information-approved-drugs/fda-approves-olaparib-germline-brca-mutated-metastatic-breast-cancer> (accessed on 1 June 2021).
5. Lynparza Approved in EU for the Treatment of Germline BRCA-Mutated HER2-Negative Advanced Breast Cancer. Available online: <https://www.astrazeneca.com/media-centre/press-releases/2019/lynparza-approved-in-eu-for-the-treatment-of-germline-brca-mutated-her2-negative-advanced-breast-cancer-10042019.html#> (accessed on 1 June 2021).
6. FDA Approves Talazoparib for gBRCAm HER2-Negative Locally Advanced or Metastatic Breast Cancer. Available online: <https://www.fda.gov/drugs/drug-approvals-and-databases/fda-approves-talazoparib-gbrcam-her2-negative-locally-advanced-or-metastatic-breast-cancer> (accessed on 1 June 2021).
7. European Commission Approves TALZENNA®(Talazoparib) for Patients with Inherited (Germline) BRCA-Mutated Locally Advanced or Metastatic Breast Cancer. Available online: [https://www.pfizer.com/news/press-release/press-release-detail/european\\_commission\\_approves\\_talzenna\\_talazoparib\\_for\\_patients\\_with\\_inherited\\_germline\\_brca\\_mutated\\_locally\\_advanced\\_or\\_metastatic\\_breast\\_cancer](https://www.pfizer.com/news/press-release/press-release-detail/european_commission_approves_talzenna_talazoparib_for_patients_with_inherited_germline_brca_mutated_locally_advanced_or_metastatic_breast_cancer) (accessed on 1 June 2021).
8. Field, A.S.; Raymond, W.A.; Schmitt, F. The International Academy of Cytology Yokohama System for Reporting Breast Fine Needle Aspiration Biopsy Cytopathology: Recent research findings and the future. *Cancer Cytopathol.* **2021**. epub ahead of print. [CrossRef] [PubMed]
9. De Rosa, F.; Migliatino, I.; Vigliar, E.; Salatiello, M.; Pisapia, P.; Iaccarino, A.; Russo, D.; Insabato, L.; Accurso, A.; Arpino, G.; et al. The continuing role of breast fine-needle aspiration biopsy after the introduction of the IAC Yokohama System For Reporting Breast Fine Needle Aspiration Biopsy Cytopathology. *Diagn. Cytopathol.* **2020**, *48*, 1244–1253. [CrossRef] [PubMed]
10. Beca, F.; Schmitt, F.C. Ancillary Tests in Breast Cytology: A Practical Guide. *Acta Cytol.* **2019**, *63*, 302–313. [CrossRef] [PubMed]
11. Concolino, P.; Gelli, G.; Rizza, R.; Costella, A.; Scambia, G.; Capoluongo, E. BRCA1 and BRCA2 Testing through Next Generation Sequencing in a Small Cohort of Italian Breast/Ovarian Cancer Patients: Novel Pathogenic and Unknown Clinical Significance Variants. *Int. J. Mol. Sci.* **2019**, *20*, 3442. [CrossRef] [PubMed]
12. Field, A.S.; Schmitt, F.; Vielh, P. IAC Standardized Reporting of Breast Fine-Needle Aspiration Biopsy Cytology. *Acta Cytol.* **2017**, *61*, 3–6. [CrossRef] [PubMed]
13. Field, A.S.; Raymond, W.A.; Rickard, M.; Arnold, L.; Brachtel, E.F.; Chaiwun, B.; Chen, L.; Di Bonito, L.; Kurtycz, D.F.I.; Lee, A.H.S. The International Academy of Cytology Yokohama System for Reporting Breast Fine-Needle Aspiration Biopsy Cytopathology. *Acta Cytol.* **2019**, *63*, 257–273. [CrossRef] [PubMed]
14. Pisapia, P.; Pepe, F.; Iaccarino, A.; Sgariglia, R.; Nacchio, M.; Conticelli, F.; Salatiello, M.; Tufano, R.; Russo, G.; Gragnano, G.; et al. Next Generation Sequencing in Cytopathology: Focus on Non-Small Cell Lung Cancer. *Front. Med.* **2021**, *8*, 633923. [CrossRef] [PubMed]
15. Pisapia, P.; Pepe, F.; Sgariglia, R.; Nacchio, M.; Russo, G.; Conticelli, F.; Girolami, I.; Eccher, A.; Bellevicine, C.; Vigliar, E.; et al. Next generation sequencing in cytology. *Cytopathology* **2021**. epub ahead of print. [CrossRef] [PubMed]
16. Srinivasan, M.; Sedmak, D.; Jewell, S. Effect of fixatives and tissue processing on the content and integrity of nucleic acids. *Am. J. Pathol.* **2002**, *161*, 1961–1971. [CrossRef]
17. Robson, M.; Im, S.A.; Senkus, E.; Xu, B.; Domchek, S.M.; Masuda, N.; Delaloge, S.; Li, W.; Tung, N.; Armstrong, A.; et al. Olaparib for Metastatic Breast Cancer in Patients with a Germline BRCA Mutation. *N. Engl. J. Med.* **2017**, *377*, 523–533. [CrossRef] [PubMed]
18. Litton, J.K.; Rugo, H.S.; Ettl, J.; Hurvitz, S.A.; Gonçalves, A.; Lee, K.H.; Fehrenbacher, L.; Yerushalmi, R.; Mina, L.A.; Martin, M. Talazoparib in Patients with Advanced Breast Cancer and a Germline BRCA Mutation. *N. Engl. J. Med.* **2018**, *379*, 753–763. [CrossRef] [PubMed]
19. Tutt, A.N.J.; Garber, J.E.; Kaufman, B.; Viale, G.; Fumagalli, D.; Rastogi, P.; Gelber, R.D.; de Azambuja, E.; Fielding, A.; Balmaña, J. OlympiA Clinical Trial Steering Committee and Investigators. Adjuvant Olaparib for Patients with BRCA1- or BRCA2-Mutated Breast Cancer. *N. Engl. J. Med.* **2021**. epub ahead of print. [CrossRef] [PubMed]

- 
20. Vinayak, S.; Tolaney, S.M.; Schwartzberg, L.; Mita, M.; McCann, G.; Tan, A.R.; Wahner-Hendrickson, A.E.; Forero, A.; Anders, C.; Wulf, G.M.; et al. Open-label Clinical Trial of Niraparib Combined with Pembrolizumab for Treatment of Advanced or Metastatic Triple-Negative Breast Cancer. *JAMA Oncol.* **2019**, *5*, 1132–1140. [[CrossRef](#)] [[PubMed](#)]
  21. Domchek, S.M.; Postel-Vinay, S.; Im, S.A.; Park, Y.H.; Delord, J.P.; Italiano, A.; Alexandre, J.; You, B.; Bastian, S.; Krebs, M.G. Olaparib and durvalumab in patients with germline BRCA-mutated metastatic breast cancer (MEDIOLA): An open-label, multicentre, phase 1/2, basket study. *Lancet Oncol.* **2020**, *21*, 1155–1164. [[CrossRef](#)]