

CLINICAL CASE REPORT

Medicina (Kaunas) 2010;46(12):827-34

Diagnosis and treatment of conduct disorder related to frontal lobe syndrome in a 16-year-old girl

Darius Leskauskas¹, Gediminas Kunca¹, Virginija Adomaitienė¹,
Rymantė Gleiznienė², Liutauras Labanauskas³

¹Department of Psychiatry, Medical Academy, Lithuanian University of Health Sciences,

²Department of Radiology, Medical Academy, Lithuanian University of Health Sciences,

³Department of Children's Diseases, Medical Academy, Lithuanian University of Health Sciences, Lithuania

Key words: conduct disorder; frontal lobe syndrome; disinhibition; treatment.

Summary. Conduct disorders are the most frequent psychiatric diagnosis in the pediatric and adolescent population, with different etiology and difficult to treat. Delinquent, aggressive, and impulsive behavior, lack of empathy and inability to predict possible consequences of the behavior lead to significant desadaptation and danger for these patients. In clinical practice, focus is usually given on social and psychological causes of conduct disorders ignoring possible biological factors in etiology and pathophysiology. A clinical case described in this article shows the linkage between frontal brain dysfunction and behavioral symptoms. The first clues of organic brain disorder were multiple and severe symptoms of disinhibition resistant to treatment with dopaminergic drugs and the results of neuropsychological testing. Computed tomography, magnetic resonance imaging, and single-photon emission computed tomography findings were minor and not supported by associated neurological symptoms. However, the location of alterations of brain structure and perfusion significantly correlated with psychopathology. Clarification of the organic cause of the conduct disorder allowed choosing an effective strategy of psychopharmacologic treatment. A positive clinical effect was achieved after switching the treatment from dopaminergic antipsychotic drugs to carbamazepine, which modulates the GABAergic system. Presenting this clinical case, we intended to emphasize the importance of careful attention to the findings of neurovisual and neuropsychological testing diagnosing conduct disorders and individually choosing the most effective psychopharmacologic treatment.

Introduction

Aggressive, antisocial behavior, conduct problems are the most common reasons accounting for 30–40% of all referrals to child and adolescent mental health care services (1). Conduct disorders are the most common psychiatric diagnosis among children and adolescents and one of the conditions most difficult to treat. The prevalence exceeds 5% among boys and reaches 16% among adolescents. Conduct disorders are more commonly diagnosed among boys than girls. The ratio is typically cited to be 3:1 for boys to girls, as 8–16% of boys and 3% of girls aged 4–16 years are diagnosed with conduct disorders (2). The ICD-10 classification characterizes conduct disorders as a repetitive and persistent pattern of behavior, in which either the basic rights of others or major age-appropriate societal norms and rules are violated, lasting at least 6 months, with antisocial, aggressive, provocative behavior

being present above the ordinary teenage rebellion or children disobedience (3). The etiology of conduct disorders is usually associated with adverse psychosocial environment including relationships in the family and at school, but it is known that their presentation can be influenced by structural or functional abnormalities of the central nervous system (CNS). The ICD-10 classification distinguishes these types of conduct disorders: conduct disorder confined to the family context, unsocialized conduct disorder, socialized conduct disorder, oppositional defiant disorder, depressive conduct disorder, mixed and other not specified conduct disorders. Hyperkinetic conduct disorders are also assigned to the group of conduct disorders. Biological etiology of hyperkinetic behavioral disorders is well investigated, while the etiological factors for conduct disorders are not clearly defined and examined.

According to the bio-psycho-social theory cur-

Correspondence to D. Leskauskas, Department of Psychiatry, Medical Academy, Lithuanian University of Health Sciences, Eivenių 2, 50028 Kaunas, Lithuania
E-mail: dleskauskas@yahoo.com

Adresas susirašinėti: D. Leskauskas, LSMU MA Psichiatrijos klinika, Eivenių 2, 50028 Kaunas
El. paštas: dleskauskas@yahoo.com

rently prevailing in psychiatry, etiological causes of conduct problems are diverse and can be divided into several main groups:

Associated with psychological factors. Cognitive factors are usually associated with impaired ability to process and use emotionally meaningful environmental information and being unable to make socially appropriate decisions based on it (4). It has been noticed that individuals with an inappropriate aggressive, impulsive, antisocial behavior often have lower intellectual abilities (5, 6). Early formed personality traits, such as emotional superficiality, lack of emotional awareness, absence of guilt or conscience, superficial charm, low level of anxiety, seeking of intensive sensation, are also associated with conduct disorders.

Associated with social factors. Disharmonious parent-child relationships, early experience of violence and other psychological trauma, insufficient social and parenting skills, alcohol and drug abuse of parents, inadequate education are associated with conduct disorders in childhood and adolescence (7–9). Considerable importance is attached to peer influences: early exclusion of an aggressive child from normal peer group and his/her later identification with the group of delinquent peers. Poverty, unemployment, poor household living conditions, and bad neighborhoods have also to be mentioned (10, 11).

Associated with biological factors. This relatively large group receives increasing attention of researchers and includes genetic, physiologic, neuroendocrine, neurotransmitter, neuroanatomic, and neurotoxic biological factors. Studies involving adopted children and twins have provided a large body of evidence that genetic factors influence more frequent occurrence of conduct disorders in twins (12, 13) and adopted children whose parents had been diagnosed with antisocial personality disorder (14, 15). Research shows that individuals with conduct disorders often demonstrate many signs of physiological underarousal: low heart rate resting and responding to stressful situations (16, 17), alterations of sleep EEG and skin conductance (17, 18). Neurotoxic factors are associated with abuse of alcohol, nicotine, and drugs in prenatal and perinatal period (19, 20). Neuroendocrine factors influencing behavioral problems are associated with the hypothalamus-pituitary-adrenal axis, which regulates response to stress and cortisol release into the bloodstream (21). Low cortisol levels were found in younger children who in later life manifested: aggressive behavior (22). Neurotransmitter factors: it is known that impaired neurotransmission in serotonergic, dopaminergic, noradrenergic, and GABAergic (GABA, gamma amino butyric acid) systems are associated with increased irritability, aggressiveness, and manic-depressive clinical manifestations (23–25). Neuroanatomic factors: single-

photon emission computed tomography (SPECT), positron emission tomography (PET), magnetic resonance imaging (MRI), and functional magnetic resonance imaging (fMRI) studies show correlations between impairment of brain structure and function in the specific localization of the CNS and aggressive/antisocial behavior (26). Much attention is paid to the prefrontal cortical region where different areas are associated with occurrence of aggressive, impulsive behavior and social-emotional self-regulation of an individual (27). Recent studies have suggested the links between dysfunction of amygdala, decreased volume of gray matter of the brain and aggressive delinquent behavior in adolescence, psychopathic personality traits in adulthood (28).

It should be emphasized that all listed etiological factors rarely occur isolated. Their mutual accumulating interaction significantly increases the risk of conduct disorder, affects the dynamics of development of the disorder, and influences efficacy of treatment. Therefore, medical and psychosocial treatment strategy for each individual should be chosen with regard to etiological factors significant for this individual case. Traditionally, diagnosing and treating juvenile conduct disorders in everyday clinical work, too much emphasis is placed on psychological and social factors unfairly forgetting possible biological components of these disorders. Such an approach ignores the possibilities for individually selected psychopharmacologic treatment options offered by improving neurovisual and neuropsychological diagnostic measures.

Case report

A 16-year-old female patient was urgently hospitalized because of acute significant psychomotor agitation and threats of suicide. The patient is the second child from the first marriage; she has 10- and 20-year-old healthy sisters. The mother and biological father divorced when the patient was 3 years old because of father's violence toward family members and frequent heavy drinking. Prenatal and perinatal periods were without any complications. Early psychomotor development went normally and timely. At the age of 5 years, the patient had a car accident, but no significant injuries were documented. During preschool years, she was a withdrawn, quiet child, fearful of strangers. Starting school at the age of 7 years, she faced difficulties in learning from the beginning, particularly in reading and writing. Because of that, at the age of 12 years, she underwent psychological examination with the Wechsler Intelligence Scale for Children-Third Edition (WISC-III) and the Child Behavior Checklist (CBCL) measures showing the following results: verbal IQ, 68; nonverbal IQ, 61; and total IQ, 64;

low intellectual abilities, fast processing of information, with the notable fluctuations in attention and impulsivity determining a big number of mistakes. Behavior of the patient significantly changed at the age of 14 – she became truant at school, started running away from home, became very aggressive, with poor control of the affect, engaged in a loose sexual behavior. She was not able to explain the reason of such behavior to her parents. Because of behavioral problems and aggression, she was hospitalized in a pediatric psychiatry ward at the age of 15 years. She was diagnosed with mixed disorder of conduct and emotions and mild mental retardation; the patient was treated with haloperidol (1.5 mg b.i.d.) and benzodiazepines. The effect of treatment was poor and short-term. Conduct disorder was progressing – the patient began to steal and sell things and ran away from home more frequently. Feeling unable to control her behavior, her stepfather had enchained her at home, and due to this, parental rights had been temporarily restricted; the patient was sent to the foster home. Because of frequent escapes from the institution, conflicts with peers and staff, open aggressiveness toward them, she was again hospitalized in the pediatric psychiatry ward for 3 weeks. She was treated with typical antipsychotics, benzodiazepines, showing a partial and short-term effect. Because of persistent behavioral problems, she was referred to a socialization center where she became violent from the first minutes of arrival, was smashing her head to the wall, strangled herself with hands, throwing around and breaking furniture. With the help of police, she was brought to the emergency room of a hospital.

Mental status at the arrival was as follows: untidy appearance, matted hair, dirty clothes, and poor hygiene; communicating with reluctance, answering the questions roughly, usually in a single word; poor glossary, primitive language, lot of swearing, threatening others. The patient was tensed and anxious. Mood was significantly downgraded, dysphoric. Emotions were labile, easily irritated, showing anger outbursts, especially if her demands were not satisfied. Behavior was unpredictable, aggressive, poor impulse control, episodes of psychomotor agitation. She was banging her fists to the wall, kicking the bed, throwing things to the staff. Thinking was concrete with low productivity. No hallucinations, delusional ideas, or signs of delirium were documented. The patient was correctly oriented in time and environment, however, inconsistently talked about past events, mixing real events with confabulations. She was unable to explain such behavior and actively declared suicidal thoughts and intentions, frequently threatening that she will “find the way to commit suicide.” Problems with concentration and sustaining attention were noted. The

patient lacked judgment and understanding of her condition and situation.

Neurologic examination revealed significant facial asymmetry, normal eye movement, sufficient facial mime, and no bulbar symptoms. No signs of motor impairments were evident. Mild tremor of the left hand was documented with no other pathological neurological symptoms. Neuro-ophthalmologic examination revealed retinal angiopathy of both eyes.

The findings of the WISC-III test were as follows: material analysis was hurried and in some cases superficial, decreased volitional regulation of activity and attention. Verbal intelligence index was low (VIQ 68), nonverbal intelligence index was low (NIQ 67), and overall intelligence index was low (IQ 67). Low level of general knowledge, scant orientation in social situations. Qualities of thinking were as follows: abilities for generalization were low and based on concrete, often nonessential features, poor reservoir of generalizing concepts. Significantly better (reaching borderline level) execution of the task establishing logical sequence of events. Results from constructive tasks showed weak abilities for analysis and synthesis of spatial relationship; better results were documented in the task on formation of objects from the parts. Decreased concentration of attention and decreased operational memory were observed; amount of immediate memorizing was very low. Resistance to distractibility was very low (AT IQ 65). Information processing speed was very slow (the performance speed index, IQ AG 54). The following conclusions from data of neuropsychological test were drawn: hurried execution of tasks, superficial analysis of material, impulsive decision making, lack of critical assessment of own errors. Work lacked volitional efforts; failures were followed by frustration reactions with rather aggressive statements. Lowered social awareness, poor verbalization of thoughts were documented; thinking was very concrete, focused on superficial, concrete qualities of the objects. The patient was unable to comprehend arithmetic tasks requiring two steps to be carried out. These features of performance reflected disordered volitional regulation and thinking problems associated with frontal lobe dysfunction. Better constructive performance in the tasks with concrete visual information was seen: the perceptual organization index (POIQ-74) was higher than the verbal awareness index (VSIQ 62); the index of saving auditory information was very low.

Summarizing, the following aspects were pointed out: low intellectual capacities with concomitant difficulties in volitional regulation, planning and accomplishment of activities, low self-control, emotional instability, impulsivity, aggressive and dysphoric reactions. These disorders of self-regu-

lation suggest the dysfunction of frontal brain areas. Cognitive disorders dominated by difficulties in comprehension and abstract thinking, problems in saving auditory information can be related to more significant dysfunction of the left hemisphere and left temporal region.

Brain CT showed fibrous dysplasia of the right frontal cranial vault and greater wing of the sphenoid bone (Fig. 1).

Brain MRI examination showed no abnormalities in MR signal intensity in the brain. Basal cis-

terns were open. The dysplastic changes of the right frontal cranial vault and frontal sinuses were noticed. The ventricles were slightly wider as for this age group (Fig. 2).

Brain perfusion scintigraphy with ⁹⁹TcHmPAO revealed a visible small area of hypoperfusion in the left inferior frontotemporal area. Total perfusion asymmetry between the left and right hemispheres R>L up to 4% in the individual sections, in the frontal areas R>L asymmetry 4%–8% in individual sections were seen (Fig. 3).

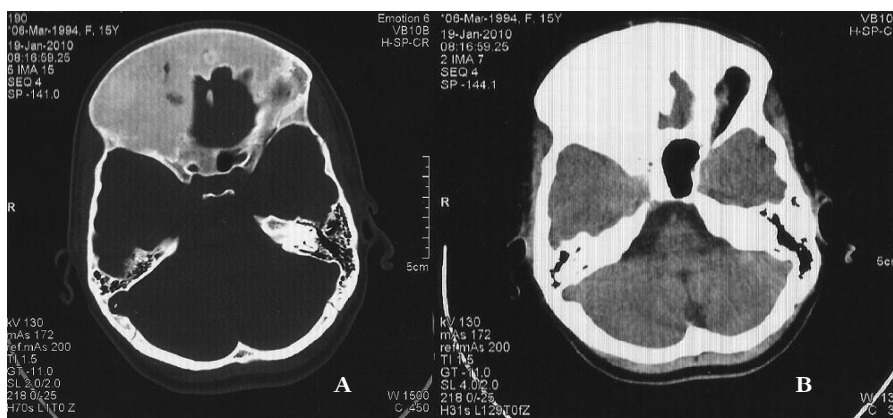


Fig. 1. Brain computed tomography

A, bone window; B, soft tissue window.

Fibrous dysplasia of the right frontal cranial vault and greater wing of the sphenoid bone.

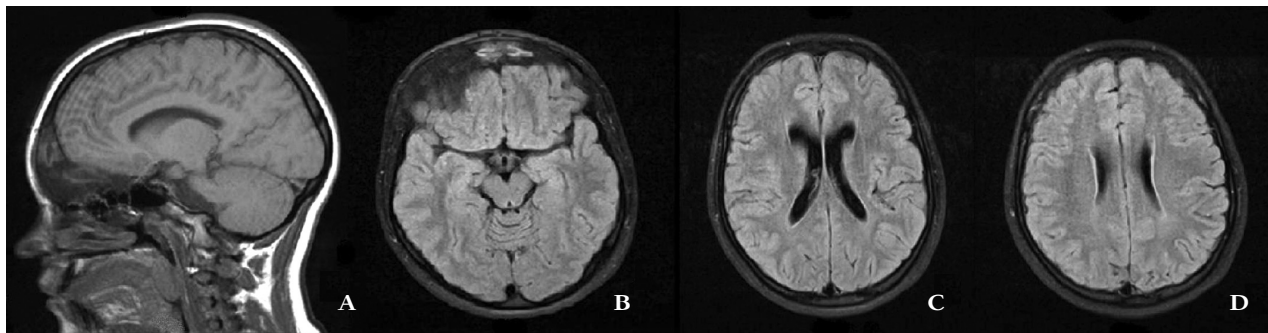


Fig. 2. Brain magnetic resonance imaging

A, T1W/TSE (TR 608 ms, TE 17 ms) sequence sagittal plane; B, C, and D, T2W/FLAIR (TR 9000 ms, TE 89 ms) sequence, axial plane: dysplastic changes of the right frontal cranial vault and frontal sinuses, no significant changes in the left frontotemporal area.

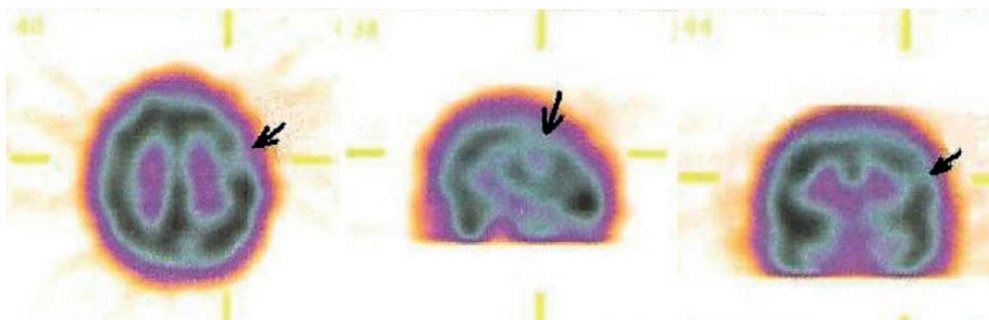


Fig. 3. Brain perfusion scintigraphy

Small area of hypoperfusion in the left inferior frontotemporal area.

Treatment with a conventional, low-potency antipsychotic drug, chlorprothixene, titrating the dose up to 150 mg per day, was initiated, but clinical effect was not significant. Augmentation with diazepam up to 25 mg per day was indicated “when necessary” for symptomatic relief of anxiety and control of aggressive outbursts. Structured environmental, cognitive behavioral and occupational therapies were provided as usually. However, the treatment effect was negligible; the patient remained very aggressive, threatening suicide and self-mutilating, exhibiting impulsive behavior difficult to predict. Cognitive behavioral therapy was impossible due to problems of concentration and operational memory, inability to estimate the possible consequences of behavior and control the impulses seeking positive reinforcement. Because of this and taking into account the results of neurovisual and functional examinations, treatment was changed down-titrating and discontinuing chlorprothixene and switching to an anticonvulsant, carbamazepine. Carbamazepine was started at a dose of 100 mg per day and up-titrated to a dose of 600 mg per day. With the initiation of the treatment with carbamazepine, the patient’s status began to improve: irritability, aggressiveness, and impulsivity decreased, mood improved and stabilized, suicidal intentions and self-mutilating behavior diminished. The parents reported that the patient’s behavior was more easily controlled, running away from home significantly decreased, she was getting engaged in a longer untroubled communication, meaningful work. At this point, her carbamazepine level was 20 $\mu\text{mol/L}$. This treatment effect was preserved during all 3-month follow-up period.

Discussion and conclusions

The presented clinical case is interesting in several aspects. On the one hand, this patient was very difficult in the clinical sense – extreme impulsiveness, aggressiveness, repetitive dangerous behavior toward herself and others, which was not corrected during repeated inpatient treatments by providing a structured and safe environment, cognitive behavioral therapy, and pharmacotherapy with high doses of antipsychotics and benzodiazepine tranquilizers. This prompted a more detailed investigation of possible causes of the disordered behavior. Identified changes of brain structures and perfusion in the frontal regions were minimal and doubtful regarding their clinical significance to other professionals as showing no significant neurological symptoms. However, clinical symptoms and results of neuropsychological testing significantly correlated with psychopathology described in the literature as specific for dysfunction of these brain areas. Together with increased effectiveness of changed treatment strategy, it proves that structural and functional al-

terations in the brain found in neuroimaging tests were relevant to etiology and treatment of this conduct disorder.

Correlations between brain lesions and psychiatric disorders are well known and documented in scientific literature (29, 30). The human frontal lobes integrate sensory-limbic input with memory of the immediate past (working memory) while simultaneously monitoring social circumstances to plan, sequence, and anticipate the consequences of actions and rapidly adjust motor programs in response to ongoing environmental feedback. The ventromedial prefrontal cortex complex includes the orbitofrontal cortex, ventromedial prefrontal cortex, and infra and supracallosal anterior cingulate gyrus. Together these regions help to organize social behaviors and integrate them with both sensory input and visceral processing. The dorsolateral prefrontal cortex generates conscious will to execute a plan, which is a part of intentional behavior sequence. The dorsolateral prefrontal cortex acting under the influence of the ventromedial prefrontal cortex combines new sensory data held in working memory with long-term memories to generate a plan and anticipate its consequences. Having calculated the most adaptive signal stream, the dorsolateral prefrontal cortex transmits it to the supplemental motor area and the premotor cortex for temporal refinement and transmission to the motor strip (31). Recent studies have suggested that aggressive and antisocial behavior and its consequences are significantly and positively associated with orbitofrontal cortex asymmetry, so that the smaller the left orbitofrontal cortex in relation to the right, the greater the aggressive behavior (32). Frontal-subcortical circuits, temporolimbic structures, and nucleus accumbens are parts of the orbitofrontal circuit, whose dysfunction is characterized by disinhibition syndromes including irritability, impulsivity, and undue familiarity. This has been interpreted as the consequence of loss of inhibition by the frontal monitoring system on the limbic system that is responsible for instinctual behaviors (33). The prefrontal cortex is diffusely reached by multiple axon projections of different neurotransmitters. Major dopamine projections predominantly arise from brainstem neurotransmitter centers: ventral tegmental area and substantia nigra. These neurons regulate movements, reward, cognition, psychosis, and many other functions (34). In the columnar organization of the cerebral cortex, GABAergic neurons provide the outer boundaries of the column with inwardly directed axons. While the GABAergic interneurons comprise a minority of cortical neurons, they exert a profound degree of inhibition on the activity of the glutamatergic pyramidal cells. GABAergic neurons project directly to the substantia nigra pars reticulata, which regu-

lates dopaminergic neuronal activity (31). While the mesocorticolimbic dopamine system is implicated in the initiation, execution, termination, and consequences of aggressive behavior, drugs with a high affinity for dopamine D2 receptors lack specificity for reducing aggressive behavior. Positive modulators of GABA_A receptors with specific subunit configuration may be relevant for heightening aggression, and these sites may be the targets for intervention (35).

In this clinical case, we have found structural alterations, which included the skull and frontal brain areas. Examination of cerebral perfusion as well indicated signs of hypoperfusion in the left frontotemporal area. It is worth noting that MRI examination did not indicate any significant changes in the frontotemporal areas found during SPECT examination. Both the structural and perfusion changes in the brain were not marked and questioned regarding their clinical significance as not causing neurological symptoms. However, localization of these changes clearly correlated with the prevailing psychopathology dominated by the symptoms of disinhibition and results of neuropsychological tests. Neuropsychological tests showed time-stable decreased intellectual abilities with more recent disturbances specific to dysfunction of prefrontal-frontal lobe areas and probably in the left hemisphere and temporal regions. For example, an observed lack of empathy was probably determined by failure in interaction among the ventromedial prefrontal, lateral orbitofrontalis, and temporal cortex areas (36).

Effective psychopharmacologic treatment of behavioral disturbances is particularly important for the patients with overt aggression and explosive behavior. Various drug groups were described as effective in reducing impulsive and aggressive behavior in short-term trials, while long-term effectiveness is not clear and requires further investigation. We initiated the treatment with a conventional low-potency antipsychotic drug, chlorprothixene, which has a strong antagonistic effect on the D1, D2, D3, 5HT₂, H1, mACh, α 1-adrenergic receptors. It is analogous

to haloperidol used for treatment previously. This pharmacologic group of drugs is commonly prescribed in clinical practice to reduce aggressive, impulsive behavior because it provides a quick (although often short-term) desired clinical effect for the majority of patients. Their efficiency is explained by a blockage of dopamine (especially D2) receptors because dopamine is involved in activation, motivation, and reward systems of behavior. Studies with animals indicate that the increased dopaminergic activity is associated with increased aggression and impulsiveness. In other studies, pharmacologically changed levels of dopamine in humans increased or decreased aggressive behavior and the ability to recognize other people's aggression (23). However, in our case repetitive treatments with antidopaminergic drugs were completely ineffective. This can be explained by the fact that disruptive behavior manifested because of disturbance in other level of behavior regulation system. Such a kind of disturbance can be suspected because the patient had multiple symptoms of disinhibition in various areas of functioning: extreme lack of impulse control, aggressive and antisocial behavior, hypersexual behavior, and cognitive dysfunction. Therefore, the treatment with carbamazepine, which acts on the GABAergic system, was more effective. GABA is the primary CNS neurotransmitter known as having a strong inhibitory action. It is important for the transmission of impulses between the prefrontal and limbic areas of the brain. Dysregulation of this system can cause disorders of dopamine regulation in several brain areas (37, 38). One of several mechanisms of action of carbamazepine is augmentation of the GABA system, hence a pathophysiological explanation for its beneficial effects in the treatment of disinhibition (39).

Presenting this clinical case, we intended to emphasize the importance of careful attention to the findings of neurovisual and neuropsychological testing diagnosing conduct disorders and individually choosing the most effective psychopharmacologic treatment.

Elgesio sutrikimo, susijusio su frontalinės skilties sindromu, pasireiškusių 16 metų mergaitei, diagnostika ir gydymas

Darius Leskauskas¹, Gediminas Kunca¹, Virginija Adomaitienė¹, Rymantė Gleiznienė², Liutauras Labanauskas³

¹Lietuvos sveikatos mokslų universiteto Medicinos akademijos Psichiatrijos klinika,

²Lietuvos sveikatos mokslų universiteto Medicinos akademijos Radiologijos klinika,

³Lietuvos sveikatos mokslų universiteto Medicinos akademijos Vaikų ligų klinika

Raktažodžiai: elgesio sutrikimai, kaktinės skilties sindromas, disinhibicija, gydymas.

Santrauka. Elgesio sutrikimai yra plati savo etiologija sutrikimų grupė. Bendrojoje vaikų ir paauglių populiacijoje elgesio sutrikimai bene dažniausiai diagnozuojami ir sunkiai gydomi. Delinkventinis, agre-

syvus, impulsyvus elgesys, empatijos bei impulsų kontrolės stygius, negebėjimas numatyti galimų tokio elgesio pasekmių dažnai sukelia didelę pacientų dezadaptaciją, pavojų sau ir aplinkiniams. Klinikinėje praktikoje paprastai daugiau dėmesio skiriama socialinėms bei psichologinėms elgesio sutrikimų priežastims ir pamirštami galimi įvairūs biologiniai etiologiniai ir patofiziologiniai veiksniai. Aprašytu klinikišku atveju norėta parodyti frontaliųjų galvos smegenų sričių disfunkcijos sąsajas su elgesio sutrikimų simptomais, jos reikšmę diagnostikai bei gydymui. Organinis galvos smegenų sutrikimas buvo įtartas dėl sunkiai gydymui neuroleptikais pasiduodančių disinhibicijos simptomų ir būdingų neuropsichologinio tyrimo duomenų. KT, MRT ir SPECT rasta minimalių CNS struktūrinių ir perfuzijos pokyčių, keliančių įtarimų dėl klinikinės reikšmės, nes nesukėlė žymesnių patologiškų neurologinių simptomų. Tačiau jų lokalizacija koreliavo su pasireiškusia psichopatologija, specifiška šios smegenų srities pažeidimams. Nustačius organinę elgesio sutrikimo priežastį, buvo galima pasirinkti efektyvesnę gydymo taktiką. Teigiamo klinikinio poveikio pasiekta pradėjus gydymą GABA-erginę sistemą moduluojamuoju preparatu – karbamazepinu. Taigi, pateikdami šį klinikinį atvejį, autoriai nori atkreipti dėmesį į neurovizualiųjų bei neuropsichologinių tyrimų reikšmę diagnozuojant elgesio sutrikimus ir individualiai pritaikant veiksmingiausią psichofarmakologinį gydymą.

References

- Kazdin A. Treatments for aggressive and antisocial children. *Child Adolesc Psychiatr Clin N Am* 2000;9:841-58.
- Cappadocia MC, Desrocher M, Pepler D, Schroeder JH. Contextualizing the neurobiology of conduct disorder in an emotion dysregulation framework. *Clin Psychol Rev* 2009; 29:506-18.
- The ICD-10 Classification of Mental and Behavioural Disorders. Clinical descriptions and diagnostic guidelines. Geneva: World Health Organization; 1993. p. 191-7.
- Fairchild G, Van Goozen SHM, Stollery SJ, Aitken MRF, Savage J, Moore SC, et al. Decision making and executive function in male adolescents with early-onset or adolescence-onset conduct disorder and control subjects. *Biol Psychiatry* 2009;66:162-8.
- Carpenter DO, Nevin R. Environmental causes of violence. *Physiol Behav* 2010;99:260-8.
- Kebir O, Grizenko N, Sengupta S, Joobar R. Verbal but not performance IQ is highly correlated to externalizing behavior in boys with ADHD carrying both DRD4 and DAT1 risk genotypes. *Prog Neuropsychopharmacol Biol Psychiatry* 2009;33:939-44.
- McCauley Ohannessian C, Hesselbrock VM. Paternal alcoholism and youth substance abuse: the indirect effects of negative affect, conduct problems, and risk taking. *J Adolesc Health* 2008;42:198-200.
- Gartsteina MA, Fagot BI. Parental depression, parenting and family adjustment and child effortful control: explaining externalizing behaviors for preschool children. *Appl Develop Psychol* 2003;24:143-77.
- Kunitz SJ, Levy J, McCloskey J, Gabriel KR. Alcohol dependence and domestic violence as sequelae of abuse and conduct disorder in childhood. *Child Abuse Negl* 1998;22: 1079-91.
- Snyder J, McEachern A, Schrepferman L, Just C, Jenkins M, Roberts S, et al. Contribution of peer deviancy training to the early development of conduct problems: mediators and moderators. *Behav Ther* 2010;41:317-28.
- Najman JM, Clavarino A, McGee TR, Bor W, Williams GM, Hayatbakhsh MR. Timing and chronicity of family poverty and development of unhealthy behaviors in children: a longitudinal study. *J Adolesc Health* 2010;46:538-44.
- Riggins-Caspers K, Cadoret RJ, Panak W, Lempers JD, Troughton E, Stewart MA. Gene x environment interaction and the moderating effect of adoption agency disclosure on estimating genetic effects. *Pers Indiv Differ* 1999;27:357-80.
- Knopik VS, Heath AC, Bucholz KK, Madden PAF, Waldron M. Genetic and environmental influences on externalizing behavior and alcohol problems in adolescence: a female twin study. *Pharmacol Biochem Behav* 2009;93:313-21.
- Langbehn DR, Cadoret RJ. The adult antisocial syndrome with and without antecedent conduct disorder: comparisons from an adoption study. *Compr Psychiatry* 2001;42:272-82.
- Langbehn R, Cadoret JR, Caspers K, Troughton EP, Yucuis R. Genetic and environmental risk factors for the onset of drug use and problems in adoptees. *Drug Alcohol Depend* 2003;69:151-67.
- Murray-Close D, Crick NR. Gender differences in the association between cardiovascular reactivity and aggressive conduct. *Int J Psychophysiol* 2007;65:103-13.
- Posthumus JA, Bocker KBE, Raaijmakers MAJ, Van Engeland H, Matthys W. Heart rate and skin conductance in four-year-old children with aggressive behavior. *Biol Psychol* 2009;82:164-8.
- Knyazeva GG, Slobodskaya HR, Wilson GD. Psychophysiological correlates of behavioural inhibition and activation. *Pers Ind Difference* 2002;33:647-60.
- Huizink AC, Mulder EJH. Maternal smoking, drinking or cannabis use during pregnancy and neurobehavioral and cognitive functioning in human offspring. *Neurosci Biobehav Rev* 2006;30:24-41.
- Silberg JL, Parr T, Neale MC, Rutter M, Angold A, Eaves LJ. Maternal smoking during pregnancy and risk to boys' conduct disturbance: an examination of the causal hypothesis. *Biol Psychiatry* 2003;53:130-5.
- Van Goozen SHM, Fairchild G. Neuroendocrine and neurotransmitter correlates in children with antisocial behavior. *Horm Behav* 2006;50:647-54.
- Fairchild G, Van Goozen SHM, Stollery SJ, Brown J, Gardiner J, Herbert J, et al. Cortisol diurnal rhythm and stress reactivity in male adolescents with early-onset or adolescence-onset conduct disorder. *Biol Psychiatry* 2008;64:599-06.
- Seo D, Patrick CJ, Kennealy PJ. Role of serotonin and dopamine system interactions in the neurobiology of impulsive aggression and its comorbidity with other clinical disorders. *Aggress Violent Behav* 2008;13:383-395.
- Olivier B, Van Oorschoot R. 5-HT1B receptors and aggression: a review. *Eur J Pharmacol* 2005;526:207-17.
- Bjork JM, Moellera FG, Kramerb GL, Kramb M, Surisb A, Rushb AJ, et al. Plasma GABA levels correlate with aggressiveness in relatives of patients with unipolar depressive disorder. *Psychiatry Res* 2001;101:131-6.
- Wahlund K, Kristiansson M. Aggression, psychopathy and brain imaging – review and future recommendations. *Int J Law Psychiatry* 2009;32:266-71.
- Ganslera DA, McLaughlin NCR, Iguchia L, Jerrama M, Moored DW, Bhadeliae R, et al. A multivariate approach to aggression and the orbital frontal cortex in psychiatric patients. *Psychiatry Res* 2009;171:145-54.
- Sterzer P, Stadler C, Poustka F, Kleinschmidt A. A structural neural deficit in adolescents with conduct disorder and its association with lack of empathy. *Neuroimage* 2007;37:335-42.

29. Gudienė D, Burba B. Mental disorders and their relation to brain lesion location: diagnostic problems. *Medicina (Kaunas)* 2003;39(2):105-13.
30. Hawkins KA, Trobst KK. Frontal lobe dysfunction and aggression: conceptual issues and research findings. *Aggress Violent Behav* 2000; 5(2):147-57.
31. Sadock BJ, Sadock VA, Ruiz P, Coyle JT, Victoroff J. Amino acid neurotransmitters; human aggression. In: Kaplan & Sadock's comprehensive textbook of psychiatry. 9th edition. New York: Lippincott Williams & Wilkins; 2009. p. 80-1, 2675-7.
32. Antonucci AS, Gansler DA, Tan S, Bhadelia R, Patz S, Fulwiler C. Orbitofrontal correlates of aggression and impulsivity in psychiatric patients. *Psychiatry Res* 2006;147:213-20.
33. Zamboni G, Huey ED, Krueger F. Apathy and disinhibition in frontotemporal dementia: insights into their neural correlates. *Neurology* 2008;71(10):736-42.
34. Stahl SM. Circuits in psychopharmacology. In: Stahl's essential psychopharmacology: neuroscientific basis and practical applications. 3rd ed. New York: Cambridge University Press; 2008. p. 201-4.
35. De Almeida RMM, Ferrari PF, Parmigiani S, Miczek KA. Escalated aggressive behavior: dopamine, serotonin and GABA. *Eur J Pharmacol* 2005;526:51-64.
36. De Wied M, Gispen-de Wied C, Van Boxtel A. Empathy dysfunction in children and adolescents with disruptive behavior disorders. *Eur J Pharmacol* 2010;626:97-103.
37. Spiegel DR, Qureshi N. The successful treatment of disinhibition due to a possible case of non-human immunodeficiency virus neurosyphilis: a proposed pathophysiological explanation of the symptoms and treatment. *Gen Hosp Psychiatry* 2010;32:221-4.
38. Kato T. Molecular neurobiology of bipolar disorder: a disease of 'mood-stabilizing neurons'? *Trends Neurosci* 2008; 31(10):495-503.
39. Stepanović-Petrović RM, Tomić MA, Vučković SM. GABAergic mechanisms are involved in the antihyperalgesic effects of carbamazepine and oxcarbazepine in a rat model of inflammatory hyperalgesia. *Pharmacology* 2008;82:53-8.

Received 5 October 2010, accepted 7 December 2010
Straipsnis gautas 2010 10 05, priimtas 2010 12 07