

Keratoprosthesis Surgery as an Alternative to Keratoplasty

Vytautas Jašinskas¹, Paulius Rudalevičius¹, Arūnas Miliauskas¹,
Darius Milčius², Ūla V. Jurkūnas³

¹Department of Ophthalmology, Medical Academy, Lithuanian University of Health Sciences, Lithuania,
²Lithuanian Energy Institute, Lithuania, ³Harvard Medical School, Cornea and Refractive Surgery Service,
Massachusetts Eye and Ear Infirmary, Boston, USA

Key Words: Boston type 1 keratoprosthesis; artificial cornea; keratoplasty; corneal blindness; glaucoma.

Summary. Corneal transplant surgery after chemical or thermal burns has a very low success rate. Vision in these patients can be restored by using an artificial cornea (keratoprosthesis). In this report, we present 5 clinical cases of implanting a fresh corneal graft with Boston type 1 keratoprosthesis in patients with corneas inappropriate for standard corneal transplantation. The mean follow-up was 26.4 months (range, 12 to 36 months; SD, 13.1). The main measures of outcomes were visual acuity and keratoprosthesis stability. At least 1 year after the operation (5 eyes), vision acuity was >0.1 in 100% of the eyes and >0.4 in 50% of the eyes. Retention of the initial keratoprosthesis was 100%. The results of this study seem to be similar to those reported internationally. The anatomical and visual functions of the eyes were stable after keratoprosthesis implantation, though for a longer follow-up period, additional surgical procedures may be required.

Introduction

Based on the data from the World Health Organization, approximately 8 million people around the world are affected by corneal blindness (1). In the majority of these patients, vision can be restored with corneal transplantation surgery. More than 100 000 keratoplasties are performed annually worldwide (2). However, there is a very low success rate of corneal transplant surgery caused by concomitant limbal stem cell deficiency appearing after chemical or thermal burns, viral keratitis, ocular cicatricial pemphigoid, Stevens-Johnson syndrome, and trachoma (3). Grafts often become vascularized and opaque and fail shortly after the transplant. Repeated transplantation carries an even worse prognosis: the graft remains transparent for more than 5 years only in 20% of the cases (4). In such cases, vision can be restored by using an artificial cornea, such as a keratoprosthesis (KPro).

The idea of using an artificial cornea to treat blindness was first suggested by Pelier de Quergsy, a French ophthalmologist, in 1789 (5). Attempts to implant glass and various crystals into the cornea have been made for hundreds of years, but turned out to be failures. In 1906, Eduard Zirm, an Austrian ophthalmologist, performed the first successful corneal transplant surgery, which later led to a loss of interest in using artificial corneas. In 1949, Harold Ridley noticed that the eye can tolerate poly-

methylmethacrylate (PMMA) fragments and developed the first intraocular lens made from PMMA (6). In 1950, Englishmen Stone and Herbert made successful experiments with animals and implanted PMMA plates into animal corneas (7). With the introduction of this synthetic plastic polymer of low toxicity and good optical quality and the failure of keratoplasty in chronically edematous and vascularized corneas, interest in corneal implants was renewed. Interlamellar corneal PMMA prostheses are tolerated in human eyes quite well; however, the results were not satisfactory due to the opacity of the remaining stroma (8). In 1954, Vanysek developed a full thickness corneal prosthesis with an interlamellar support element. Subsequently, corneal prostheses have been modified by creating a retrocorneal fixation (9) and replacing support elements by ceramic, Dacron (10), and even tooth tissue (11).

Currently, the 3 main types of KPros used in clinical practice are as follows: AlphaCor KPro, osseo-odonto-KPro, and Boston type 1 KPro (BKPro).

Due to the simplicity of the design and relatively uncomplicated surgical implantation, BKPro has become one of the most commonly used KPro; in 2010 alone, 1200 patients underwent BKPro implantation (12). There are 2 types of BKPros differing in their structure and indication: type 1 BKPro is more often used for patients who produce a sufficient amount of tears to lubricate the ocular surface and type 2 BKPro is used when the ocular surface is very dry and keratinized. Type 2 BKPro differs from type 1 by an additionally elongated 2-mm optic, which after the lids of an eye are sewn up, is

Correspondence to P. Rudalevičius, Department of Ophthalmology, Medical Academy, Lithuanian University of Health Sciences, Eivenių 2, 50028 Kaunas, Lithuania
E-mail: pauliusrudalevicius@gmail.com

brought onto the surface of the skin through the upper lid. The other difference is that the type 1 BKPro provides a visual field of up to 60 degrees, whereas the type 2 BKPro gives a smaller field of 40 degrees. The BKPro was invented by Professor Claes Dohlman at the Massachusetts Eye and Ear Infirmary. In 2009, the type 1 BKPro was implanted in Lithuania for the first time.

This article describes the first 5 patients who underwent type 1 BKPro implantation in the Department of Ophthalmology, Lithuanian University of Health Sciences.

Case Reports

Case 1. A 48-year-old man presented with complaints of poor vision in the left eye. The patient had a history of thermal trauma in the left eye due to condenser explosion. Shortly after the trauma, the ocular surface was covered with a conjunctival flap to preserve the eye. Subsequently, he developed dense corneal opacity (Fig. 1, patient 1, A). The preoperative VA of the right and left eyes was 0.8 and light perception, respectively, with correct light projection and color differentiation.

Case 2. A 56-year-old man presented with complaints of poor vision in the left eye. The patient had a history of chemical burn in the left eye caused by alkaline materials. Subsequently, he developed dense vascularized corneal opacity (Fig. 1, patient 2, A). The preoperative VA of the right and left eyes was 1.0 and 0.01, respectively, with normal color differentiation.

Case 3. An 80-year-old man presented with complaints of poor vision in the left eye. The patient had a history of bullous keratopathy due to complicated cataract surgery and 2 unsuccessful corneal transplants (Fig. 1, patient 3, A). The preoperative VA of the right and left eyes was 0 and hand movements in front of the eye, respectively, with correct color differentiation.

Case 4. A 25-year-old man presented with complaints of poor vision in the right eye. The patient had a history of thermal and mechanical injuries with homemade explosives and then a failed corneal transplant (Fig. 1, patient 4, A). The preoperative VA of the right and left eyes was hand movements in front of the eye and 0, respectively.

Case 5. A 41-year-old man presented with complaints of poor vision in the left eye. The patient had a history of bullous keratopathy after multiple surgical procedures (5 trabeculectomies and 1 Molteno implant) for congenital glaucoma and then 3 failed corneal transplants (Fig. 1, patient 5, A). The preoperative VA of the right eye was 0.01 and hand movements in front of the eye, respectively.

Informed consent for preoperative evaluation, surgery, and postoperative follow-up was obtained from each of the five patients who underwent surgery for a BKPro type 1 implantation.

To determine a candidate for BKPro surgery, a complete ocular history was obtained, and each patient underwent an eye examination. The inclusion criteria according to the Boston Keratoprosthesis International Protocol (13) were as follows: good blinking and tear mechanism, Snellen VA not better than 0.05, no retinal detachment, no end-stage glaucoma, no autoimmune disease, and patient's commitment to regular follow-ups.

A-mode ophthalmic ultrasonography was used to measure the axial length of the globe and determine the power of the optic of the BKPro. B-mode was used due to the opaque cornea in order to assess the anterior and posterior segment of the eye.

BKPro surgery was performed under general anesthesia by the same surgeon (V.J.). The BKPro is made from PMMA and consists of a front plate containing the optic of the KPro, back plate, and locking ring (Fig. 2). The first step was to assemble the corneal graft-BKPro complex. The donor cornea was trephined using a trephine (8.5 mm in diameter); a 3-mm opening was additionally trephined in its center through which an anterior plate with the stem-optics made from PMMA was fitted in. Then a posterior PMMA plate was placed from the side of endothelium, which was fixed to the stem with a titanium ring (Fig. 3) (13). The graft-BKPro complex was placed in the storage solution. An aphakic BKPro was used in 60% (3/5) of the cases, while a pseudophakic BKPro was used in 40% (2/5) of cases. The patient's eye was preoperatively prepared in the routine way. The recipient's cornea was trephined through all layers with a Baron-Hessburg suction-assisted trephine 8 mm in diameter. Reconstructive surgery was performed on the irido-lenticular-anterior vitreous body complex. The iris and the pupil were left intact when possible. If the eye was pseudophakic, the intraocular lens was left in place. If the natural lens was in place, it was removed. Extracapsular extraction was the best thing to do in this case, leaving the posterior capsule to constrain the vitreous. If the anterior vitreous surface was broken in the aphakic eye, moderate open sky core vitrectomy was done. The final step is to transfer the graft-BKPro complex from the storage solution to the trephined recipient's cornea and fix with 16 individual 10-0 nylon sutures. Suture knots were adequately buried beneath the surface. At the end of the surgery, a protective Kontur soft contact lens (Kontur Kontakt Lens Co., Hercules, CA) measuring 16 mm in diameter was placed on the cornea and BKPro for permanent use.

In all 5 cases, the BKPro surgery was done in the manner described above; however, some additional procedures were done. Table 1 lists the intraoperative characteristics of the patients and procedures that were performed.

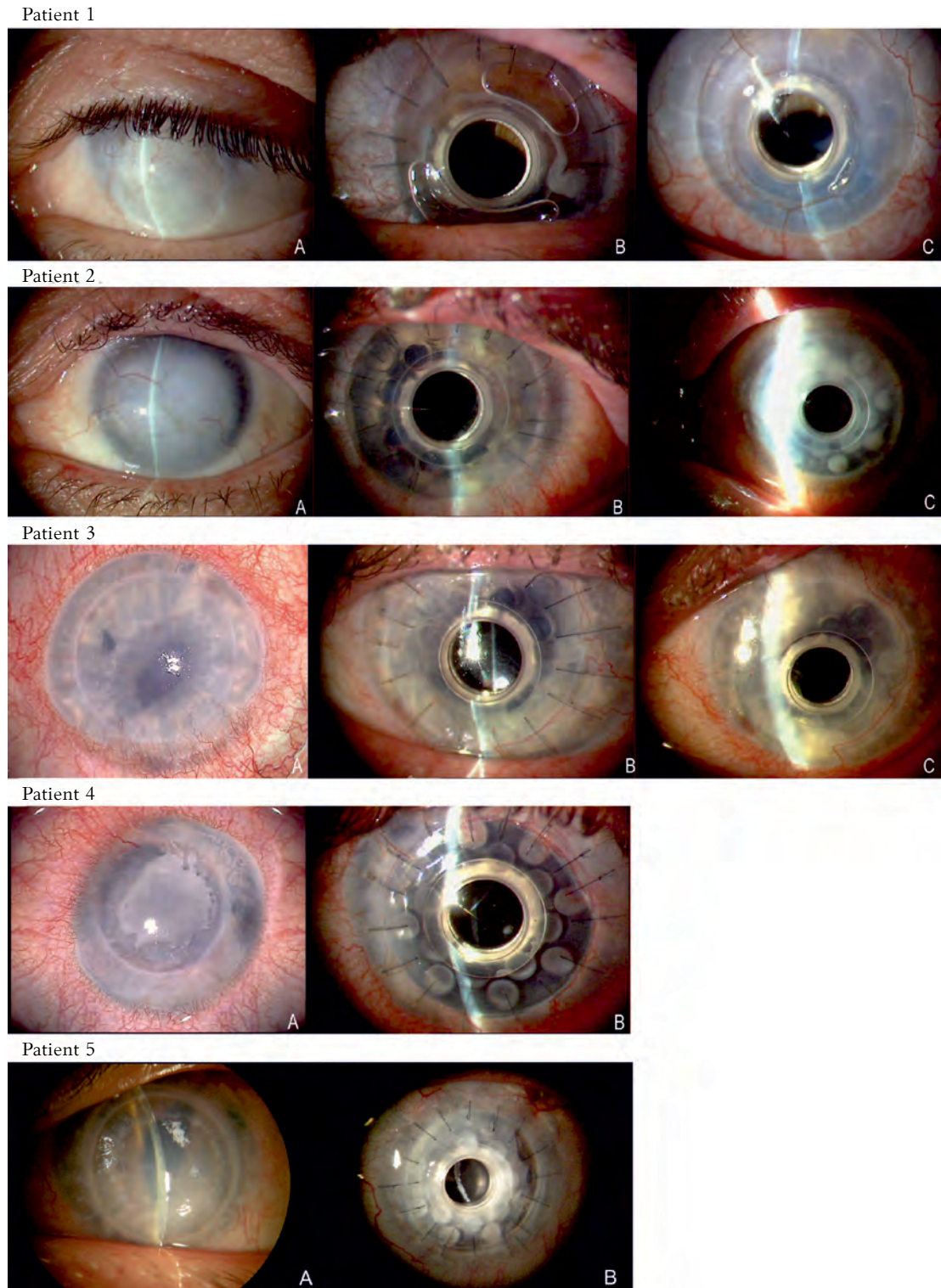


Fig. 1. Photographs of the eyes before and after type 1 keratoprosthesis implantation

Patient 1: A, corneal leukoma after thermal and mechanical injuries; B, 12 months after surgery with good BKPro retention, sutures were not removed, the contact lens was placed on the eye (there was some air under the contact lens). A misalignment of the pupil and optic center of the BKPro implant can be seen; C, 36 months after surgery. BKPro retention was good, the sutures were removed, and the misalignment of the pupil center was same. **Patient 2:** A, corneal leukoma after chemical injury; B, 12 months after surgery with good BKPro retention. The sutures remained, but the contact lens was on the eye; C, 36 months after surgery. BKPro retention was good; the sutures were removed. **Patient 3:** A, failed corneal transplant; B, 12 months after surgery showing good BKPro retention. The sutures remained, and the contact lens was on the eye; C, 36 months after surgery with good BKPro retention. The sutures were removed. **Patient 4:** A, failed corneal transplant; B, 12 months after surgery showing good BKPro retention. The sutures remained, and the contact lens was on the eye. **Patient 5:** A, failed corneal transplant; B, 12 months after surgery showing good BKPro retention. The sutures remained, and the contact lens was on the eye.

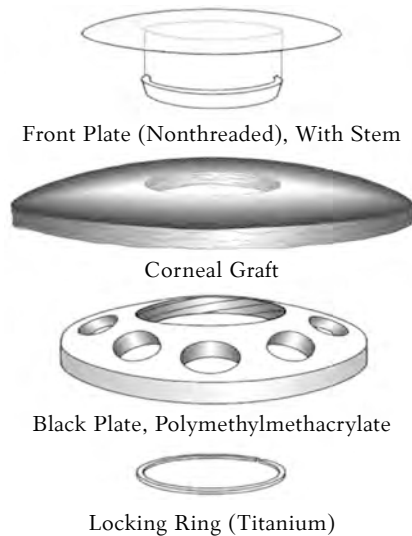


Fig. 2. Constituent parts of Boston type 1 keratoprosthesis

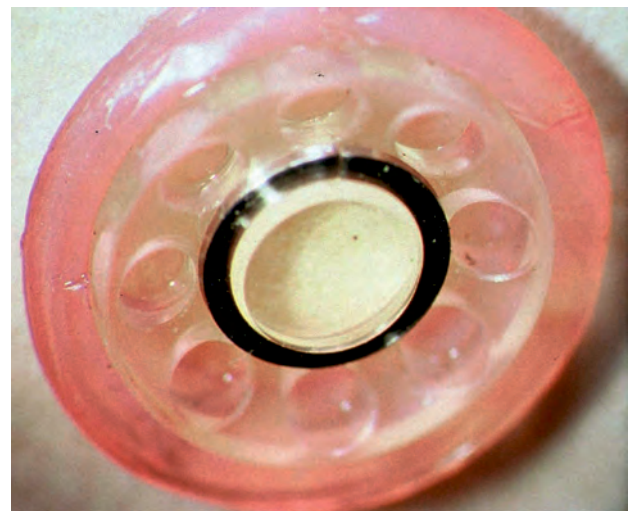


Fig. 3. Boston type 1 keratoprosthesis complex, an assembled corneal graft

Table 1. Intraoperative Characteristics and Procedures Performed in Patients Undergoing Boston Type 1 Keratoprosthesis Implantation

Characteristic	Patient				
	1	2	3	4	5
Date of KPro surgery	September 2009	September 2009	February 2010	June 2011	April 2012
Lens status	Phakic	Phakic	Pseudophakic	Aphakic	Pseudophakic
Keratoprosthesis Type	Aphakic Type 1 BKPro	Aphakic Type 1 BKPro	Pseudophakic Type 1 BKPro	Aphakic Type 1 BKPro	Pseudophakic Type 1 BKPro
Additional procedures during KPro surgery	ECCE performed, removal of the iris and retroiridial fibrotic membrane	ECCE performed	No	IOFB removal, anterior vitrectomy	Removal of secondary cataract with Soemmering ring
Complications during KPro surgery, management	Bleeding from the iris, stopped	No	No	No	No

KPro, keratoprosthesis; ECCE, extracapsular cataract extraction; IOFB, intraocular foreign body.

In one case (patient 1), after trephination of the cornea was carried out, it was found that the cornea was stuck to the iris. Its part was separated in a blunt way, but the remaining part of the iris at the 3- to 9-o'clock position was removed together with the cornea. A thick fibroid membrane was found between the iris and the lens that was separated from the lens.

In the case of an intraocular foreign body (IOFB) behind the iris, the IOFB was removed, and subsequent anterior vitrectomy was performed (patient 4).

In the pseudophakic eye, posterior capsular opacification that formed Elschnig pearls and a Soemmering ring was cleaned out with irrigation-aspiration under the intraocular lens with the intact posterior lens capsule at the end of the procedure (patient 5).

Later surgeries were performed if postoperative, nonsurgical complications occurred. Table 2 lists

the postoperative characteristics of the patients and the procedures that were performed.

A pars plana vitrectomy (patient 1) was performed according to the standard procedures, and the vitreous and the posterior lens capsule were removed.

Retroprosthetic membrane (RM) removal and the aspiration of secondary cataract were manually performed (patient 5).

During the first week after the surgery, the patients were followed up on a daily basis, then on a weekly basis during the first month, afterwards, once a month for half a year; and then every 2–3 months regularly.

After the day of the surgery, fluoroquinolone and 0.1% dexamethasone drops were prescribed 4 times a day. After 4 weeks, the frequency was decreased to twice a day. After 2 months, 0.1% chloramphenicol and 0.3% ciprofloxacin antibiotic drops were prescribed for regular use 2 times a day.

Table 2. Postoperative Characteristics and Procedures Performed of Patients Undergoing Boston Type 1 keratoprosthesis Implantation

Characteristic	Patient				
	1	2	3	4	5
Late postoperative complications, management	Secondary cataract formation, Nd:YAG laser capsulotomy; vitritis, pars plana vitrectomy	Retroprosthetic membrane formation, Nd:YAG laser membranectomy	No	No	Retroprosthetic membrane and secondary cataract formation, removed during repeated surgery
Ocular hypertension, management	Glaucoma medications	Glaucoma medications, transscleral cycloablation	Glaucoma medications	Glaucoma medications	Glaucoma medications

Table 3. Conservative Regimen of Patients After Boston Type 1 keratoprosthesis Implantation

Medication	Patient				
	1	2	3	4	5
Antibiotic	Levofloxacin	Levofloxacin	Levofloxacin	Chloramphenicol and Dexamethasone*	Chloramphenicol and Dexamethasone*
Hypotensive	Dorzolamide, Timolol	Dorzolamide, Timolol, Brimonidine	Betaxolol	Dorzolamide, Timolol	Dorzolamide, Timolol
Hormone	No	No	No	Yes	Yes
Other	No	Artificial tears	Artificial tears	No	No

*Oftan Dexa-Chlora eye drops as Chloramphenicol eye drops are not registered in Lithuania.

Postoperatively, IOP was evaluated by digital palpation of the globe as described by Banitt (14), as the optical components of the BKPro are rigid and inflexible, which prevents pneumotometry and applanation tonometry. In the case of elevated IOP, eye drops for glaucoma were used. Table 3 shows the postoperative eye drops constantly used by the patients.

The sutures were removed after an average of 14.1 months (range, 12 to 16 months; SD, 1.58). The soft contact lens that was placed on the eye after the surgery and changed once a month was cultured for fungi and bacteria.

The geometry and surface morphology of the IOFB was investigated with scanning electron microscopy (SEM) with a Hitachi 3400 N microscope. Information on the elemental and chemical state was received from x-ray photoelectron spectroscopy (XPS) measurements with a PHI 5000 Versaprobe instrument.

Table 4 summarizes the preoperative and postoperative Snellen VA for 5 eyes. Postoperatively, VA significantly improved in all 5 cases. The Snellen distance-corrected VA ranged from 0.1 to 1.0 on the first day after surgery (data of 5 eyes) and remained to be 0.1 to 1.0 after 12 months (data of 5 eyes) and 0.4 to 1.0 after 24 months (data of 3 eyes), while after 36 months, it was hand movements to 0.9 (data of 3 eyes). To improve the distance VA, the contact lens with -3.0 D power was used for permanent use in 2 cases: VA improved from 0.1 to 0.3 (patient 4) and 0.09 to 0.1 (patient 5).

Table 4. Preoperative and Postoperative Snellen Visual Acuity in Operated Eyes

Visual Acuity	Patient				
	1	2	3	4	5
1 day postoperatively	1.0	0.6	0.4	0.3*	0.1*
After 12 months	1.0	0.6	0.4	0.3*	0.1*
After 24 months	1.0	0.6	0.4	NA	NA
After 36 months	0.9†	HM‡	0.4	NA	NA

HM, hand movements; NA, not available.

*Contact lens with -3.0 D power was used; †persistent vitreous inflammation for 6 months (after pars plana vitrectomy, VA increased to 0.9); ‡failed to appear in consultations and did not use glaucoma drops.

However, due to late postoperative complications (described below) (patients 1 and 2), VA deteriorated to counting fingers and hand movements after 36 months (due to vitritis and ocular hypertension). After vitritis treatment (patient 1), VA increased to 0.9.

The IOFB was removed and examined with SEM, and its geometrical structure is shown in Fig. 4. The length of the IOFB was approximately 4.86 mm and had a width ranging from 1.92 mm to 2.53 mm. An analysis of the elemental and chemical state that was done by XPS revealed that the origin of the IOFB was PMMA. There was an additional peak at 287.7 eV, which was associated with the formaldehyde functional group (Fig. 5). The presence of this group can be explained because of an aging effect induced by sample surface irradiation during XPS measurements. The weight of the IOFB was




Fig. 4. Scanning electron microscopy view of the intraocular foreign body

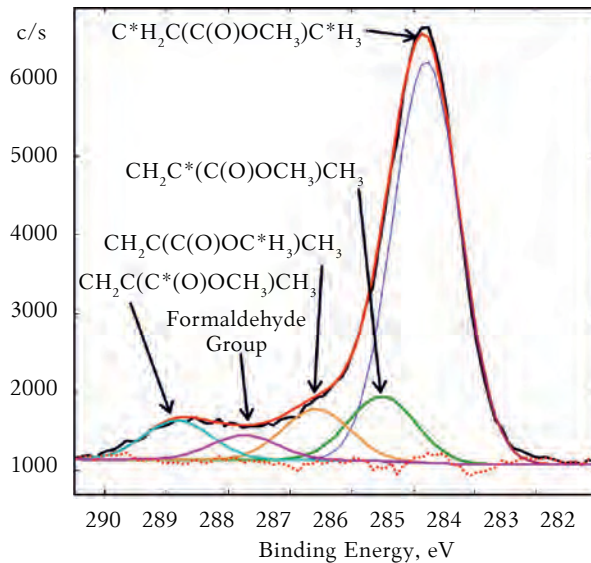


Fig. 5. C_{1s} XPS spectra of the intraocular foreign body surface with fitted peaks associated with the repeating structural units

0.00476 g (weighed with Libra METTER TOLEDO, model XS DUAL RANGE).

No early postoperative complications occurred. In all cases, there were one or more late nonsurgical, postoperative complications, including RM formation (n=2), secondary cataract development (n=2), vitritis (n=1), and ocular hypertension (n=5).

The diagnosis of the RM (patients 2 and 5) was made based on the development of the avascular membrane behind the posterior surface of the stem of the BKPro. Nd:YAG laser membranectomy of RM was performed when opacification became visually significant (patient 2). No significant complications occurred after this procedure. The RM in the patient 5 was removed surgically.

Table 5. Postoperative Cup-to-Disc Vertical Diameter Ratio

Cup-to-Disc Ratio at	Patient				
	1	2	3	4	5
1 month after surgery	0.7	0.6	0.5	0.6	1.0
12 months after surgery	0.7	0.6	0.5	0.6	1.0
24 months after surgery	0.7	0.6	0.5	NA	NA
36 months after surgery	0.7	1.0*	0.5	NA	NA

*The patient failed to use glaucoma drops. NA, not available.

Secondary cataract was treated with Nd:YAG laser capsulotomy (patient 1) and surgical cleaning (patient 5). After the Nd:YAG laser capsulotomy (patient 1), vitritis was documented. Despite intensive treatment with topical steroids, persistent vitreous inflammation remained visually significant for

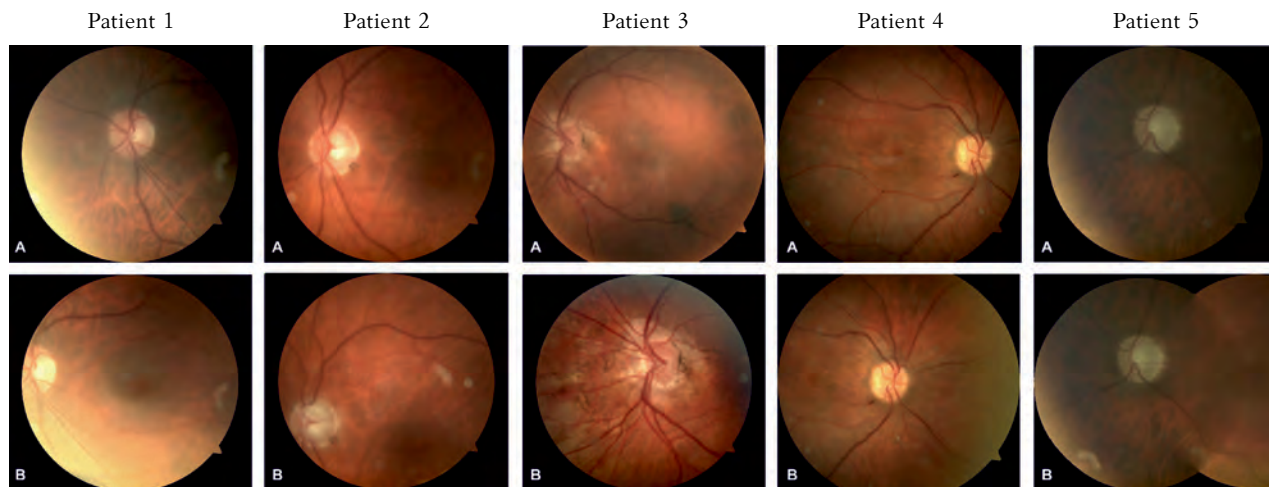


Fig. 6. Photographs of the optic nerve after Boston type 1 keratoprosthesis surgery A, first month after surgery; B, last visit photographs.

6 months, and VA deteriorated to counting fingers. Pars plana vitrectomy was then performed. Two weeks after the vitrectomy, the posterior chamber and vitreous cavity became more transparent, and the distance VA improved to 0.9. After the surgical aspiration of secondary cataract, the eye remained without the signs of inflammation.

In all cases, elevated IOP was found. To reduce ocular hypertension, topical medications for glaucoma were used successfully in all except for one case. After 2.5 years of regular follow-ups, one of the patients discontinued using glaucoma drops for more than 6 months (patient 2). The vertical cup-to-disc ratio increased from 0.6 to 1.0 during this period, and IOP increased despite the fact that glaucoma therapy was initiated again. Remnants of a temporal visual field were left with a decreased VA from 0.6 to hand movements from the temporal side. After the transscleral cyclophotocoagulation, IOP became normal and remained normal during the 6-month follow-up.

The retina and the optic nerve were examined through the clear optical part of the BKPro, and no significant lesions were found in the retina, but an increased vertical cup-to-disc ratio from 0.5 to 1.0 was observed in all cases. The postoperative characteristics of the optic nerve are described in Table 5. The postoperative images of the eye fundus are presented in Fig. 6.

The retention of the soft contact lens was very good in 4 cases, and very poor in 1 case (patient 2) due to the irregular and abnormal eye surface. In this particular case, the contact lens was lost 1 to 2 weeks after it was fitted. The contact lens was replaced during every follow-up for 2 years. Later, the patient refused to use it again due to irritation and foreign body sensation.

The contact lens culture was negative for bacteria and fungus in all cases.

Retention of the BKPro was 100%. Tilt of the BKPro was noticed in 1 case due to ocular hypertension (patient 2). The BKPro regained a normal position after IOP was normalized.

The patients did not complain concerning the constant use of eye drops. There was no need to replace the BKPro.

The patients did not complain concerning the constant use of eye drops or constricted visual field and were satisfied with the cosmetic results after the surgery. Photographs of the 5 operated eyes are shown at different follow-ups in Fig. 1.

Discussion

This article discusses the surgical procedures, operative and postoperative complications, and visual outcomes during the 36-month follow-up after the implantation of the type 1 BKPro in 5 patients from Lithuania.

Previous studies have reported that the most common indication for BKPro surgery was corneal graft failure (44% to 59%) (15, 16) followed by thermal (28.6%) (17) and chemical injury (27%) (15), Stevens-Johnson syndrome (14.3%) (17), and aniridia (23.8%) (17). In our cases, the most common indication also was corneal graft failure (60%) followed by chemical injury (20%) and thermal mechanical injury (20%).

In a study by Aldove et al. (15), 38% of eyes were pseudophakic and 62% were aphakic. The procedures most commonly performed in conjunction with BKPro implantation were anterior vitrectomies (14.2%), tube shunt implantations (11.5%), and intraocular lens removals (7.1%). Other study (16) reported tube shunt implantations (30%) and iridoplasty (8%) to be most common. No significant intraoperative complications occurred in this series. In our study, 40% of eyes were phakic, 40% were pseudophakic, and 20% were aphakic. Cataract extraction was performed in 40% and anterior vitrectomy in 20% of the cases, while secondary cataract during surgery was removed in 20% of the cases, and part of the iris, in 20%.

In one case, the IOFB was found during the surgery (the eye was injured with homemade explosives and failed 1 keratoplasty procedure). The IOFB was not observed during the preoperative examination with an x-ray (as PMMA is not a radiocontrast agent) and B-mode ophthalmic ultrasonography (because of the blind zone) as well as during the first penetrating keratoplasty. The IOFB was localized just behind the iris and could push the iris forward and lead to anterior synechia.

According to the literature sources, glaucoma was the most common pre-existing comorbidity with an incidence ranging from 40% to 73% (15, 16). In our study, it accounted for 40%. This could be explained by intraocular changes occurring after eye burns, traumas, and previous keratoplastic surgeries, which initiates the development of secondary glaucoma.

In our study, the preoperative VA was 0.01 in 20% of cases and hand movements or light perception in 60% and 20% of cases, respectively. In the study by Aldove et al. (15), the VA was light perception, hand movements, and counting fingers in 50%, 17%, and 31% of the cases, respectively, while 2% of the cases had a VA of 0.05 or better. The difference in the preoperative VA could be explained by the very strict selection of patients in our study. We tried to enroll the patients with a possible better postoperative prognosis. An improvement in VA after the surgery was dramatic in our study as in other international study (15). VA improved from 0.4 to 1.0 in 60% of the cases and from 0.1 to 0.3 in 40% of the cases in our study at the 12-month follow-

Table 6. Antibiotic Use Scheme After BKPro Type 1 Implantation*

Suggested Maintenance Antibiotic Prophylaxis Regimen for KPro Patients			
Class	Preferred Antibiotic Choice	Alternative Antibiotic Choice	Third Choice (Greater Toxicity)
A	1% Chloramphenicol, ONE drop TWICE a day	Trimethoprim sulfate 0.1%/Polymyxin B (Polytrim) suspension ONE drop TWICE a day	Clindamycin 0.3% ONE drop TWICE a day
B	0.3% Ciprofloxacin, ONE drop TWICE day (may substitute with 0.3% ofloxacin levofloxacin 0.5%, moxifloxacin)	OR Bacitacin Zinc/Polymyxin B (Polysporin) ointment (at night before sleep ONLY)	Tobramycin 0.3% ONE drop TWICE a day (short-term use only)

*Reprinted with permission from Amet et al. (13).

up. The study by Aldove et al. showed that VA improved from 0.4 to 1.0 in 29% of the cases, from 0.1 to 0.3 in 22% of the cases, and less than 0.1 in 49% of the cases after 12 months. VA remained the same after 24 months. It was observed that a large number of eyes with good restored VA after the surgery remained constant up to 24 months and thus indicated a low incidence of postoperative complications, such as retinal detachment, sterile vitritis, cystoids macular edema, etc., resulting in the loss of vision.

The most common postoperative complications after BKPro implantation are reported to be RM formation ranging from 26.7% to 65% (15–17), elevated IOP ranging from 13.9% to 38% (15, 16), and sterile corneal necrosis (17.8%) (15). Correspondingly, Nd:YAG laser membranectomy (9.9%), glaucoma surgery (8.9%), and BKPro replacement (20.8%) were the most commonly performed procedures to manage these complications (15). In our study, the RM developed in 40% of the cases (which was successfully removed) and no corneal necrosis developed, but IOP was elevated in 100% of the cases. Glaucoma was successfully managed with glaucoma medications in 4 cases, and in 1 case, cyclophotocoagulation was performed. Glaucoma in patients with the BKPro can occur and progress due to a number of reasons. Many of these reasons involve underlying damage to the angle (14). Progressive closure of the angle is presumed to be a causative factor. In most recipients that underwent penetrating keratoplasty, some degree of synechial angle closure already exists. Further problems of the angle can occur as the anterior segment becomes crowded once the back plate has been placed in the close proximity to the iris. Moreover, primary glaucoma, which had not been diagnosed before, cannot be excluded. Topical glaucoma medications may be less effective after BKPro implantation due to the replacement of a portion of the ocular surface by a PMMA optic.

In the study by Aldove et al. (15), infectious endophthalmitis occurred in 8.9% of the cases; in the studies by Ramchandran et al. (18) and Chew (16),

in 7.1% and 11%, respectively; sterile vitritis was diagnosed in 4.0% (15) and 12.9% of the cases (19) after BKPro implantation. A decision was made to perform a vitrectomy in all cases. In our study, no infectious endophthalmitis was detected, but sterile vitritis occurred in 20% of the cases and was managed by performing a pars plana vitrectomy. VA was restored to 0.9.

After BKPro implantation, the patient must use antibiotic eye drops for the rest of his/her life. Antibiotic eye drops effective against both gram-positive and gram-negative microorganisms are recommended. An antibiotic regimen recommended by Amet et al. indicates to use one antibiotic from class A and one from class B (Table 6) (13). In our cases, the patients that were operated on were administered Levofloxacin and Chloramphenicol eye drops.

Aldove et al. reported the BKPro retention rate to be 80.5% (removal average 6.43 months after implantation) (15). In the study by Chew et al. (16), the retention rate was 97%. In our study, the BKPro was tilted in 1 case with uncontrolled IOP, but after lowering the IOP, it became stable again and had a retention rate 100%.

Conclusions

Currently, BKPro is the first choice for the restoration of vision in corneal blindness for the most complicated cases in this group. Based on VA and stabilized KPro retention (100%) in our cases, the BKPro is an effective tool to improve vision in selected patients who are considered poor candidates for traditional corneal transplants. The results achieved with the BKPro implants in the Department of Ophthalmology, Lithuanian University of Health Sciences, seem to be similar to those achieved internationally. The anatomical and visual functions of the eyes were stable after BKPro implantation, though for a longer follow-up period, additional surgical procedures may be required.

Statement of Conflict of Interest

The authors state no conflict of interest.

References

1. Schwab L. Eye care in developing nations. 3rd ed. San Francisco: American Academy of Ophthalmology; 1999.
2. Preferred practice patterns, cornea panel. Corneal opacification and ectasia. San Francisco: American Academy of Ophthalmology; 2000.
3. Dandona L, Naduvilath TJ, Janarthana M, Ragu K, Rao GN. Survival analysis and visual outcome in a large series of corneal transplants in India. *Br J Ophthalmol* 1997;81:726-31.
4. Pavan-Langston D. Viral disease of the ocular anterior segment: basic science and clinical disease. In: Foster S, Azar D, Dohlman C, editors. *The Cornea*. 4th ed. Philadelphia, Pa: Lippincott Williams & Wilkins; 2005. p. 297-397.
5. Giles CL, Henderson JW. Keratoprosthesis: current status. *Am J Med Sci* 1967;253:239-42.
6. Blodi FC. Cataract surgery. In: Albert DM, Edwards DD, editors. *The history of ophthalmology*. Cambridge, MA: Blackwell Scientific; 1996. p. 165-77.
7. Stone W Jr, Herbert E. Experimental study of plastic material as replacement for cornea: preliminary report. *Am J Ophthalmol* 1953;36:168-73.
8. Macpherson DG, Anderson JM. Keratoplasty with acrylic implant. *Br Med J* 1953;1:330-53.
9. Stone W Jr. Alloplasty in surgery of the eye. *N Engl J Med* 1958;258:486-90.
10. Girard LJ, Hawkin RS, Nieves R, Borodofsky T, Grant C. Keratoprosthesis: a 12-year follow-up. *Trans Sect Ophthalmol Am Acad Otolaryngol* 1977;83:252-67.
11. Cardona H. Keratoprosthesis with a plastic fiber meshwork supporting plate. Report of an experimental and comparative histologic study. *Am J Ophthalmol* 1967;64:228-33.
12. Boston KPro News, Fall 2011, no 8. Available at: URL: www.masseyeandear.org. Accessed October 25, 2012.
13. Amet JD, Pineda R, Lawson B, Belau I, Dohlman CH. The Boston Keratoprosthesis International Protocol. Version 2, 2009; June 15. Available at: URL: http://www.masseyeandear.org/gedownload!/KPro%20International%20Protocol2.pdf?item_id=5816015
14. Banitt M. Evaluation and management of glaucoma after keratoprosthesis. *Curr Opin Ophthalmol* 2011;22:133-6.
15. Aldove JA, Sangwan VS, Basu S, Basak SK, Hovakimyan A, Gevorgyan O, et al. International results with the Boston type I keratoprosthesis. *Ophthalmology* 2012;119:1530-8.
16. Chew FH, Ayres BD, Hammersmith KM, Rapuano CJ, Laibson PR, Myers JS, et al. Boston keratoprosthesis outcomes and complications. *Cornea* 2009;28:989-96.
17. Kang JJ, Cruz J, Cortina MS. Visual outcomes of Boston keratoprosthesis implantation as the primary penetrating corneal procedure. *Cornea* 2012;31:1436-40.
18. Ramchandran RS, DiLoreto DA, Chung MM, Kleinman DM, Plotnik RP, Graman P, et al. Infectious endophthalmitis in adult eyes receiving Boston type I keratoprosthesis. *Ophthalmology* 2012;119:674-81.
19. Goldman RD, Hubshman J, Aldave AJ, Chiang A, Huang JS, Bourges J, et al. Postoperative posterior segment complications in eyes treated with the Boston type I keratoprosthesis. *Retina* 2013;33:532-41.

Received 28 November 2012, accepted 30 May 2013