

Evaluation of Axonal Optic Nerve Damage Using Visual Evoked Potentials and Optical Coherence Tomography in Patients With Multiple Sclerosis

Daina Pastare^{1,2}, Ieva Ķire^{3,4}, Renārs Erts⁵, Guna Laganovska^{3,4}, Andrejs Millers^{1,2}

¹Department of Neurology and Neurosurgery, Riga Stradins University, ²Department of Neurology, Pauls Stradins Clinical University Hospital, ³Department of Ophthalmology, Riga Stradins University, ⁴Department of Ophthalmology, Pauls Stradins Clinical University Hospital, ⁵Department of Physics, Riga Stradins University, Latvia

Key Words: multiple sclerosis; optic nerve; axonal damage; visual evoked potentials; optical coherence tomography.

Summary. Background and Objective. Axonal tissue impairment plays a substantial role in the development of disability in multiple sclerosis. The aim of our study was to analyze the clinical utility of visual evoked potentials (VEP) and optical coherence tomography (OCT) in the diagnosis of optic nerve axonal damage and to determine the correlation between the retinal nerve fiber layer at the temporal quadrant (RNFLT) thickness and the VEP amplitude in multiple sclerosis patients with and without a history of acute optic neuritis (ON).

Material and Methods. This cross-sectional study included 69 relapsing-remitting patients with multiple sclerosis from Pauls Stradins Clinical University Hospital, who were divided into 2 groups: with and without a history of ON. The RNFLT thickness and the VEP amplitude were measured.

Results. A total of 25 clinically affected eyes were studied. VEP showed a higher sensitivity (64%) than OCT (50%) in supporting a clinical diagnosis of ON. A significant correlation was found between the RNFLT thickness in the temporal segment and the average VEP amplitude both in the eyes of MS patients with ($r_s=0.42$, $P=0.01$) and without a history of ON ($r_s=0.44$, $P<0.001$).

Conclusions. The evidence from this study suggests that diagnostics of optic nerve axonal damage is feasible by means of using the average VEP amplitude instead of OCT alone. However, the combination of VEP and OCT increases the chance to confirm the existence of ON. A significant correlation was found between structural and functional vision parameters for both patients with and without a history of ON.

Introduction

Multiple sclerosis (MS) is a chronic inflammatory disease of the central nervous system that often affects young patients and leads to a progressive neurological defect. Relatively recent studies have confirmed that the development of long-term disability in MS is not mostly related to demyelination, but to an axonal and neuronal loss (1–4). The necessity for the closer analysis of axonal tissue arises from the fact that there is a growing need to develop biomarkers for monitoring the disease progress and modeling the prognosis as well as the evaluation of treatment effectiveness (5). An acute episode of optic neuritis (ON) is observed in 30%–70% of MS patients during the course of the disease (6, 7). The damage of vision pathways is an ideal model for neurodegenerative processes in MS (8), which theoretically might reflect degenerative changes in the brain. Optical coherence tomography (OCT) captures images from the retina (9), the only place in a human body where the investigation of the axonal tissue layer is possible

in vivo regardless of the myelin sheath condition. It has repeatedly been shown that damage to the retinal nerve fiber layer at the temporal quadrant (RNFLT) can be detected even in patients without a history of an acute episode of ON, suggesting of subclinical and progressive damage of the afferent visual system (10–13). A neurophysiological method – visual evoked potentials (VEPs) – has already been used for the evaluation of axonal optic nerve damage for many years. This method was also mentioned in the McDonald's criteria used for the diagnostics of MS in 2001 and 2005 (14, 15). The loss of axonal tissue is characterized by changes in the VEP amplitude, but the prolongation of latency refers to optic nerve demyelination (16). The aim of our study was to analyze the clinical utility of VEP and OCT in the diagnosis of optic nerve axonal damage and to determine the correlation between the RNFLT thickness, which is considered a structural parameter of the retina, and the VEP amplitude, a functional visual parameter, in MS patients with and without a history of acute ON.

Material and Methods

The cross-sectional study included 69 relapsing-remitting MS patients with and without a history of

Correspondence to D. Pastare, Department of Neurology, Pauls Stradins Clinical University Hospital, Pilsonu 13, 1002 Riga, Latvia. E-mail: daina.pastare@gmail.com

ON, recruited from the Multiple Sclerosis Center at Pauls Stradins Clinical University Hospital. A history of ON was documented based on symptoms and clinical signs (17). However, not all patients had a documented episode of ON. The study involved only patients with an episode of ON observed ≥ 6 months before examinations. The mean time after an episode of ON was 19.2 months. Patients were not given corticosteroid therapy for at least 30 days before the study, while some patients continued immunomodulatory treatment. Patients suffering from neurological diseases other than MS and ophthalmological or systemic ones that could affect the afferent visual system were not included into the study. MS diagnosis was established by a neurologist according to the McDonald's criteria. A neurological examination with impairment assessed using the Kurtzke Expanded Disability Status Scale (EDSS) was performed. The EDSS is based on data from the neurological examination and patient's ability to walk. Scores range from 0 (indicating no neurologic impairment) to 10 (death due to MS). An experienced ophthalmologist performed a complete ophthalmologic examination: determination of visual acuity, measurement of ocular tension, biomicroscopy of the anterior pole, and visual field testing.

All the patients underwent the pattern-reversal VEP stimulation in a dark and quiet room for both eyes by using the RETI-port 21 (Roland Consult, Germany). Subjects were seated at a distance of 100 cm from the monitor screen and had to fix the gaze at the red dot in the center of the screen. Full correction of refraction was performed if necessary. Active and reference gold disc electrodes were placed at Oz and Fz, respectively, according to the international 10–20 system. The monocular stimulation of vision with the black-white video monitor at a frequency of 1.6 Hz was performed, and stimulus patterns were presented on a video screen subtending 12×15 degrees of visual angle with a pattern contrast of 99%. The average potentials were filtered and analyzed by means of repeated (100) stimulations 2 times for each eye. N75/P100 amplitudes were measured. The VEP amplitude was evaluated based on the laboratory-designed reference value, to assume amplitude under $8.2 \mu\text{V}$ as an abnormal one.

The RNFLT thickness in 6 standard sectors (temporal, temporal upper, temporal lower, nasal, nasal upper, and nasal lower) was measured for all subjects on OCT (Heidelberg Engineering SPECTRALIS) using the TruTrack™ active eye-tracking system. All the scans were performed by the same experienced ophthalmologist. Poor-quality scans were excluded. The RNFLT thickness in the reference range was represented by the green background. The presence of the defect was determined based on the machine normative database; a red colored quadrant was classified as abnormal.

The patients with MS were divided into 2 groups. The first group included 25 patients with a clinical history of unilateral ON. The second group comprised 44 patients without a history of ON. The control group consisted of 14 age-matched individuals.

Descriptive statistics were used for data presentation and analysis. The chi-square test or the Fisher exact test was used to evaluate qualitative variables. Quantitative variables for both the groups were analyzed using the Student *t* test. Correlation was assessed by the Spearman correlation. The receiver operating characteristic (ROC) curve and the area under the curve were analyzed. The MedCalc 12.0 software was used to estimate statistically significant differences between the areas under ROC curves. The level of significance was set at $P < 0.05$.

Results

The study included 25 eyes affected by ON, 25 contralateral, unaffected eyes of the same group, and 88 eyes of MS patients without a history of ON. The age of the patients ranged from 17 to 65 years. There was no significant age difference comparing the study groups ($t = 1.90$, $P = 0.06$). The mean EDSS score of MS patients was 1.94. The disease duration ranged from 0 to 400 months. The clinical and demographic characteristics of the patients included in the study are summarized in Table 1.

Table 2 shows the comparison of the mean VEP amplitude between MS patients with and without a history of ON.

Table 1. Clinical and Demographic Characteristics of the Study Population

Characteristic	ON Affected n=25	ON Unaffected n=44
Age, mean (SD), years	39.54 (10.35)	38.32 (10.77)
Men/women, n	10/15	16/28
Disease duration, mean (range), months	57.61 (0–384)	52.12 (0–400)
Months from ON episode, mean (range)	19.2 (6–120)	0
EDSS, mode (range)	3.5 (0–6)	0 (0–6)

EDSS, Expanded Disability Status Scale; ON, optic neuritis.

Table 2. The Mean Visual Evoked Potential Amplitude and Retinal Nerve Fiber Layer Thickness for Eyes Affected and Unaffected by Optic Neuritis

Parameter	ON Affected n=25	ON Unaffected n=88	<i>P</i> value	Controls n=28
VEP amplitude, μV	6.59 (4.21)	10.32 (4.80)	<0.001	13.62 (4.45)
RNFLT thickness, μm	53.64 (15.05)	62.47 (13.92)	0.001	72.71 (7.71)

Values are mean (standard deviation). VEP, visual evoked potential; RNFLT, retinal nerve fiber layer at the temporal quadrant; ON, optic neuritis.

A moderate, positive, and significant correlation was found between the RNFLT thickness and the mean VEP amplitude in the MS patients with a history of ON ($r_s=0.42, P=0.01$) as well as in the MS patients without a history of ON ($r_s=0.44, P<0.001$). The abovementioned relationships are depicted in Fig. 1. However, no significant correlation was observed in the control group ($P=0.47$).

A separate analysis of the MS patients' population with a history of ON revealed an abnormally reduced RNFLT thickness in 16 ON-affected eyes (64%), while a decrease in the mean VEP amplitude was observed in 18 cases (72%).

Similar results were obtained studying the other ON-unaffected eye of the same patients' population, to assess a subclinical optic nerve involvement. The reduced RNFLT thickness was found in 6 eyes (24%) and the decreased mean VEP amplitude in 11 cases (44%).

By using the combination of both methods in the ON-affected eyes, abnormalities were detected in 13 cases (52%). However, regarding the ON-unaffected eyes, optic nerve damage was documented in 4 eyes (16%).

While seeking for an answer to the question how high the possibility is to make mistakes by using only one method, it turned out that in the ON-affected eyes with a normal mean VEP amplitude, the OCT method identified abnormalities in 3 cases (12%), while in case of the normal RNFLT thickness, the average VEP amplitude was reduced in 5 cases (20%). Similarly analyzing the other ON-unaffected eyes, the average VEP amplitude was normal with an abnormal RNFLT thickness in 2 cases (8%), while 7 cases (28%) had a reduced average VEP amplitude with the normal RNFLT thickness.

It was observed that between ON history and presence of a reduced VEP amplitude there exists a proportional significant relevance ($P=0.04$), and such relevance was approved also between the history of ON and the presence of the decreased RNFLT thickness ($P=0.03$).

Referring to the ROC curve analysis and setting the clinical ON signs as the gold standard, the sensitivity and specificity of the VEP amplitude in this case were 64% and 90%, respectively, with the diagnostic accuracy being 74%. Similarly, measuring the RNFLT thickness and setting the ON clinical signs

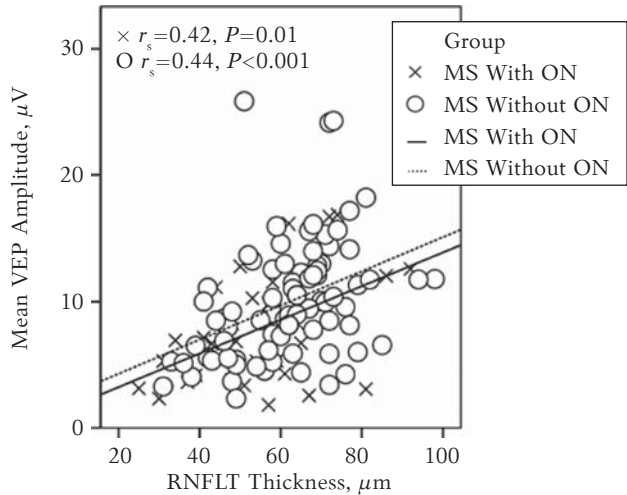


Fig. 1. Correlation between mean visual evoked potential (VEP) amplitudes and retinal nerve fiber layer at the temporal quadrant (RNFLT) thickness

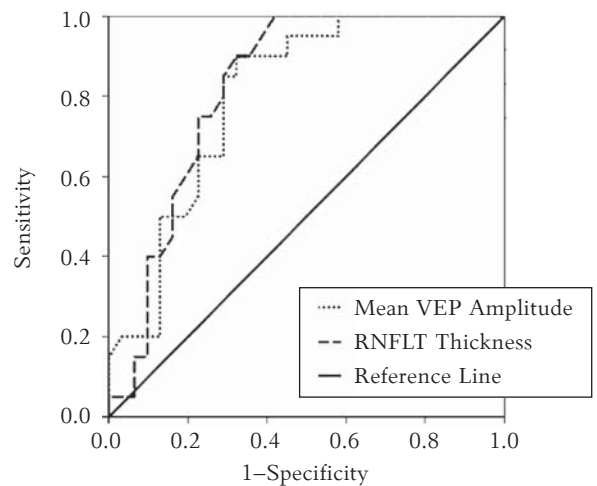


Fig. 2. Assessment of suitability of retinal nerve fiber layer at the temporal quadrant (RNFLT) thickness and average visual evoked potential (VEP) amplitude in ON diagnostics using ROC curves

as the gold standard, the corresponding values of OCT were 50%, 100%, and 73%, respectively. The positive predictive value of the RNFLT thickness measured by OCT was greater than that of the VEP amplitude (Table 3).

The ROC curve analysis showed no significant difference ($P=0.75$) in the area under the ROC curve comparing the RNFLT thickness (AUC=0.82; 95% CI, 0.70 to 0.93, $P<0.001$) and the mean VEP

Table 3. Comparison of Diagnostic Accuracy

Parameter	Sensitivity %	Specificity %	Accuracy %	Positive Predictive Value %	Negative Predicted Value %
Lowered VEP amplitude	64	90	74	90	62
Reduced RNFLT thickness	50	100	73	100	63

VEP, visual evoked potential; RNFLT, retinal nerve fiber layer at the temporal quadrant.

amplitude (AUC=0.80; 95% CI, 0.68 to 0.92, $P<0.001$) in determining ON (Fig. 2).

Discussion

Similar to previous studies (11–13, 18, 19), our study confirms that subclinical axonal optic nerve damage in ON-unaffected eyes can be diagnosed by using the measurements of both the VEP amplitude and the RNFLT thickness. These results support the need to apply these tests to MS patients even without a history of ON in order to get the picture of axonal optic nerve lesions. In addition, both of these methods are useful in equivocal clinical situations, when the symptoms of ON are weakly expressed or the patient is not able to assess them adequately due to cognitive impairment.

Relying on the data obtained, our study showed an equally strong correlation between the mean VEP amplitude and the RNFLT thickness both in the eyes with or without a history of ON. In addition, our results indicated a correlation between the reduced VEP amplitude and decreased RNFLT thickness in the patients with a history of ON. This concurs with the data in literature and supports the use of these 2 methods to detect ON. Both the measurements of the RNFLT thickness by OCT and the VEP amplitude in the AUC analysis are equally qualitative parameters for the diagnostics of optic nerve damage due to ON. However, using the OCT method, optic nerve damage was diagnosed in fewer cases as compared with the VEP method both in the eyes affected and unaffected by ON.

In our study, OCT to confirm clinical ON had sensitivity by 14% lower as compared with VEP, and it was lower than that reported in the literature (18). Nevertheless, OCT had a higher positive predictive value, which can be explained by well-designed cutoff values in the device normative database. One of the explanations for the low sensitivity of OCT

could be the fact that only the anterior visual pathway can be assessed by this test, meanwhile the VEP can provide an insight into the integrity of both the anterior and posterior visual pathways. Moreover, it should be taken into account that after an ON episode, axonal damage could be secondary to demyelination, but the reduction in the RNFLT thickness proceeds retrograde and is therefore not always complete. To improve the sensitivity of OCT, some authors (20–22) have recently offered the measurements of the neuronal ganglion cell layer and the inner plexiform layer, which should indicate axonal damage more accurately than the measurements of the RNFLT, as these structures contain no additional glial tissues and blood vessels (23). Mistakenly thicker RNFLT could also be caused by possible glial tissue replacement for axonal tissue loss, which is included in the total RNFLT thickness. However, it should be noted that the measurements of the ganglion cell neuronal layer and the inner plexiform layer are possible only through manual segmentation, which is a relatively time-consuming process and therefore may be hardly ever applied in clinical practice.

Conclusions

The obtained results suggest that despite a significant correlation between the RNFLT thickness and the VEP amplitude, the diagnosis of both clinical and subclinical optic nerve damages is made more convincingly by using VEP. From this conclusion it follows that if circumstances require using a single method for the approval of an ON history, VEP is more preferred. However, the combination of the VEP and OCT methods would facilitate the confirmation of ON preexistence.

Statement of Conflict of Interest

The authors state no conflict of interest.

References

1. Trapp BD, Peterson J, Ransohoff RM, Rudick R, Mork S, Bo L. Axonal transection in the lesions of multiple sclerosis. *N Engl J Med* 1998;338:278–85.
2. Pirko I, Lucchinetti CF, Sriram S, Bakshi R. Gray matter involvement in multiple sclerosis. *Neurology* 2007;68:634–42.
3. Fisniku LK, Chard DT, Jackson JS, Anderson VM, Altmann DR, Miszkiel KA, et al. Gray matter atrophy is related to long-term disability in multiple sclerosis. *Ann Neurol* 2008;64:247–54.
4. Siffrin V, Vogt J, Radbruch H, Nitsch R, Zipp F. Multiple sclerosis – candidate mechanisms underlying CNS atrophy. *Trends Neurosci* 2010;33:202–10.
5. Fernandez O. Integrating the tools for an individualized prognosis in multiple sclerosis. *J Neurol Sci* 2013;331:10–3.
6. Balcer LJ. Clinical practice. Optic neuritis. *N Engl J Med* 2006;354:1273–80.
7. Frohman EM, Frohman TC, Zee DS, McColl R, Galetta S. The neuro-ophthalmology of multiple sclerosis. *Lancet Neurol* 2005;4:111–21.
8. Sakai RE, Feller DJ, Galetta KM, Galetta SL, Balcer LJ. Vision in multiple sclerosis: the story, structure-function correlations, and models for neuroprotection. *J Neuroophthalmol* 2011;31:362–73.
9. Jindahra P, Hedges TR, Mendoza-Santiesteban CE, Plant GT. Optical coherence tomography of the retina: applications in neurology. *Curr Opin Neurol* 2010;23:16–23.
10. Parisi V, Manni G, Spadaro M, Colacino G, Restuccia R, Marchi S, et al. Correlation between morphological and functional retinal impairment in multiple sclerosis patients. *Invest Ophthalmol Vis Sci* 1999;40:2520–7.
11. Trip SA, Schlottmann PG, Jones SJ, Altmann DR, Garway-Heath DF, Thompson AJ, et al. Retinal nerve fiber layer axonal loss and visual dysfunction in optic neuritis. *Ann Neurol* 2005;58:383–91.
12. Fisher JB, Jacobs DA, Markowitz CE, Galetta SL, Volpe NJ, Nano-Schiavi ML, et al. Relation of visual function to retinal nerve fiber layer thickness in multiple sclerosis. *Ophthalmology* 2006;113:324–32.

13. Talman LS, Bisker ER, Sackel DJ, Long DA Jr, Galetta KM, Ratchford JN, et al. Longitudinal study of vision and retinal nerve fiber layer thickness in multiple sclerosis. *Ann Neurol* 2010;67:749-60.
14. McDonald WI, Compston A, Edan G, Goodkin D, Hartung HP, Lublin FD, et al. Recommended diagnostic criteria for multiple sclerosis: guidelines from the International Panel on the diagnosis of multiple sclerosis. *Ann Neurol* 2001; 50:121-7.
15. Polman CH, Reingold SC, Edan G, Filippi M, Hartung HP, Kappos L, et al. Diagnostic criteria for multiple sclerosis: 2005 revisions to the "McDonald Criteria". *Ann Neurol* 2005;58:840-6.
16. You Y, Klistorner A, Thie J, Graham SL. Latency delay of visual evoked potential is a real measurement of demyelination in a rat model of optic neuritis. *Invest Ophthalmol Vis Sci* 2011;52:6911-8.
17. The clinical profile of optic neuritis. Experience of the Optic Neuritis Treatment Trial. Optic Neuritis Study Group. *Arch Ophthalmol* 1991;109:1673-8.
18. Naismith RT, Tutlam NT, Xu J, Shepherd JB, Klawiter EC, Song SK, et al. Optical coherence tomography is less sensitive than visual evoked potentials in optic neuritis. *Neurology* 2009;73:46-52.
19. Klistorner A, Arvind H, Nguyen T, Garrick R, Paine M, Graham S, et al. Axonal loss and myelin in early ON loss in postacute optic neuritis. *Ann Neurol* 2008;64:325-31.
20. Davies EC, Galetta KM, Sackel DJ, Talman LS, Frohman EM, Calabresi PA, et al. Retinal ganglion cell layer volumetric assessment by spectral-domain optical coherence tomography in multiple sclerosis: application of a high-precision manual estimation technique. *J Neuroophthalmol* 2011;31:260-4.
21. Seigo MA, Sotirchos ES, Newsome S, Babiarz A, Eckstein C, Ford E, et al. In vivo assessment of retinal neuronal layers in multiple sclerosis with manual and automated optical coherence tomography segmentation techniques. *J Neurol* 2012;259:2119-30.
22. Walter SD, Ishikawa H, Galetta KM, Sakai RE, Feller DJ, Henderson SB, et al. Ganglion cell loss in relation to visual disability in multiple sclerosis. *Ophthalmology* 2012;119: 1250-7.
23. Hood DC, Salant JA, Arthur SN, Ritch R, Liebmann JM. The location of the inferior and superior temporal blood vessels and interindividual variability of the retinal nerve fiber layer thickness. *J Glaucoma* 2010;19:158-66.

Received 18 September 2013, accepted 30 November 2013