

Available online at www.sciencedirect.com

ScienceDirect

journal homepage: <http://www.elsevier.com/locate/medici>

Review

Familial hematuria: A review

Paulína Plevová^{a,*}, Josef Gut^b, Jan Janda^c

^aDepartment of Medical Genetics, University Hospital Ostrava, Ostrava, Czechia

^bDepartment of Paediatrics, Hospital Česká Lípa, Česká Lípa, Czechia

^cDepartment of Pediatrics, Motol University Hospital and 2nd Faculty of Medicine, Charles University in Prague, Prague, Czechia

ARTICLE INFO

Article history:

Received 20 July 2016

Received in revised form

23 December 2016

Accepted 16 January 2017

Available online 31 January 2017

Keywords:

Alport syndrome

Thin basement membrane nephropathy

Familial glomerular hematuria

COL4A4

COL4A5

ABSTRACT

The most frequent cause of familial glomerular hematuria is thin basement membrane nephropathy (TBMN) caused by germline COL4A3 or COL4A4 gene mutations. Less frequent but important cause with respect to morbidity is Alport syndrome caused by germline COL4A5 gene mutations. The features of Alport syndrome include hematuria, proteinuria and all males with X-linked disease and all individuals with recessive disease will develop end stage renal disease, usually at early youth. In X-linked Alport syndrome, a clear genotype-phenotype correlation is typically observed in men. Deleterious COL4A5 mutations are associated with a more severe renal phenotype and more frequent high-frequency sensorineural hearing loss and ocular abnormalities. Less severe COL4A5 mutations result in a milder phenotype, with less frequent and later onset extrarenal anomalies. The phenotype in females is highly variable, mostly due to inactivation of one of the X chromosomes. Isolated cases may be caused by de novo COL4A5 mutations or by gonosomal mosaicism. Untreated autosomal recessive Alport syndrome, caused by COL4A3 and COL4A4 mutations, is typically associated with ESRD at the age of 23–25 years and extrarenal symptoms in both men and women. The TBMN phenotype is associated with heterozygous carriers of COL4A3, COL4A4 mutations. Molecular genetic testing is the gold standard for diagnosing these diseases. Although genotype-phenotype correlations exist, the phenotype is influenced by modifying factors, which remain mainly undefined. No therapy is available that targets the cause of Alport syndrome; angiotensin-converting enzyme inhibitor therapy delays renal failure and improves lifespan.

© 2017 The Lithuanian University of Health Sciences. Production and hosting by Elsevier Sp. z o.o. This is an open access article under the CC BY-NC-ND license (<http://creativecommons.org/licenses/by-nc-nd/4.0/>).

1. Introduction

Hematuria is one of the most frequently observed symptoms in nephrology and urology. Microscopic hematuria may be detected along with mild transitory proteinuria on examina-

tion of patients with febrile conditions and clinical manifestations related to the urinary system. Microscopic hematuria might also be found randomly, during routine urine examinations in asymptomatic persons or during preventive procedures. The presence of a macroscopic attack may be alarming from the patient's point of view. Nevertheless, microscopic or

* Corresponding author at: Department of Medical Genetics, University Hospital Ostrava, 17. listopadu 1790, 708 52 Ostrava, Czechia.
E-mail address: pavlina.plevova@volny.cz (P. Plevová).

<http://dx.doi.org/10.1016/j.medici.2017.01.002>

1010-660X/© 2017 The Lithuanian University of Health Sciences. Production and hosting by Elsevier Sp. z o.o. This is an open access article under the CC BY-NC-ND license (<http://creativecommons.org/licenses/by-nc-nd/4.0/>).

macroscopic hematuria in pediatric patients is not typically a symptom of a serious disease. A significant problem for pediatricians and nephrologists is to distinguish the small proportion of prognostically serious conditions, which may be influenced significantly by treatment, from the large group of transitory or long-term benign hematurias in children [1,2].

Thirty years ago, Fairley and Birch discovered phase-contrast microscopy. This non-invasive approach of urine examination enabled distinguishing between glomerular and non-glomerular types of erythrocyturia [3].

A special issue is the concomitant occurrence of hematuria in the patient's closest relatives (siblings, parents, and grandparents). In most cases, these individuals are asymptomatic. The vast majority of these individuals have glomerular hematuria, which is the topic of this article [1,2].

2. History

Alport syndrome (AS) was named after Cecil A. Alport, who published his observations in the British Medical Journal in 1927 [4]. Although similar observations were published earlier by other authors, C. A. Alport noted two important facts: first, "The male members of a family tend to develop nephritis and deafness and do not as a rule survive," and second, "The females have deafness and haematuria and live to old age."

Almost nothing was known about the etiopathogenesis of nephropathy before routine kidney biopsies were introduced into clinical practice that directed the attention to the glomerulus. However, only when electron microscopy (EM) came into routine use during the 1970s, was it possible to recognize unusual changes in the glomerular basement membrane (GBM). EM enabled visualization of the early stages of nephropathy, before the glomeruli became affected by terminal sclerotization [5,6].

In the 1960s, frequent urine screening of the population revealed asymptomatic individuals with isolated microscopic hematuria and normal kidney morphology, kidney functions, and blood pressure. In 1966, McConville and McAdams described a group of children with microscopic hematuria that had other family members with hematuria, but without nephropathy. They were the first to use the term *benign familial hematuria* [7]. After the 1970s, based on images observed with EM, a new term – *thin membrane syndrome* – was introduced. Currently, the most commonly used term is *thin basement membrane nephropathy* (TBMN) [8].

3. Glomerular basement membrane

The GBM is a specialized form of extracellular matrix, with a thickness of 300–350 nm. The GBM lies between endothelial cells and the podocyte epithelial layer of the glomerular capillary wall. The GBM forms a basic mechanical support that anchors cellular elements, and its components serve as ligands for membrane receptors and transporters. The complex interconnectivity between the GBM and other layers facilitates its function in blood ultrafiltration into the primary ultrafiltrate. Thus, the term 'glomerular barrier complex' includes the GBM, the endothelial cell layer with fenestrations,

podocyte foot processes, the slit membrane, and the polysaccharide endothelial surface layer [9–11].

Imaging the GBM with EM enabled the differentiation of three layers. This structure has been presented in textbooks for several decades. The layers include the central dark *lamina densa*, and its sandwich-like lining on both sides, the *lamina rara interna* and *externa* [12]. Furthermore, the GBM structure comprises a scaffold of intertwining collagen IV fibers, which are bound with molecules of laminin, nidogen/entactin, perlecan, and heparin sulphate proteoglycan [12,13].

Collagen IV comprises six α chains ($\alpha 1-6$) that are produced by podocytes. These chains include the collagen domain, characterized by the repeating amino acid triplet, glycine-X-Y (where X and Y are various amino acids), and two non-collagen domains, 7S and NC1 (Fig. 1). The 7S domains connect the α chain trimers into the collagen network. Arrangement of the three α chains into the triple helix starts at the NC1 domain (Fig. 1) [14]. The encircling chains fit tightly together, due to the small glycine residues in the collagen domain. They form the so-called glycine backbone of the collagen. There are evolutionary conserved interruptions of the collagenous motif of Gly-X-Y. Only three trimer combinations are found in tissues: $\alpha 1-1-1$, $\alpha 3-4-5$, and $\alpha 5-5-6$. Two collagen IV triple-helical protomers interact through their C-terminal NC1 domains, and four protomers interact through their N-terminal 7S domains, to form the GBM collagen network (Fig. 1). The $\alpha 3-4-5$ trimer is found in the GBM and in tubular structures of the nephron, but also in the lungs, testis, eye, and cochlea. The Bowman capsule and skin basement membranes maintain $\alpha 5-5-6$ trimers [13,15,16]. In the glomerulus, the initial embryonal $\alpha 1-1-1$ network is subsequently replaced by the $\alpha 3-4-5$ configuration, during nephron maturation (the so-called developmental switch). This switch provides more resistance to physical and chemical effects [17].

4. Alport syndrome

4.1. Genetic background of Alport syndrome/thin basement membrane nephropathy

The six genes that encode the α -chains of collagen IV (COL4A1-COL4A6) are located in pairs, facing head-to-head, in close proximity (Table). This positioning reflects the mode of disease inheritance and the gender-related disease severity in COL4A5 gene mutations. Most patients (85%) have X-linked Alport syndrome (XLAS) with a deficient $\alpha 5$ chain due to COL4A5 gene mutations. This condition is characterized by a more severe phenotype in males than in female carriers. Patients with the less frequent (14% of cases) autosomal recessive form of Alport syndrome (ARAS) are either homozygous for identical mutations in COL4A3 or COL4A4 genes, or they carry two different mutations in the same gene (compound heterozygosity) [18–20]. Some authors also recognize an autosomal dominant form of Alport syndrome (ADAS; 1% of cases) caused by heterozygous COL4A3 or COL4A4 mutations and Alport-like ultrastructural histology [18–21]. Individuals with TBMN that exhibit isolated hematuria are usually carriers of a heterozygous mutation in the COL4A3 or COL4A4 gene. This condition is currently considered a trait of an ARAS carrier [22]. The

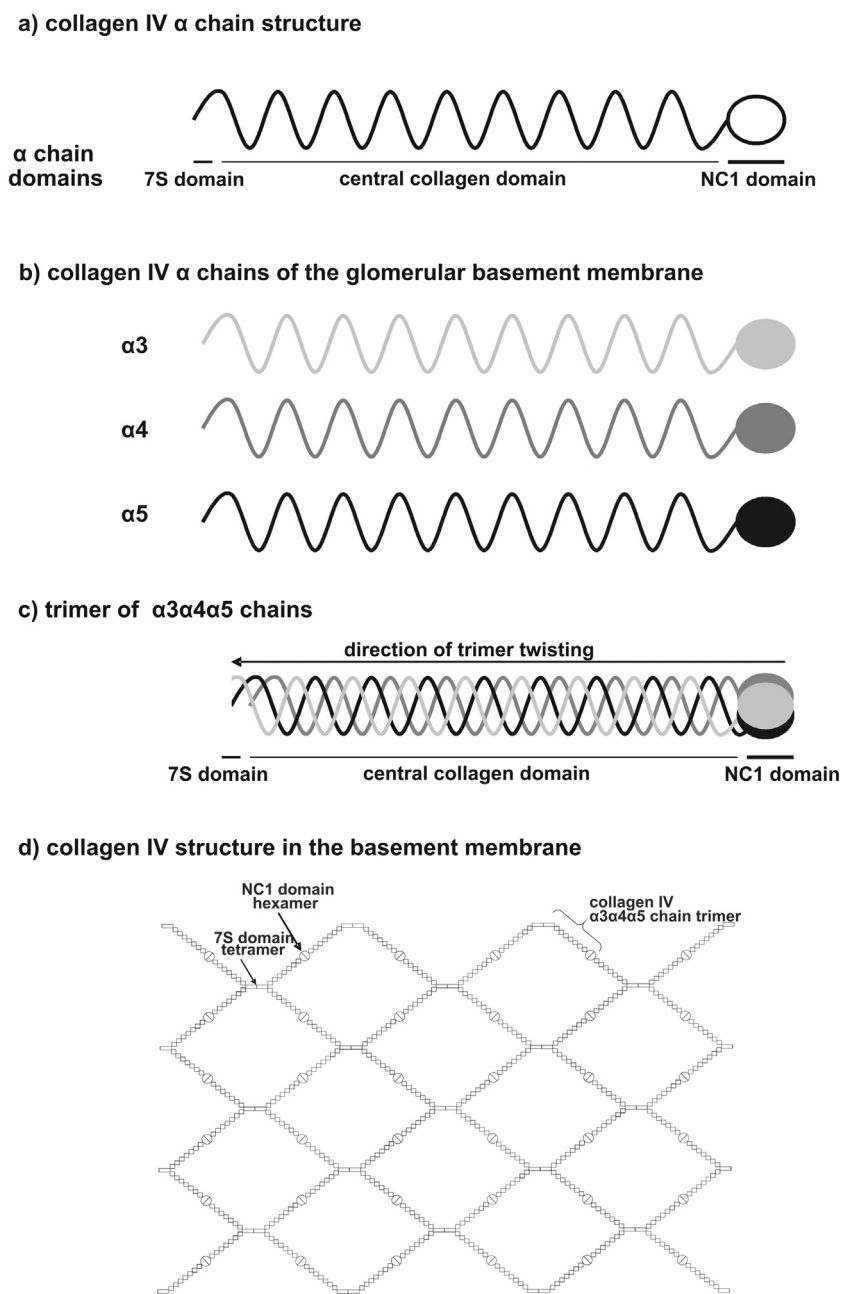


Fig. 1 – Schematic of the structure of collagen IV α chains associated with Alport syndrome (a, b), how they twist to form a trimer (c) and of collagen IV structure in the basement membrane (d) (according to Sundaramoorthy et al. [14] and Sado et al. [15]).

Table – Characteristics of the genes encoding α -chains of collagen IV [15,18, OMIM database].

Gene	Chromosome locus	α -chain of collagen IV encoded by the gene	Disease caused by mutation of the gene
COL4A1	13q34	$\alpha1$	Hereditary angiopathy with nephropathy, aneurysms, and muscle cramps; porencephaly
COL4A2	13q34	$\alpha2$	Porencephaly
COL4A3	2q36.3	$\alpha3$	ARAS, ADAS? TBMN
COL4A4	2q36.3	$\alpha4$	ARAS, ADAS? TBMN
COL4A5	Xq22.3	$\alpha5$	XLAS
COL4A6	Xq22.3	$\alpha6$? X-linked deafness

ARAS, autosomal recessive Alport syndrome; ADAS, autosomal dominant Alport syndrome; TBMN, thin basement membrane nephropathy; XLAS, X-linked Alport syndrome.

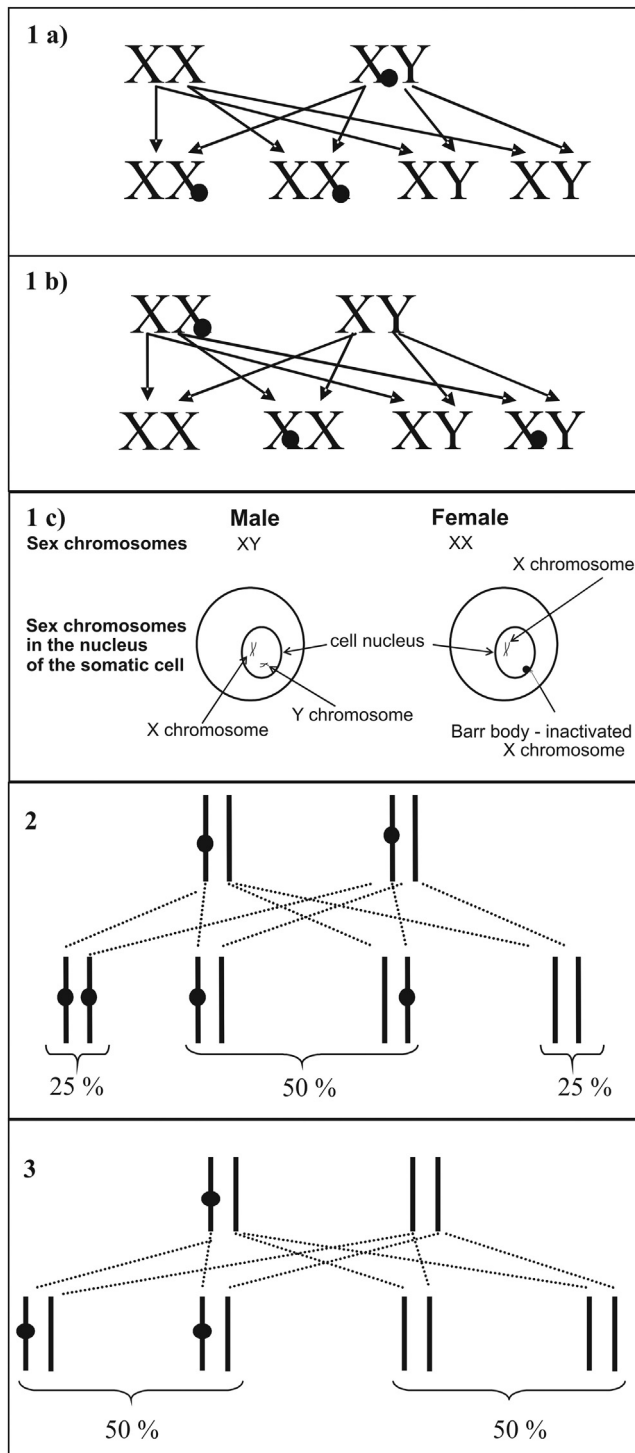


Fig. 2 – Alport syndrome and thin basement membrane nephropathy – patterns of inheritance. (1) X-linked recessive inheritance; (1a) the trait is carried by males: the hemizygous male transfers his X chromosome with the mutated COL4A5 gene to all his daughters, and all his sons are healthy; (1b) the trait is carried by females: the female transfers her X chromosome with the mutated COL4A5 gene to half of her daughters (they have one gene wildtype and one mutated, their phenotype is variable) and half of her sons (they have only the mutated gene, the disease manifests); (1c) schematic of X chromosome inactivation: in

inheritance principles for the three forms of the disease are shown in Fig. 2.

Hundreds of sequence variants have been described in COL4A5, COL4A3, and COL4A4 genes. These variants are recorded in databases of mutations [23].

In the developed countries, routine testing of the three genes is performed. Approximately 34% of COL4A5 pathogenic mutations are premature stop codons (6% direct and 28% downstream). Missense mutations occur in 43% of patients, and the majority (75%) affect glycine codons; 23% are splicing variants [24]. Although unique pathogenic COL4A5 mutations are found in most families with XLAS worldwide, in Slavic countries, such as Greece, the Czech Republic, and Slovenia, the c.1871G > A (G624D) COL4A5 mutation is prevalent. This mutation is typically associated with a milder course of the disease [25, Plevova, unpublished results].

The most deleterious mutations, such as large genomic rearrangements, nonsense mutations, and frameshift mutations, prevent protein synthesis. When any one of the α chains in the triple helix is missing, the trimer is not created. Consequently, embryonal collagen ($\alpha 1$ - $\alpha 1$ - $\alpha 2$ trimers) cannot be exchanged for adult collagen ($\alpha 3$ - $\alpha 4$ - $\alpha 5$ chains). The result is a persistent, insufficiently resistant embryonal collagen in the GBM [17].

Missense mutations that result in glycine substitutions slow the process of trimer twisting. The arrangement of chains into the triple helix starts at the NC1 domain. Thus, NC1 domain mutations can disrupt the processes of chain twisting and hexamer folding, which are necessary for network formation [14].

Based on the above-listed facts, it is possible to perform diagnostic tests on kidney and skin biopsy samples with fluorescent antibodies against the $\alpha 3$, $\alpha 4$, and $\alpha 5$ chains. In most XLAS cases, immunofluorescence studies show absent GBM expression of all constitutive collagen IV chains ($\alpha 3$, $\alpha 4$, and $\alpha 5$) in both the GBM and Bowman's capsule in kidney biopsies, and negative $\alpha 5$ staining in skin biopsies [26–28]. In a minority of patients, however, partial or normal expression can be observed, whereas female carriers often demonstrate a segmental pattern of expression by immunofluorescence studies [26,27,29]. Similarly to XLAS, patients with ARAS

males, two sex chromosomes are present in an active form in the nuclei of somatic cells, one X chromosome and one Y chromosome; in females, one X chromosome is present in the active form, and the other is inactivated in the form of a Barr body. (2) Autosomal recessive inheritance: the disorder manifests when both alleles of the gene are mutated; the parents are heterozygous carriers of the mutation (they carry the mutation on one allele of the gene); the offspring of these parents have a 25% probability of the mutation in both alleles (i.e., they manifest the disease), a 50% probability of being heterozygous carriers of the trait, and a 25% probability of having two normal alleles. (3) Autosomal dominant inheritance: mutation in one allele of the gene can cause the disease; offspring of a parent with the mutation have a 50% probability of inheriting the trait, regardless of gender.

generally have no detectable $\alpha 3$, $\alpha 4$, and $\alpha 5$ collagen IV chains in their GBM, whereas positive immunoreactivity for $\alpha 5$ chain is observed in other basement membranes, including the renal capsule, the renal tubular structures, and the epidermal basement membrane [30]. The clinical importance of immunofluorescent analyses has recently decreased, as genetic testing is generally replacing more invasive investigations such as kidney biopsy and skin biopsy and is likely to achieve confirmation of the diagnosis at a molecular level in around 95% of patients who have AS [23,31].

With AS, the GBM structure has reduced resistance to physical and chemical influences. Initially, the process is reflected in well-known EM changes: an initial GBM thinning in early childhood progresses to GBM splitting [32]. These structural changes induce an inflammatory response in the mesangium and epithelial cell layers of the proximal tubule, and GBM fibrotization develops. These processes lead to the thickening, lamelization, and fragmentation of the GBM, observed with EM, in the later phases of AS. In the thickened regions of the GBM, podocyte foot processes are lost [6,33].

In the nephrological literature, the term collagen IV nephropathy or type IV collagen – associated diseases includes AS, TBMN, Goodpasture syndrome, and posttransplantation anti-GBM nephritis in patients with AS [16].

4.2. Clinical picture of Alport syndrome

Alport syndrome (AS) is a progressive nephropathy characterized by the association of progressive hematuric nephritis with ultrastructural changes of the glomerular basement membrane (GBM), sensorineural deafness and variable ocular abnormalities [34,35].

The initial, symptom-free microscopic hematuria, sometimes with macroscopic attacks, may be accompanied by proteinuria, hypertension, or chronic renal failure, which usually leads to end-stage renal disease (ESRD). These symptoms may occur at any time between the first and seventh decade of life [22]. The most severe course of XLAS is associated with the hemizygous condition in males (Fig. 2). The mean course to ESRD is 25 years in untreated males with XLAS, and 90% require renal replacement therapy before age 40 years. While patients with AS represent about 2% of the registered cases of pediatric patients with ESRD in North America [24,36], the rate in Europe is below 1% [6,37]. The proportion of patients of Romanian origin was found to be significantly larger than expected based on the proportion of Romanian people in the total population of Alport syndrome in Slovakia [38]. They are a traditionally nomadic ethnic group, living mostly in Europe and the Americas and originating from the northern regions of the Indian subcontinent [39]. A founder effect may be responsible for this observation [38].

In most cases of XLAS, a genotype-phenotype correlation can be observed. The most deleterious mutations lead to earlier ESRD onset, compared to less severe mutations (e.g., those in the glycine scaffold). The so-called “juvenile” or “early onset” type of XLAS is associated with kidney failure that develops before age 30 years in patients; these patients have a high risk of extrarenal symptom development, and they typically carry deleterious mutations in the COL4A5 gene. In contrast, the “adult” or “late onset” form of XLAS results in

ESRD after the age of 30 years, or not at all, and it is typically associated with less severe mutations, e.g., G624D and P628L missense mutations have been observed with this phenotype [16,20,23]. Even though one can often predict the clinical course of the disease, we currently cannot conclude with absolute certainty how each specific mutation will affect the prognosis of the patient [18,22]. Nowadays, the renal phenotype may be influenced by treatment as angiotensin-converting enzyme inhibitor therapy delays renal failure and improves lifespan [34,35].

Hearing is normal at birth followed by the development of high-frequency (2000–8000 Hz) sensorineural hearing loss in 50% of affected males with XLAS by the age of 15 years and 90% by the age of 40 years [28]. Early hearing loss is typically associated with severe renal damage. Nearly all patients with the recessive form of the disease develop early hearing loss, regardless of gender, and it is usually progressive [18,21]. Children in whom the diagnosis of AS has been made should have audiological assessments from 5 years [40].

Ocular abnormalities occur in 44%–72% of adult males and 15%–38% of adult females with XLAS, develop in late childhood or early adult life, and can be visualized using a slit lamp ophthalmoscope [40,41]. Their prevalence depends on how carefully the person is examined, and on the method used e.g., with retinal photography or with optical coherence tomography [42]. The abnormalities include anterior lenticonus and central and peripheral retinopathy with typical whitish or yellow spots, retinal thinning and macular holes; vitelliform lesions and midperipheral retinoschisis have also been described [18,41,42]. Anterior lenticonus causes capsule thinning, which results in bulging of the lens; this condition is pathognomonic for AS. It occurs in 30% of males with XLAS in the fourth decade of life, and it occurs almost exclusively in families with juvenile AS [18,41,42]. All patients with this symptom also develop chronic nephritis, sensorineural hearing loss, and retinopathy. Retinopathies with whitish or yellow perimacular spots or flecks appear in early adolescence, and they most commonly occur together with renal failure, hearing loss, and lenticonus. However, these retinopathies do not affect vision or require therapy [40,41].

Historical clinical criteria of AS include (1) family history of macro/microscopic hematuria or chronic renal failure, (2) abnormalities characteristic of Alport syndrome detected by electron microscopic analyses of kidney biopsy specimens, (3) characteristic ocular abnormalities (anterior lenticonus and macular flecks), (4) high-frequency sensorineural deafness. At least three of the criteria should be met to establish the diagnosis of Alport syndrome [43].

Between 10% and 15% of patients carry a de novo mutation, or one of the parents is affected with gonadal mosaicism, where only some gametes, i.e., sperms or oocytes, carry the COL4A5 mutation but the rest of the cells is normal and the mutation is undetectable in blood. In these patients, nephropathy is absent from the family history [40]. The male-to-male inheritance of nephropathy excludes the XLAS form.

Female carriers of XLAS present a highly variable clinical picture, ranging from an entirely asymptomatic disease course, even with the most severe mutations, to lifelong microscopic hematuria, without any deterioration of renal functions and renal failure; and to renal failure at a young age.

This variability in the clinical picture of XLAS among women is caused mainly by X chromosome lyonization, where one of the X chromosomes becomes inactive in each cell of the body through complex cellular processes in the early stages of embryonic development (Fig. 2c) [18,44]. When this unbalanced X chromosome inactivation results in an active mutated gene in the kidneys, nephropathy may develop. This phenomenon can cause large phenotypic variability among females with identical mutations in one family [44].

XLAS with leiomyomatosis of the esophagus and tracheo-bronchial tree is a relatively rare condition. This disease is caused by a large deletion in the 5' end (i.e., the initiation region) of the COL4A5 gene, which includes the adjacent COL4A6 gene [45]. Symptoms of this form of the disease manifest in late childhood, and they include dysphagia, postprandial vomiting, retrosternal pain or pain in the epigastrium, recurrent bronchitis, dyspnea, cough, and stridor. Women in these families may also develop genital leiomyomas. Also, bilateral posterior subcapsular cataracts are frequently present [45].

The clinical features of patients with ARAS are the same as those for males with XLAS. However, with ARAS, there is no sexual differentiation in the disease course or family history [46]. Autosomal recessive mutations typically causes sporadic AS cases that appear only in one generation. Males and females are at equal risk, and the disease severity is similar. A young woman with ERDS, hearing loss, and eye abnormalities suggests ARAS [20].

The possible real existence of an autosomal dominant form has long been debated. It is currently well established that a variable but significant percentage of TBMN patients carrying heterozygous COL4A3/A4 mutations develop later added proteinuria and chronic renal failure (discussed below) [2,22]. The AS phenotype is influenced by many modifying factors, both genetic and environmental, that remain mainly unidentified [47]. Molecular genetic testing is most helpful in confirming the diagnosis, determining the mode of inheritance, and sometimes, in predicting the prognosis of the disease. Family members should be offered predictive genetic testing to disclose the risk of disease development. The results may be used to select suitable kidney donors among relatives or for family planning [48].

5. Thin basement membrane nephropathy

TBMN is the most frequent cause of microscopic hematuria in the population; its incidence is approximately 1% [49]. TBMN is usually considered benign; it is mostly detected in random or scheduled urine sediment analyses in healthy individuals with normal kidney ultrasound, kidney functions, and normal blood pressure. TBMN inheritance is mostly autosomal dominant; however, rare sporadic cases have been described, where a de novo mutation may be assumed. Heterozygous COL4A3 or COL4A4 gene mutations explain more than 50% of familial benign hematuria cases [49]. The penetrance is incomplete; however, microscopic hematuria is not detected only in less than 10% of carriers [50]. In TBMN, kidney biopsy samples exhibit no abnormalities with light microscopy, and only GBM thinning is found with EM. The reference thickness

of a normal GBM varies among laboratories and is also age-dependent; however, a thickness less than 150 nm is considered thinned [6,51]. Typically, with EM analysis, global GBM thinning is detected over the whole sample, or in at least 50% of glomeruli. Nevertheless, some patients show segmental GBM thinning. In pre-school and elementary school-aged children, in particular, it must be taken into account that initially AS may manifest as a thin membrane. Immunofluorescence analyses in TBMN typically show normal staining of $\alpha 3$, $\alpha 4$, and $\alpha 5$ chains. Histological changes typical for AS are detectable in only a minority of adults, and they indicate a risk of developing ESRD at an older age. Pregnancy does not pose any risk for women with TBMN [6,25,46].

Recent studies have shown that some TBMN patients develop proteinuria and changes of focal segmental glomerulosclerosis when biopsied. In several studies, up to 20%–30% of heterozygous carriers progressed to ESRD by the age of 70 years [21,50–55]. The proportion of patients with extrarenal manifestations differs from none [50,51] to up to 13%–48% with hearing loss and 14% with ocular abnormalities [21,52], however, the rates may be higher. These results suggest that in most families with heterozygous COL4A3/COL4A4 mutations and microscopic hematuria due to TBMN, some patients will progress to a more severe clinical outcome with age-dependent penetrance. No genotype–phenotype correlation was observed. Genetic counseling should be conducted taking this aspect into account [21,52–54].

Certain hypomorphic podocin variants (p.Arg229Gln and p.Glu237Gln) may act as adverse genetic modifiers when co-inherited with COL4A3 or COL4A4 mutations, thus predisposing to focal segmental glomerulosclerosis and severe kidney function decline in COL4A3 and COL4A4 heterozygotes [56,57].

Heterozygous COL4A3 and COL4A4 mutations explain only about 40% of familial microscopic hematuria cases, while it is more than certain that additional still unknown genes exist that are responsible for a similar phenotype [21,53].

6. Other syndromes that exhibit familial glomerular hematuria

Currently other genetic forms of glomerular hematuria were recognized [58].

Immunoglobulin A (IgA) nephropathy, the most common chronic glomerulopathy worldwide is a complex, multifactorial disease, characterized by ill-defined genetic factors that influence disease pathogenesis. The only symptom that might be observed over time is isolated microscopic hematuria. Attacks of macroscopic hematuria that last one or more days may appear in association with respiratory infections. A familial occurrence has been repeatedly described. A definite diagnosis requires histological examination of a kidney biopsy [59].

C3 glomerulopathy is a subgroup of membranoproliferative glomerulonephritis. It is characterized by immunofluorescence detection of complement 3 (C3) deposits without immunoglobulins, low serum C3 levels, but typically, normal C4 levels. It includes three clinical conditions, known as dense deposit disease, C3 glomerulonephritis, and complement factor H-related 5 (CFHR5) nephropathy [20,60,61]. Mutations

have been described in genes that encode proteins that regulate the alternative complement pathway, including *CFH*, *CFI*, *C3*, and *CFHR5* genes [62]. Prevalent duplication of exons 2–3 of the *CFHR5* gene was observed in Cypriot families [63]. Patients may present with proteinuria, hematuria, hypertension, and/or renal failure. Chronic deterioration of renal function leads to ESRD, typically within 10 years of the diagnosis, in 36%–50% of patients [62,63]. Development of proteinuria is a bad prognostic sign [63]. Outcomes of renal transplantation are characterized by histological recurrence, which may contribute to increased rates of allograft failure [62].

Glomerulopathy with fibronectin deposits is caused by *FN1* (fibronectin) gene mutations and inherited as an autosomal-dominant trait. It is characterized by microscopic hematuria, proteinuria, and hypertension, with progression to ESRD, during the second to sixth decade of life [22,58].

MYH9-related disorders is caused by mutations in the *MYH9* gene, which encodes non-muscle myosin heavy chain IIA. This autosomal dominant disease involves Döhle's inclusions in leucocytes, macrothrombocytopenia, congenital nephropathy, sensory hearing loss, and congenital cataract. Nephropathy begins with microscopic hematuria, which gradually develops into proteinuria. Depending on the location of the mutation, this disease can carry a risk of ESRD in young adulthood. Previously, the syndrome was divided into four clinical entities, including the May Hegglin anomaly and the Sebastian, Fechtner, and Epstein syndromes. About 35% of cases are sporadic, half of them due to de novo *MYH9* gene mutations [64].

7. Therapy for Alport syndrome and thin basement membrane nephropathy

There is no radical cure for the disease [65]. Guidelines for AS and TBMN therapy are derived mainly from general nephrology guidelines, which were generated for managing diabetic nephropathies. This approach was based on the knowledge that reducing even a minor amount of proteinuria is very effective in reducing the risk of ESRD development. Gross et al. have shown that long-term administration of angiotensin converting enzyme inhibitors (ACEis) to AS patients with proteinuria delayed dialysis by 18 years and in patients with hematuria or microalbuminuria the treatment was even more effective [34]. Also other pharmacological intervention at the renin-angiotensin-aldosterone system has been used with success including angiotensin receptor blockers (ARBs), renin inhibitors and aldosterone blockade [35,65]. The results of studies with the combination of ACEis and ARBs are inconclusive [65]. Current guidelines include the administration of ACEis or angiotensin receptor blockers for patients at risk, either prior to proteinuria or upon detection of mild proteinuria (microalbuminuria) as they are the most effective agents at prolonging renal survival [65–67]. The renin-angiotensin-aldosterone system inhibitors are currently the only pharmaceutical agents available to retard chronic kidney disease progression in AS. Novel pharmacological and biological therapies including stem cell have been met with ambiguous success [65].

There is a need for at least biannual monitoring of blood pressure and screening for proteinuria for all mutation carriers [34]. It seems that long-term administration of ACEi may also be beneficial for ESRD prevention in female carriers with mild proteinuria, particularly when the patient has a childhood history of repeated macroscopic attacks. Low compliance with therapy may be expected among individuals with asymptomatic AS, typically during puberty and adolescence, and particularly, among members of families with no ESRD history [46,68,69].

Female carriers of the *XLAS* gene mutation are often considered potential kidney donors for a son or a brother. Symptomatic carriers should be discouraged from kidney donation, due to reduced “viability” of the donated kidney and the potential risk of ESRD. Compared to unrelated donors, female carriers have a higher risk of hypertension and microalbuminuria/proteinuria; in addition, they are at risk of renal failure [70]. A kidney biopsy is mandatory in a potential donor that carries a mutation, even when they have normal renal function and normal levels of proteinuria. It is necessary to assess potential renal damage that may result from the effects of random X inactivation [71]. Individuals from families with ARAS should undergo genetic and biopsy examinations. Heterozygous mutation carriers with normal blood pressure and kidney functions may be recommended as kidney donors, when a biopsy can exclude a coincidental nephropathy [46,72]. In 3%–5% of men with kidney transplantations, an early, rapid loss of the graft may occur due to the development of anti-GBM nephritis. This condition occurs when the immune system is exposed to a new GBM that harbors α chains 3, 4, and 5. This complication is commonly observed in patients with major genomic deletions; however, it may also occur in individuals with other mutations [72].

Guidelines recommend that patients should be protected from ototoxic medication and excessive acoustic loads. Lenticonus may be corrected with a lens replacement. Retinopathy is typically progressive; however, it is not detrimental to sight, and no treatment is required [68].

Individuals with TBMN may be reviewed by the primary care provider annually for hypertension, proteinuria, and renal impairment. There are no significant limitations on physical activities. The appearance of proteinuria or elevated blood pressure requires an ACEi treatment [46,65].

Families with AS may be offered prenatal and preimplantation diagnoses of the disease. Ideally, young couples should seek genetic counseling prior to pregnancy [46].

8. Concluding remarks

Significant progress has recently been achieved in recognizing the etiopathogenesis of AS and TBMN. The wide-spread availability of genetic testing has facilitated achieving accurate diagnoses and predictions of the presumable disease course, in most cases. Genetic testing has also allowed the identification and early surveillance of other family members at risk. Although we cannot effectively treat the cause in patients with AS, we can effectively reduce the rate of ESRD with early symptomatic therapy in patients that show even minor proteinuria. The relatively high variability of the clinical

picture among different families with identical mutations, and even within one family, indicates that strong genetic modifying factors exist, and they remain to be identified. With respect to the relatively high incidence of TBMN in the population family members of all patients with unclear microscopic hematuria and normal renal functions should be offered urine testing before invasive, usually urological examinations are performed.

Conflict of interest

The authors state no conflict of interest.

Acknowledgments

The work was supported by the Ministry of Health of the Czech Republic – Conceptual Development of Research Organization, Faculty Hospital of Ostrava (2015).

REFERENCES

- [1] Kashtan CE. Familial hematuria. *Pediatr Nephrol* 2009;24(10):1951–8.
- [2] Gale DP. How benign is hematuria? Using genetics to predict prognosis. *Pediatr Nephrol* 2013;28(8):1183–94.
- [3] Birch DF, Fairley KF. Haematuria: glomerular or non-glomerular? *Lancet* 1979;2(8147):845–6.
- [4] Alport AC. Hereditary familial congenital haemorrhagic nephritis. *BMJ* 1927;1(3454):504–6.
- [5] Cameron JS, Hicks J. The introduction of renal biopsy into nephrology from 1901 to 1961: a paradigm of the forming of nephrology by technology. *Am J Nephrol* 1997;17(3–4):347–58.
- [6] Janda J, Dušek J, Vondrák K, Stejskal J, Krejčová S. Alport syndrome and benign familial hematuria. *Cs Pediatr* 1999;54(10):602–9.
- [7] McConville JM, McAdams AJ. Familial and nonfamilial benign hematuria. *J Pediatr* 1966;69(2):207–14.
- [8] Gauthier B, Trachtman H, Frank R, Valderrama E. Familial thin basement membrane nephropathy in children with asymptomatic microhematuria. *Nephron* 1989;51(4):502–8.
- [9] Büscher AK, Weber S. The podocytopathies. *Eur J Pediatr* 2012;171(8):1151–60.
- [10] Haraldsson B, Nystrom J, Deen WN. Properties of the glomerular barrier and mechanisms of proteinuria. *Physiol Rev* 2008;88(2):451–87.
- [11] Menzel S, Moeller MJ. Role of the podocyte in proteinuria. *Pediatr Nephrol* 2011;26(10):1775–80.
- [12] McCarthy KJ, Wassenhove-McCarthy DJ. The glomerular basement membrane as a model system to study the bioactivity of heparan sulfate glycosaminoglycans. *Microsc Microanal* 2012;18(1):3–21.
- [13] Miner JH, Sanes JR. Collagen IV alpha 3, alpha 4, and alpha 5 chains in rodent basal laminae: sequence, distribution, association with laminins, and developmental switches. *J Cell Biol* 1994;127(3):879–91.
- [14] Sundaramoorthy M, Meiyappan M, Todd P, Hudson BG. Crystal structure of NC1 domains. Structural basis for type IV collagen assembly in basement membranes. *J Biol Chem* 2002;277(34):31142–53.
- [15] Sado Y, Kagawa M, Naito I, Ueki Y, Seki T, Momota R, et al. Organization and expression of basement membrane collagen IV genes and their roles in human disorders. *J Biochem* 1998;123(5):767–76.
- [16] Hudson BG. The molecular basis of goodpasture and Alport syndromes: beacons for the discovery of the collagen IV family. *J Am Soc Nephrol* 2004;15(10):2514–27.
- [17] Kalluri R, Shield CF, Todd P, Hudson BG, Nelson EG. Isoform switching of type IV collagen is developmentally arrested in X-linked Alport syndrome leading to increased susceptibility of renal basement membranes to endoproteolysis. *J Clin Invest* 1997;99(10):2470–8.
- [18] Jais JP, Knebelmann B, Giatras I, De Marci M, Rizzoni G, Renieri A, et al. X-linked Alport syndrome: natural history in 195 families and genotype-phenotype correlations in males. *J Am Soc Nephrol* 2000;11(4):649–57.
- [19] Heidet L, Gubler MC. The renal lesions of Alport syndrome. *J Am Soc Nephrol* 2009;20(6):1210–5.
- [20] Wang Y, Sivakumar V, Mohammed M, Colville D, Storey H, Flinter F, et al. Clinical and genetic features in autosomal recessive and X linked Alport syndrome. *Pediatr Nephrol* 2014;29(3):391–6.
- [21] Fallerini C, Dosa L, Tita R, Del Prete D, Feriozzi S, Gai G, et al. Unbiased next generation sequencing analysis confirms the existence of autosomal dominant Alport syndrome in a relevant fraction of cases. *Clin Genet* 2014;86(3):252–7.
- [22] Deltas C, Pierides A, Voskarides K. Molecular genetics of familial hematuric diseases. *Nephrol Dial Transplant* 2013;28(12):2946–60.
- [23] International Alport Mutation Consortium, Savige J, Ars E, Cotton RG, Crockett D, Dagher H, et al. DNA variant databases improve test accuracy and phenotype prediction in Alport syndrome. *Pediatr Nephrol* 2014;29(6):971–7.
- [24] Savige J, Storey H, Il Cheong H, Kang HG, Park E, Hilbert P, et al. X-linked and autosomal recessive Alport syndrome: pathogenic variant features and further genotype-phenotype correlations. *PLOS ONE* 2016;11(9):e0161802.
- [25] Pierides A, Voskarides K, Kkolou M, Hadjigavriel M, Deltas C. X-linked, COL4A5 hypomorphic Alport mutations such as G624D and P628L may only exhibit thin basement membrane nephropathy with microhematuria and late onset kidney failure. *Hippokratia* 2013;17(3):207–13.
- [26] Nakanishi K, Yoshikawa N, Iijima K, Kitagawa K, Nakamura H, Ito H, et al. Immunohistochemical study of alpha 1–5 chains of type IV collagen in hereditary nephritis. *Kidney Int* 1994;46(5):1413–21.
- [27] Haas M. Alport syndrome and thin glomerular basement membrane nephropathy: a practical approach to diagnosis. *Arch Pathol Lab Med* 2009;133(2):224–32.
- [28] Hashimura Y, Nozu K, Kaito H, Nakanishi K, Fu XJ, Ohtsubo H, et al. Milder clinical aspects of X-linked Alport syndrome in men positive for the collagen IV $\alpha 5$ chain. *Kidney Int* 2014;85(5):1208–13.
- [29] Massella L, Gangemi C, Giannakakis K, Crisafi A, Faraggiana T, Fallerini C, et al. Prognostic value of glomerular collagen IV immunofluorescence studies in male patients with X-linked Alport syndrome. *Clin J Am Soc Nephrol* 2013;8(5):749–55.
- [30] Gubler MC, Knebelmann B, Beziau A, Broyer M, Pirson Y, Haddoum F, et al. Autosomal recessive Alport syndrome: immunohistochemical study of type IV collagen chain distribution. *Kidney Int* 1995;47(4):1142–7.
- [31] Gross O, Kashtan CE, Rheault MN, Flinter F, Savige J, Miner JH, et al. Advances and unmet needs in genetic, basic and clinical science in Alport syndrome: report from the 2015 International Workshop on Alport Syndrome. *Nephrol Dial Transplant* 2016;(May). pii:gfw095.
- [32] Kruegel J, Rubel D, Gross O. Alport syndrome – insights from basic and clinical research. *Nat Rev Nephrol* 2013;9(3):170–8.

- [33] Cosgrove D. Glomerular pathology in Alport syndrome: a molecular perspective. *Pediatr Nephrol* 2012;27(6):885–90.
- [34] Gross O, Licht C, Anders HJ, Hoppe B, Beck B, Tönshoff B, et al. Early angiotensin converting enzyme inhibition in Alport syndrome delays renal failure and improves life expectancy. *Kidney Int* 2012;81(5):494–501.
- [35] Temme J, Peters F, Lange K, Pirson Y, Heidet L, Torra R, et al. Incidence of renal failure and nephroprotection by RAAS-inhibition in heterozygous carriers of X-chromosomal and autosomal-recessive Alport-mutations. *Kidney Int* 2012;81(8):779–83.
- [36] Smith JM, Martz K, Blydt-Hansen TD. Pediatric kidney transplant practice patterns and outcome benchmarks, 1987–2010: a report of the North American Pediatric Renal Trials and Collaborative Studies. *Pediatr Transplant* 2013;17(2):149–57.
- [37] Rigden SP, Mehls O, Jones EH, Valderrábano F. Report on management of renale failure in Europe, XXVI, 1995. The child–adult interface: a report on Alport's syndrome, 1975–1993. The ERA-EDTA Registry. *Nephrol Dial Transplant* 1996;11(Suppl. 7):21–7.
- [38] Kolvek G, Podracka L, Rosenberger J, Stewart RE, van Dijk JP, Reijneveld SA. Kidney diseases in Roma and non-Roma children from eastern Slovakia: are Roma children more at risk? *Int J Public Health* 2014;59(6):1023–6.
- [39] Kenrick D. Historical dictionary of the gypsies (Romanies). 2nd ed. Lanham: Scarecrow Press Inc.; 2007.
- [40] Taylor J, Flinter F. Familial haematuria: when to consider genetic testing. *Arch Dis Child* 2014;99(9):857–61.
- [41] Savige J, Liu J, DeBuc DC, Handa JT, Hageman GS, Wang YY, et al. Retinal basement membrane abnormalities and the retinopathy of alport syndrome. *Invest Ophthalmol Vis Sci* 2010;51(3):1621–7.
- [42] Thomas AS, Baynham JT, Flaxel CJ. Macular holes, vitelliform lesions, and midperipheral retinoschisis in Alport syndrome. *Retin Cases Brief Rep* 2016;10(2):109–11.
- [43] Flinter FA, Cameron JS, Chantler C, Houston I, Bobrow M. Genetics of classic Alport's syndrome. *Lancet* 1988;2(8618):1005–7.
- [44] Rheault MN. Women and Alport syndrome. *Pediatr Nephrol* 2012;27(1):41–6.
- [45] Antignac C, Heidet L. Mutations in Alport syndrome associated with diffuse esophageal leiomyomatosis. *Contrib Nephrol* 1996;117:172–82.
- [46] Savige J, Gregory M, Gross O, Kashtan C, Ding J, Flinter F. Expert guidelines for the management of Alport syndrome and thin basement membrane nephropathy. *J Am Soc Nephrol* 2013;24(3):364–75.
- [47] Lemmink HH, Nillesen WN, Mochizuki T, Schröder CH, Brunner HG, van Oost BA, et al. Benign familial hematuria due to mutation of the type IV collagen alpha 4 gene. *J Clin Invest* 1996;98(5):1114–8.
- [48] Liapis H, Gaut JP. The renal biopsy in the genomic era. *Pediatr Nephrol* 2013;28(8):1207–19.
- [49] Kashtan CE. Alport syndrome and thin basement membrane nephropathy: diseases arising from mutations in type IV collagen. *Saudi J Kidney Dis Transpl* 2003;14(3):276–89.
- [50] Voskarides K, Damianou L, Neocleous V, Zouvani I, Christodoulidou S, Hadjiconstantinou V, et al. COL4A3/COL4A4 mutations producing focal segmental glomerulosclerosis and renal failure in thinbasement membrane nephropathy. *J Am Soc Nephrol* 2007;18(11):3004–16.
- [51] Dische FE. Measurement of GBM thickness and its application to the diagnosis of thin-membrane nephropathy. *Arch Pathol Lab Med* 1992;116(1):43–9.
- [52] Marcocci E, Uliana V, Bruttini M, Artuso R, Silengo MC, Zerial M, et al. Autosomal dominant Alport syndrome: molecular analysis of the COL4A4 gene and clinical outcome. *Nephrol Dial Transplant* 2009;24(5):1464–71.
- [53] Papazachariou L, Demosthenous P, Pieri M, Papagregoriou G, Savva I, Stavrou C, et al. Frequency of COL4A3/COL4A4 mutations amongst families segregating glomerular microscopic hematuria and evidence for activation of the unfolded protein response. Focal and segmental glomerulosclerosis is a frequent development during ageing. *PLOS ONE* 2014;9(12):e115015.
- [54] Morinière V, Dahan K, Hilbert P, Lison M, Lebbah S, Topa A, et al. Improving mutation screening in familial hematuric nephropathies through next generation sequencing. *J Am Soc Nephrol* 2014;25(12):2740–51.
- [55] Deltas C, Savva I, Voskarides K, Papazachariou L, Pierides A. Carriers of autosomal recessive Alport syndrome with thin basement membrane nephropathy presenting as focal segmental glomerulosclerosis in later life. *Nephron* 2015;130(4):271–80.
- [56] Voskarides K, Arsali M, Athanasioy Y, Elia A, Pierides A, Deltas C. Evidence that NPHS2-R229Q predisposes to proteinuria and renal failure in familial hematuria. *Pediatr Nephrol* 2012;27(4):675–9.
- [57] Stefanou C, Pieri M, Savva I, Georgiou G, Pierides A, Voskarides K, et al. Co-inheritance of functional podocin variants with heterozygous collagen IV mutations predisposes to renal failure. *Nephron* 2015;130(3):200–12.
- [58] Deltas C, Pieridis A, Voskarides K. The role of molecular genetics in diagnosing familial hematuria(s). *Pediatr Nephrol* 2012;27(8):1221–31.
- [59] Stratta P, Musetti C, Barreca A, Mazzucco G. New trends of an old disease: the acute post infectious glomerulonephritis at the beginning of the new millenium. *J Nephrol* 2014;27(3):229–39.
- [60] Gale DP, de Jorge EG, Cook HT, Martinez-Barricarte R, Hadjisavvas A, McLean AG, et al. Identification of a mutation in complement factor H-related protein 5 in patients of Cypriot origin with glomerulonephritis. *Lancet* 2010;376(9743):794–801.
- [61] Besbas N, Gulhan B, Gucer S, Korkmaz E, Ozaltin F. A novel CFHR5 mutation associated with C3 glomerulonephritis in a Turkish girl. *J Nephrol* 2014;27(4):457–60.
- [62] Servais A, Noël LH, Frémeaux-Bacchi V, Lesavre P. C3 glomerulopathy. *Contrib Nephrol* 2013;181:185–93.
- [63] Athanasioy Y, Voskarides K, Gale DP, Damianou L, Patsias C, Zavros M, et al. Familial C3 glomerulopathy associated with CFHR5 mutations: clinical characteristics of 91 patients in 16 pedigrees. *Clin J Am Soc Nephrol* 2011;6(6):1436–46.
- [64] Saposnik B, Binard S, Fenneteau O, Nurden A, Nurden P, Hurtaud-Roux MF, et al. Mutation spectrum and genotype-phenotype correlations in a large French cohort of MYH9-Related Disorders. *Mol Genet Genomic Med* 2014;2(4):297–312.
- [65] Savva I, Pierides A, Deltas C. RAAS inhibition and the course of Alport syndrome. *Pharmacol Res* 2016;107:205–10.
- [66] Palmer SC, Mavridis D, Navarese E, Craig JC, Tonelli M, Salanti G, et al. Comparative efficacy and safety of blood pressure-lowering agents in adults with diabetes and kidney disease: a network meta-analysis. *Lancet* 2015;385(9982):2047–56.
- [67] Zhang Y, Wang F, Ding J, Zhang H, Liu X, Wang S, et al. Long-term treatment by ACE inhibitors and angiotensin receptor blockers in children with Alport syndrome. *Pediatr Nephrol* 2016;31(1):67–72.
- [68] Kashtan CE, Ding J, Gregory M, Gross O, Heidet L, Knebelmann B, et al. Clinical practice recommendations for the treatment of Alport syndrome: a statement of the Alport Syndrome Research Collaborative. *Pediatr Nephrol* 2013;28(1):5–11.

- [69] Noone D, Licht CH. An update on the pathomechanism and future therapies of Alport syndrome. *Pediatr Nephrol* 2013;28(7):1025–36.
- [70] Eberhard OK, Kliem V, Offner G, Oldhafer K, Fangmann J, Pichlmay R, et al. Assessment of long-term risks for living related kidney donors by 24-h blood pressure monitoring and testing for microalbuminuria. *Clin Transplant* 1997;11(5 Pt 1):415–9.
- [71] Gross O, Weber M, Fries JW, Müller GA. Living donor kidney transplantation from relatives with mild urinary abnormalities in Alport syndrome: long-term risk, benefit and outcome. *Nephrol Dial Transplant* 2009;24(5):1626–30.
- [72] Kashtan CE. Women with Alport syndrome: risks and rewards of kidney donation. *Nephrol Dial Transplant* 2009;24(5):1369–70.