

Concept Paper

## Anticancer Effect of Rutin Isolated from the Methanolic Extract of *Triticum aestivum* Straw in Mice

Savita Dixit

Department of Chemistry, MANIT Bhopal, M.P. 462007, India; E-Mail: savitadixit1@yahoo.com or savitadixit@manit.ac.in; Tel.: +91-9425009287; Fax: +91-0755-2670562

External Editor: Yun Yen

Received: 13 August 2014; in revised form: 15 September 2014 / Accepted: 15 September 2014 /

Published: 23 October 2014

---

**Abstract:** Rutin is the bioactive flavanoid isolated from the straw part of *Triticum aestivum* and possess various pharmacological applications. The aim of this study is to evaluate the chemopreventive potential of rutin in an experimental skin carcinogenesis mice model system. Skin tumor was induced by topical application of 7,12-dimethyl benz(a) anthracene (DMBA) and promoted by croton oil in Swiss albino mice. To assess the chemopreventive potential of rutin, it was orally administered at a concentration of (200 mg/kg and 400 mg/kg body weight) continued three times weekly for 16th weeks. The development of skin carcinogenesis was assessed by histopathological analysis. Reductions in tumor size and cumulative number of papillomas were seen due to rutin treatment. Average latent period was significantly increased as compared to carcinogen treated control. Rutin produced significant decrease in the activity of serum enzyme serum glutamate oxalate transaminase (SGOT), serum glutamate pyruvate transaminase (SGPT), alkaline phosphatase (ALP) and bilirubin when compared with the control. They significantly increased the levels of enzyme involved in oxidative stress glutathione (GSH), superoxide dismutase (SOD) and catalase. The elevated level of lipid peroxidase in the control group was significantly inhibited by rutin administration. The results from the present study suggest the chemopreventive effect of rutin in DMBA and croton oil induced skin carcinogenesis in swiss albino mice and one of the probable reasons would be its antioxidant potential.

**Keywords:** rutin; papilloma; skin carcinogenesis; chemoprevention

---

## 1. Introduction

*Triticum aestivum* Linn. commonly known as wheat grass belongs to the Gramineae and is being used in many native drug preparations. *Triticum aestivum* possess high chlorophyll content and essential vitamins, minerals, vital enzymes, amino acids, dietary fibers. Pharmacological studies carried out with extracts from *Triticum* straw shows that this plant exerts several biological effects, such as: anti-ulcer [1], anti-arthritis [2], antioxidant [3], antimicrobial [4] and antidiabetic [5] activities.

Flavanoids produce a wide range of biological effects in several mammalian cell systems and this was proved by many *in vitro* and *in vivo* experiments [6]. Rutin also called rutoside, quercetin-3-rutinoside and sophorin extensively found in many plants, including *Triticum aestivum*. This flavanoid has a broad range of biological activities antimicrobial [7], anti-inflammatory [8,9], antioxidant [10], neuroprotective [11], antiviral [12], and antiulcerogenic [13]. The anticarcinogenic activity of rutin has not yet been fully explored. Cancer prevention could be achieved by avoidance of cancer causing substances, and by using chemopreventive agents that can inhibit initiation and also to act as blocking and suppressing agents [14]. In humans, rutin attaches to the iron ion, preventing it from binding to hydrogen peroxide which could otherwise create a highly reactive free radical that may damage cell. It is also antioxidant and therefore plays a role in preventing some cancer [15]. In the present study attempts have been made to understand the chemopreventive potential of rutin isolated from *Triticum aestivum* in DMBA croton oil induced skin carcinogenesis mice model system.

## 2. Material and Methods

### 2.1. Plant Material and Preparation of the Methanolic Extract

Straw of *Triticum aestivum* (Gramineae) were collected from one village near Neelbad, Bhopal, M.P., India. Herbarium was prepared and submitted for authentication at Sefia College of Science, Bhopal. Plant was authenticated by Dr. Zia-ul-Hassan. Plant material was dried under shade and pulverised using electric grinder. Firstly, dried sample was extracted with hexane at room temperature (30 °C) for 10 days with regular stirring in between, obtaining the hexanic extract. Thereafter, the material obtained by the extraction with hexane was macerated with methanol, yielding the methanolic extract. Furthermore, the methanolic extract was concentrated by rotary vacuum evaporator followed by filtration, yielding a yellow-green material (2.5% w/w yield). It was analyzed by ultra-violet, infrared, gas chromatography mass spectrometry and nuclear magnetic resonance spectroscopic analyses that revealed the presence of a high content of the flavonoid quercetin-3-*O*- $\alpha$ -L-rhamnopyranosyl-(1-6)  $\beta$ -D-glucopyranoside (rutin). This material was further purified by recrystallization with methanol to yield rutin (99% purity).

### 2.2. Chemicals

7,12-Dimethyl benzanthracene (DMBA) and croton oil was purchased from Sigma Aldrich. Other chemical reagents are commercially available and of analytical grade.

### 2.3. Animals

Swiss albino mice of either sex were selected at random from animal house of Pinnacle Biomedical Research Institute (PBRI), Bhopal. Animals were housed in poly propylene cages with sterile husk and provided standard pellet (Golden feeds, New Delhi, India) and water *ad libitum* as their feed throughout the experiment. The animals were maintained with a 12 h light dark cycle at  $22 \pm 2$  °C at controlled condition. All animal experiments were performed with prior permission of Institutional Animal Ethics Committee (IAEC) of PBRI, Bhopal (Reg No. 1283/c/09/CPCSEA).

### 2.4. Determination of the Effect of Rutin on DMBA Croton Oil Induced Skin Carcinogenesis

Three groups (6 animals per group) of Swiss albino mice were used for the study. Animals were dorsally shaved with hair clipper. Group 1 animals were treated with single dose of DMBA (100 µg/100 µL of acetone) over the shaven area of the skin of the mice afterwards 1% croton oil was applied on skin 3 times a week up to 16 week. After the single dose of DMBA, Group 2 animals were treated with rutin (200 mg/kg) orally each day after DMBA application till completion of experiment and 1% croton oil was applied on skin after one hour rutin administration three times a week. Group 3 animals were treated with the same procedure as that of Group 2 animals but the dose level of rutin was changed (400 mg/kg). After 14 days of DMBA application, mice were observed each week for incidence of skin tumors and its sizes, body weight and average latent period were recorded till 16th weeks.

### 2.5. Determination of the Effect of Rutin on Enzyme Involved in Oxidative Stress

At the last day of the experiment, animals of all the groups were sacrificed by cervical dislocation. The animals were immediately dissected to remove their skins which were washed in ice-cold saline (0.9% NaCl) and the extraneous material was removed. It was then weighed and blotted dry. A 10% tissue homogenate was prepared from part of the skin in 0.15 M Tris-KCL (pH 7.4), and the homogenate was then centrifuged at 12,000 rpm for 15 min.

For biochemical estimation, post mitochondrial supernatant, were used on the same day that animals were killed. The level of lipid peroxide (LPO) was estimated by using the method of Ando S *et al.* [16], GSH (Moron MA *et al.*) [17], SOD (Marklund *et al.*) [18], Catalases (Clainborn) [19] and protein estimation (Lowry *et al.*) [20].

### 2.6. Determination of the Effect of Rutin on Serum Enzyme Analysis

The blood was obtained from all animals by puncturing retro-orbital plexus. At room temperature, the blood samples were allowed to clot for 45 min. Serum was separated by centrifugation at 2500 rpm at 30 °C for 15 min and utilized for the determination of various biochemical parameters. The levels of SGOT, SGPT, SALP and serum bilirubin were estimated by using span diagnostic kit.

### 2.7. Histopathology

Paraffin blocks were prepared for processed formalin fixed tissue samples. Tissue sections (3–4 mm) were taken for hematoxylin–eosin (HE) staining and epidermal thickness was determined by microscopic examination of H & E-stained tissue sample.

### 2.8. Statistical Analysis

Values are recorded as mean  $\pm$  SD. The data obtained from different groups was analyzed by ANOVA. The value  $p < 0.05$  was considered statistically significant for all conduct experiment.

## 3. Results

The outcomes of the present study are furnished in Tables 1–3. A gradual decrease in body weight was noted in all animals of the different groups. Animals of groups II and III, given a continuous treatment of different dose of rutin orally as mentioned above along with the repeated application of croton oil, showed a significant reduction in the cumulative number of papillomas and tumor size (Figure 1B,C and Table 1) as compared to the treated control group (Figure 1A). The latency period was found to be  $10.10 \pm 5.17$  week in the carcinogen treated control group, whereas it was significantly higher in rutin treated groups.

**Table 1.** Chemopreventive effect of rutin against DMBA croton oil induced skin carcinogenesis in mice.

Treatment	Body Weight (g)		Number of Papilloma	Tumor Size	Average Latent Period <sup>a</sup>
	Initial	Final			
Group I (Control)	26.26 $\pm$ 2.16	22.75 $\pm$ 11.24	10.16 $\pm$ 5.03	2.06 $\pm$ 0.37	10.10 $\pm$ 5.17
Group II (Treated)	28.95 $\pm$ 1.65	25.14 $\pm$ 12.34	3.83 $\pm$ 2.99	1.23 $\pm$ 0.37	11.70 $\pm$ 5.23
Group III (Treated)	26.21 $\pm$ 4.00	24.72 $\pm$ 12.21	2.83 $\pm$ 1.60	0.98 $\pm$ 0.32	11.38 $\pm$ 5.11

<sup>a</sup> The lag between the application of the promoting agent and the appearance of 50% of tumors was determined. Average latent period =  $\sum fx/n$ ,  $f$  is the number of tumors appearing each week;  $x$  is the numbers of weeks and  $n$  is the total number of tumors.

**Table 2.** Effect of rutinon oxidative enzyme levels.

Treatment	GSH $\mu$ mole/mg Protein	SOD $\mu$ mole/mg Protein	Catalase U/mg Protein	LPO nmole/mg Protein
Group I (Control)	8.02 $\pm$ 0.96	59.59 $\pm$ 2.15	5.97 $\pm$ 1.07	4.82 $\pm$ 1.71
Group II (Treated)	27.24 $\pm$ 1.16 *	77.50 $\pm$ 0.84 *	33.73 $\pm$ 10.93 *	3.02 $\pm$ 0.37 *
Group III (Treated)	21.22 $\pm$ 0.49 *	80.05 $\pm$ 10.54 *	38.84 $\pm$ 20.18 *	2.7 $\pm$ 0.36 *

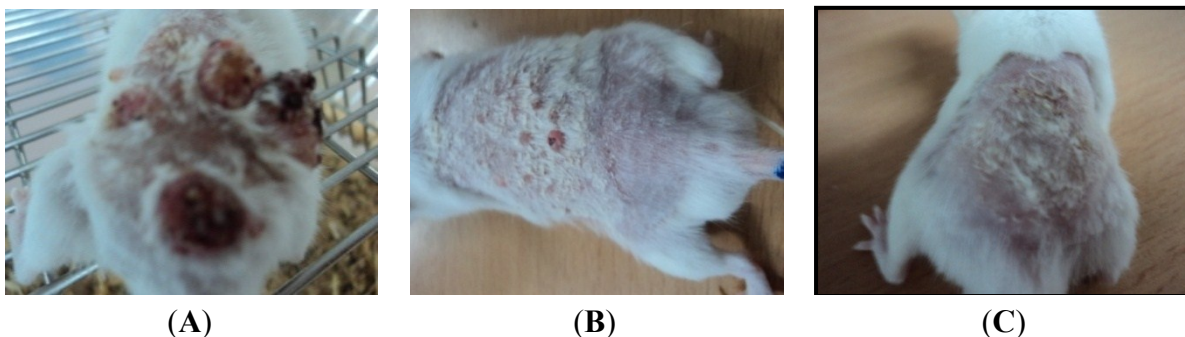
\*  $p < 0.05$ .

**Table 3.** Effect of rutinon serum enzyme levels.

Treatment	SGOTIU/L	SGPTIU/L	SALPIU/L	Bilurubbin mg/dL
Group I (Control)	162.73 $\pm$ 12.33	149.06 $\pm$ 17.00	231.52 $\pm$ 13.93	5.56 $\pm$ 2.53
Group II (Treated)	101.37 $\pm$ 6.36 *	69.91 $\pm$ 23.02 *	86.35 $\pm$ 47.16 *	2.21 $\pm$ 0.86 *
Group III (Treated)	85.26 $\pm$ 22.07 *	49.02 $\pm$ 24.06 *	75.41 $\pm$ 24.64 *	1.95 $\pm$ 0.76 *

\*  $p < 0.05$ .

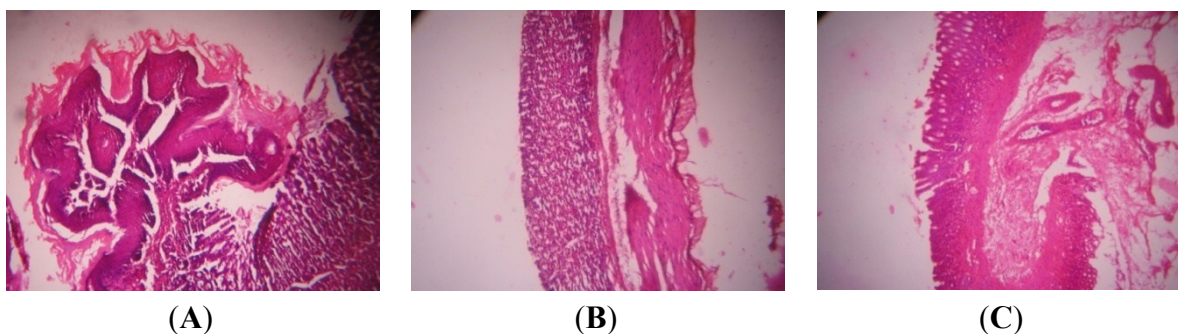
**Figure 1.** Rutin-induced reduction of tumor in “Swiss albino mice”: (A) Animal treated with water, DMBA and croton oil and observation was made at the last day of the experiment. (B) Animal treated with DMBA and croton oil as in (A) but with rutin infusion after the application of croton oil. (C) Animal treated with DMBA and croton oil as in (B) but with the increased concentration of rutin infusion.



A significant increase in GSH, SOD, catalase and protein level was noted in the skin of rutin administered animals (Groups II and III) than the control group animals (Group I) (Table 2). On contrary, the lipid peroxidase level was found to be decreased significantly in rutin administered animals as compared to control group animals. A significant decrease in enzyme serum glutamate oxalate transaminase and serum glutamate pyruvate transaminase, alkaline phosphatase and bilirubin level was noted in the serum of rutin administered animals (Groups II and III) than the control group animals (Group I) (Table 3).

In general the normal dermal layer consisted of two layers in which one has loose connective tissue and another has dense connective tissue called as papillary layer and reticular layer respectively. In DMBA and croton oil treated animals (Figure 2A) these layer starts differentiating in the form of papilloma with signs of abnormal architecture of epidermal layer and this was due to irregular proliferation of stratum spinosum cells, with abnormal thickening of stratum corneum and stratum spinosum. In rutin treated animals histological observation revealed that signs of tumor were present but hyperkeratosis and acanthosis were present but they were less as compared to control treatment (Figure 2B,C).

**Figure 2.** H&E stained cross-sections of mice skin: (A) Group I (water + DMBA + croton oil) (B) Group II (rutin 200 mg/kg+ DMBA + croton oil) (C) (rutin 400 mg/kg+ DMBA + croton oil).



#### 4. Discussion

Human epidemiological data indicate that regular use of certain medicinal plants suppress carcinogenesis in various organs [21]. So, it is becoming increasingly important to screen natural products which might suppress or reverse the process of carcinogenesis [22]. The results of the current study, and many others, indicate several beneficial effects of rutin. Skin carcinogenesis is based on the fact that initiation with the sequential application of a subthreshold dose of a carcinogen such as DMBA, followed by repetitive treatment with a noncarcinogenic promoter like croton oil (promotion) will lead to the development of skin tumors. Among the initiation and promotion steps, animal studies show that the promotion stage takes longer period to occur and it is reversible initially [23]. Therefore, cancer prevention by inhibition of tumor promotion is expected to be a resourceful approach. In the present study, rutin administration could significantly inhibit DMBA induced papilloma formation both in terms of incidence of tumour as well as mean number of papillomas.

Lipid peroxidation is a free radical chain reaction and are known to cause two main step of carcinogenesis *i.e.*, initiation and propagation. It is a highly destructive process. During carcinogenic process, lipid peroxidation is increased and a more complex and reactive compounds such as malondialdehyde (MDA) and 4-hydroxynonenal was obtained. These products of lipid peroxidation were observed to be mutagenic and carcinogenic. It is therefore implied that agents that can reduce the production of free radicals *in vivo* may be considered to have the potential for chemoprevention [24]. In the present study, administration of rutin significantly reduced the level of LPO in mice exposed to DMBA and croton oil and subsequently decreases the incidence of skin tumor.

GSH play a crucial role in preventing the oxidation of glutathione. In control group the activities of GSH was decreased while rutin treatment increased the GSH level, which clearly suggest their antioxidant property. Antioxidants are reported to possess a chemopreventive property [25]. Antioxidants are generally regarded as the first line of defense against free radical stress and suggest their usefulness in eliminating the risk of oxidative damage induced during carcinogenesis. SOD and CAT are acts as mutually supportive antioxidative enzymes, which provide protective defense against reactive oxygen species (ROS). There was a significant enhancement in the levels of GSH, SOD, catalases and protein level in the rutin treated group compared to control group animals.

DMBA treatments generate LPO and ROS in the affected area of the skin and ultimately lead to carcinogenesis. This oxidative stress was easily observable in control group as level of LPO was higher and level of Catalase, SOD, and GSH was lower. The beneficial action of rutin is probably due to its ability to stimulate the antioxidant enzymes in the cells. These increases in enzyme activity effectively down-regulate the generation of ROS and LPO in the skin and thus might reduce the incidences of skin papillomas on the treated areas.

#### 5. Conclusions

Thus it may be concluded from the present study that rutin isolated from *Triticum aestivum* could significantly enhance the antioxidant enzyme levels like GSH, SOD, Catalase and inhibited lipid peroxides hence showing its role in detoxification pathway. Both histology and enzyme activities suggest that environmental effects that lead to skin carcinogenesis can be inhibited by oral

combination of rutin in the daily diet to achieve some protection against skin cancer. The results from the present study indicate that rutin can inhibit papilloma growth.

Further *in silico* study of rutin will also be performed by using the computational background to confirm the activity and we also test rutin against different carcinoma cell lines.

### Acknowledgments

Author is grateful to Gajendra Dixit, Dean R & C, MANIT, Bhopal, India and Manvendra Karchuli, Research Officer, PBRI, Bhopal, India and Huma Ali, Research Scholar to support this research and that provided facilities to achieve the desired goals of the study.

### Conflicts of Interest

The author declares no conflict of interest.

### References

1. Singh, N.; Verma, B.P.; Pandey, B.R. Therapeutic potential of organic *Triticum aestivum* linn. (wheat grass) in prevention and treatment of chronic diseases: An overview. *Int. J. Pharm. Sci. Drug Res.* **2012**, *4*, 10–14.
2. Nenonen, M.T.; Helve, T.A.; Rauma, A.L.; Hanninen, O.O. Uncooked, lactobacilli-rich, vegan food and rheumatoid arthritis. *Br. J. Rheumatol.* **1998**, *37*, 274–281.
3. Mates, M.J.; Jimenez, S.; Fransisca, M. Role of reactive oxygen species in apoptosis: Implication for cancer therapy. *Int. J. Biochem. Cell Biol.* **2000**, *32*, 157–170.
4. Singh, A.; Sharma, U.S.; Sharma, U.K.; Mishra, V.; Ranjan, S. *In vitro* antimicrobial activity of the *Triticum aestivum* straw extracts. *Int. J. Drug Discov.* **2010**, *2*, 1–4.
5. Ahmad, M.; Qureshi, R.; Arshad, M.; Khan, M.A.; Zafar, M. Traditional herbal remedies used for the treatment of diabetes from district Attock (Pakistan). *Pak. J. Bot.* **2009**, *41*, 2777–2782.
6. Zhao, M.; Yang, B.; Wang, J.; Liu, Y.; Yu, L.; Jiang, Y. Immunomodulatory and anticancer activities of flavonoids extracted from litchi (*Litchi chinensis* Sonn) pericarp. *Int. Immunopharmacol.* **2007**, *7*, 162–166.
7. Arima, H.; Ashida, H.; Danno, G. Rutin-enhanced antibacterial activities of flavonoids against *Bacillus cereus* and *Salmonella enteritidis*. *Biosci. Biotechnol. Biochem.* **2002**, *66*, 1009–1014.
8. Guardia, T.; Rotelli, A.E.; Juarez, A.O.; Pelzer, L.E. Anti-inflammatory properties of plant flavonoids. Effect of rutin, quercetin and hesperidin on adjuvant arthritis in rat. *II Farmaco* **2001**, *56*, 683–687.
9. Afanas'ev, I.B.; Ostrakhovitcha, E.A.; Mikhalechik, E.V.; Ibragimova, G.A.; Korkina, L.G. Enhancement of antioxidant and anti-inflammatory activities of bioflavonoid rutin by complexation with transition metals. *Biochem. Pharmacol.* **2001**, *61*, 677–684.
10. Ostrakhovitcha, E.A.; Afanas'ev, I.B. Oxidative stress in rheumatoid arthritis leukocytes: Suppression by rutin and other antioxidants and chelators. *Biochem. Pharmacol.* **2001**, *62*, 743–746.

11. Gupta, R.; Singh, M.; Sharma, A. Neuroprotective effect of antioxidants on ischaemia and reperfusion-induced cerebral injury. *Pharmacol. Res.* **2003**, *48*, 209–215.
12. Middleton, J.; Kandaswami, E.; Theoharides, C. The effects of plant flavonoids on mammalian cells: Implications for inflammation, heart disease, and cancer. *Pharmacol. Rev.* **2000**, *52*, 673–751.
13. La Casa, C.; Villegas, I.; de la Lastra, C.A.; Motilva, V.; Calero, M.J.M. Evidence for protective and antioxidant properties of rutin, a natural flavone, against ethanol induced gastric lesions. *J. Ethnopharmacol.* **2000**, *71*, 45–53.
14. Davis, L.; Kuttan, G. Effect of *Withania somnifera* on DMBA induced carcinogenesis. *J. Ethnopharmacol.* **2001**, *75*, 165–168.
15. Atanassova, M.; Bagdassarian, V. Rutin content in plant products. *J. Univ. Chem. Technol. Metal.* **2009**, *44*, 201–203.
16. Ando, S.; Kon, K.; Aino, K.; Totani, Y. Increased levels of lipid peroxides in aged rat brain as revealed by direct assay of peroxide values. *Neurosci. Lett.* **1990**, *113*, 199–204.
17. Moron, M.A.; Depierre, J.W.; Mannervick, B. Levels of glutathione, glutathione reductase and glutathione-S-transferase activities in rat liver. *J. Biochim. Biophys. Acta* **1979**, *582*, 67–68.
18. Marklund, S.; Marklund, G. Involvement of the superoxide anion radical in the autoxidation of pyrogallol and a convenient assay for superoxide dismutase. *Eur. J. Biochem.* **1974**, *47*, 469–474.
19. Claiborne, A. *Handbook of Methods in Oxygen Radical Research*; CRC Press: Boca Raton, FL, USA, 1985.
20. Lowry, O.H.; Rosebrough, N.J.; Farr, A.L.; Randall, R.J. Protein measurement with the Folin phenol reagent. *J. Biol. Chem.* **1951**, *193*, 265–275.
21. Sengupta, A.; Ghosh, S.; Bhattacharjee, S.; Das, S. Indian food ingredients and cancer prevention—An experimental evaluation of anticarcinogenic effects of garlic in rat colon. *Asian Pac. J. Cancer Prev.* **2004**, *5*, 126–132.
22. Nishino, H.; Murakoshi, M.; Mou, X.Y.; Wada, S.; Masuda, M.; Ohsaka, Y. Cancer prevention by phytochemicals. *Oncology* **2005**, *69*, 38–40.
23. Slaga, T.J.; Fischer, S.M.; Nelson, K.; Gleason, G.L. Studies on the mechanism of skin tumor promotion: Evidence for several stages in promotion. *Proc. Natl. Acad. Sci. USA* **1980**, *77*, 3659–3663.
24. Zhang, J.; Xu, Y.M.; Wang, W.M.; Liu, Y.Q. Experimental study on anti-tumor effect of extractive from *Celastrus orbiculatus* in vivo. *Zhongguo Zhong Yao Za Zhi* **2006**, *31*, 1514–1516.
25. Blessy, D.; Suresh, K.; Manoharan, S.; Vijayaanand, M.A.; Sugunadevi, G. Evaluation of Chemopreventive Potential of *Zingiber Officinale Roscoe* Ethanolic Root Extract on 7,12-dimethyl Benz[a]anthracene Induced Oral Carcinogenesis. *Res. J. Agric. Biol. Sci.* **2009**, *5*, 775–781.