

# Electroencephalogram and magnetic resonance imaging comparison as a predicting factor for neurodevelopmental outcome in hypoxic ischemic encephalopathy infant treated with hypothermia

Francesca Del Balzo, Stella Maiolo, Paola Papoff, Luigi Giannini, Corrado Moretti, Enrico Properzi, Alberto Spalice

Division of Child Neurology, Department of Pediatrics, La Sapienza University, Rome, Italy

## Abstract

Hypoxic-ischemic encephalopathy (HIE) is an important cause of acute neurological damage in newborns at (or near) term. Several trials in recent years have shown that moderate hypothermia by total body cooling or selective head is an effective intervention to reduce mortality and major disability in infants survived a perinatal hypoxic-ischemic attack. Follow-up in these patients is very important to establish neurodevelopmental outcome, and specific markers can lead us to detect predicting sign for good or poor outcome. We reported a few cases of newborn with HIE treated with hypothermia, in whom the comparison between electroencephalogram (EEG) and magnetic resonance imaging (MRI) represents the first marker for neurodevelopment outcome prediction. The continuous EEG monitoring showed a depressed EEG activity with diffuse burst depression in 7 patients. No epileptic abnormalities were registered. In 10 out of 20 patients no abnormalities of the background activity and no epileptic abnormalities were observed. We found that a depressed EEG activity during the first 72 h of life and a diffused alteration of basal ganglia at MRI were correlated with a poor neurodevelopmental outcome at 18 months of follow-up.

## Introduction

Hypoxic-ischemic encephalopathy (HIE) is an important cause of acute neurological damage in newborns (NB) at or near term. Its incidence in developed countries is low, affecting approximately 2-3 cases per 1000 live NB at gestational age of  $\geq 36$  weeks, leading to important consequences, in terms of neonatal morbidity and long-term neurological disability.<sup>1</sup>

Throughout the 20th century, we have had no approach and specific therapeutic allow to prevent or minimize the brain damage associated with hypoxic-ischemic aggression of the perinatal brain. In recent years, several trials have shown that reducing the body temperature of 3-4°C (moderate hypothermia) by total body cooling or selective head, if commenced early (before 6 h of life) and maintained for 72 h, is an effective intervention to reduce mortality and major disability in infants who survive a perinatal hypoxic-ischemic attack.<sup>2,3</sup>

Electroencephalogram (EEG) has a major role in detecting severe HIE brain dysfunction.<sup>4</sup> In particular, its background abnormalities including amplitude, presence of discontinuity, length of inter-burst interval, absence of sleep-wake cycling and presence of seizures are related to the dysfunction severity both in non-cooled and cooled infants with HIE.<sup>5-11</sup> Moreover, EEG is also an useful predictor of HIE infants prognosis, as several studies confirmed the prognostic value of serial EEGs modifications or long lasting monitoring and neuroimaging techniques.<sup>5-11</sup> A brain magnetic resonance imaging (MRI) adds detailed information about the various lesion patterns that have been described in HIE.<sup>12-16</sup> Lesions vary according to the kind of predominant HI insult: an acute severe global hypoxic-ischemic event affects mostly the basal ganglia (BG), the thalamus (T), and the posterior limb of the internal capsule (PLIC). On the other hand, when a prolonged partial hypoxia-ischemia predominates, lesions usually involve WM and cortex but spare the BG-T and PLIC.<sup>12</sup> The presence of BG-T lesions is highly associated with death or cerebral palsy (CP), predominantly spastic or dystonic quadriplegia.<sup>13-16</sup> The severity of BG-T lesions defines CP severity and nature.<sup>16</sup> The most severe forms of BG-T injury can involve also the brainstem and often associate with early death. On the contrary, infants without MRI BG-T damages have a largely normal outcome.<sup>16</sup> Matching the two techniques usually provides more reliable diagnostic and prognostic indications.<sup>17</sup> We reported on our experience in a small series of newborn with HIE treated with hypothermia in whom a comparison between EEG and MRI was used as first marker for predicting neurodevelopment outcome. We observed that a depressed EEG activity in the first 72 h of life and a diffused alteration of basal ganglia at MRI were related with a poor neurodevelopmental outcome at the 18 months follow-up.

## Materials and Methods

### Study population-setting

Full term newborns delivered at gestational

Correspondence: Alberto Spalice, Division of Child Neurology, Department of Pediatrics, La Sapienza University, Viale Regina Elena 324, 00161 Rome, Italy.  
Tel.: +06.499.79311/13/14 - Fax: +06.499.79312.  
E-mail: a.spalice@tiscali.it

Key words: hypothermia, neonates, magnetic resonance imaging, long term, electroencephalogram monitoring.

Acknowledgements: the authors would thank Dr. Valerio Rocchi and Dr. Donata De Stefano (EEG technicians, Child Neurology Division, La Sapienza University, Rome, Italy) for EEG monitoring during hypothermia and follow-up.

Contributions: the authors contributed equally.

Conflict of interests: the authors declare no potential conflict of interests.

Received for publication: 27 June 2014.  
Revision received: 8 August 2014.  
Accepted for publication: 11 August 2014.

This work is licensed under a Creative Commons Attribution NonCommercial 3.0 License (CC BY-NC 3.0).

©Copyright F. Del Balzo et al., 2014  
Licensee PAGEPress, Italy  
Pediatric Reports 2014; 6:5532  
doi:10.4081/pr.2014.5532

age higher than 36 weeks and with birth weight higher than 1800 g admitted for HIE to the Neonatal Intensive Care Units (NICUs) and Pediatric Intensive Care Units (PICUs) of the La Sapienza University of Rome, Italy. All parents gave their informed consent and the study protocol was approved by the Sapienza University committee on human research.

## Hypothermia

All newborn were treated with moderate (33.5°C) hypothermia for 72 hours. Outborn patients were initially cooled to 35°C at the birth hospital, avoiding heating and using ice packs during the transfer to NICU. In all the centers a cooling blanket with an esophageal probe was used to induce hypothermia; the esophageal temperature was then lowered by the blanket's servomechanism. Rectal temperature was monitored by a rectal probe connected to a cardiomonitor. After 72 hours of hypothermia, all newborns were gradually rewarmed up to 36.5-37°C over the following 6-12 hours (0.5°C/h). During the hypothermia, vital parameters were continuously monitored.

## Neurological follow-up

The needed follow-up duration for neuro-motor disabilities and cognitive loss monitor-

ing was 18 months. Every newborn was evaluated beyond the neonatal period, at 1, 3, 6, 12 and 18 months of life. Standard EEG were evaluated within one week and repeated if abnormal. Within the first week and three months of age, newborns were studied with Neonatal Hammersmith neurological examination and General Movement (GMs) assessment. The Hammersmith Infant Neurological Examination was performed between 3 and 6 months of life. An evaluation of mental and motor development was performed with the Bayley Scales of Infant and Toddler Development 3rd edition measure at 12 and 18 months.

Bayley scales were used to measure major areas: cognitive, language, motor, social-emotional and adaptive functioning.

### Neuroradiologic follow-up

Standard cerebral MRI, diffusion tensor imaging (DTI) and spectroscopy were performed at the end of the hypothermic treatment within the first week, at 3 and 18 months.

### Inclusion criteria

The treatment with therapeutic hypothermia was reserved to newborns with gestational age  $\geq 36$  weeks and birth weight  $\geq 1800$  g who fulfilled the following criteria: i) *metabolic criteria*: Apgar score  $\leq 5$  at 10 min, or persisting need for resuscitation, including endotracheal intubation or mask ventilation for more than 10 min after birth, or acidosis ( $\text{pH} \leq 7.0$  and/or base deficit  $\geq -16$  mmol/L in umbilical cord blood or arterial, venous, or capillary blood) within 60 min from birth; ii) *neurological criteria* (modified from Sarnat and Sarnat): moderate to severe encephalopathy consisting of impaired state of consciousness (irritability, lethargy, stupor, or coma) and  $\geq 1$  of the following signs: hypotonia, or abnormal reflexes including oculomotor or pupil abnormalities, or absent or weak suctioning, or clinical seizures.

### Exclusion criteria

They are: i) newborns with gestational age less than 36 weeks, with birth weights less than 1800 g, or admitted at the NICU after 6 hours of life; ii) newborns with major congenital abnormalities or other syndromes including brain; malformations, congenital viral infections or evidence of encephalopathy other than HIE; iii) informed consent refused.

### Outcome

Outcome was based on combined frequency of mortality and severe neurodevelopmental disability in survivors at 18 months of age. Severe disability is defined as Bayley III cognitive development index 3 SDs below mean or

any one of the components of severe sensorimotor disability (e.g. inability to walk, sit, feed using hands, communicate (Bayley III language development index 3 SDs below mean), hear (80 dB sensory neural hearing loss) or see. At 18 months of life the following outcomes were also assessed: i) multiorgan dysfunction (adverse events in three or more organ systems); ii) bilateral sensorineural hearing loss more than 40 dB; iii) epilepsy (recurrent seizures beyond the neonatal, period requiring anticonvulsant treatment); iv) developmental delay; v) multiple disabilities (epilepsy, cortical visual impairment, sensorineural hearing loss, developmental delay).

Finally, the neuroradiologic outcome was assessed by comparing images of standard cerebral MRI, DTI and spectroscopy performed within the first 7 days, at 3 months and 18 months of age. Brain injuries were classified as isolated lesions of the white matter (WM), of basal ganglia and thalami (BGT), with or without involvement of posterior limb of 2.3.the internal capsule (PLIC), of cortex (COR), or various combinations of such lesions.

Serial EEG recordings were taken at four-to-six hours after birth before starting hypothermic treatment, and prolonged for 72 h during hypothermia, at the 7th and the 9th day of life. A multichannel digital video EEG system (Sirius-EBNeuro) recorded EEGs. Electrodes were applied according to the international 10–20 system, modified for neonates. They were applied to the scalp at Fp1-C3-T3-O1-Fp2-C4-T4-O2. Other channels were used to record electrocardiogram, pneumogram, electroculogram. Each recording lasted more than 2 hours, to contain at least one sleep/wake cycle. EEGs were evaluated and rated by an expert child neurophysiologist, blinded to the MRI data and not involved in these infants care (AS). EEG abnormalities during the first days of life were evaluated. Background activity was

classified as stage i) normal: normal pattern for gestational age or discrete abnormalities; ii) mild abnormalities: continuous over more than 50% of the time, delta activity, borderline, maturational delay with low voltage and low reactivity; iii) moderate abnormalities: discontinuous more than 50% of the time without fluctuations or reactivity; or iv) major abnormalities: inactive pattern or low voltage and theta tracing or paroxysmal tracing.

## Results

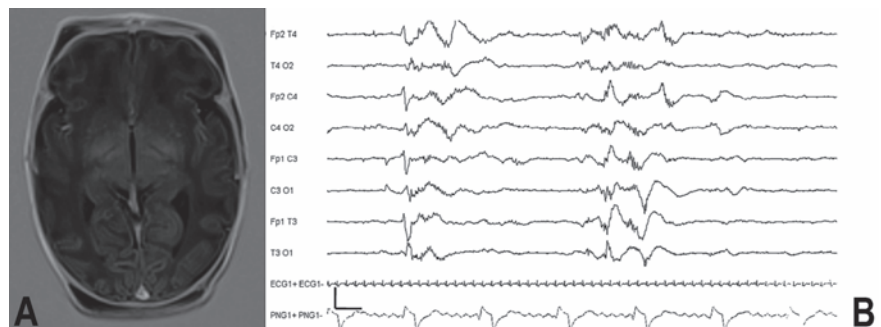
We enrolled 20 newborns (7F, 13M). The patients' perinatal history was characterized by no risk factors in 13 neonates, while among the other 7 only two had recognized risk factor as maternal fever. The EEG was performed during 72 hours of hypothermia and at ten days from rewarming (Figure 1B). The monitoring showed a depressed EEG activity with diffuse burst depression in 7 patients. No epileptic abnormalities were registered. In 10 out of 20 patients no abnormalities of the background activity and no epileptic abnormalities were observed.

In the other 3 patients we observed a depressed activity with sporadic spike and wave anomalies in the central-temporal region. The presence/absence of seizures (electrical or electro-clinical) and severity of seizures (0 = no seizure, 1 = isolated seizures, 2 = status epilepticus) was also recorded.

A seizure was defined as a sudden, repetitive, stereotyped discharge lasting at least 10 s: intermittent ( $< 3$  per hour), frequent (P3 per hour) or status epilepticus (P50% of 1-h epoch containing seizure activity).

Regarding seizures, 17 infants had no seizure, 2 had isolated seizures and 1 had status epilepticus.

There is no correlation with the severity of



**Figure 1. Patient 4: A) a magnetic resonance imaging-T1 weighted images: diffuse hyperintensity of the basal ganglia; B) electroencephalogram showing at 72 hours diffuse slowing background activity with burst suppression.**

MRI lesion.

The MRI was performed at 7 days from starting hypothermia (Figure 1A). MRI was normal in 11 pts. In 7 babies a diffuse hyperintensity of the basal ganglia was observed. In 2 neonates a lesion of the internal capsula and a lesion of the caudate nuclei were found.

MRI spectroscopy added no valuable results. No biochemical markers alterations were observed. At ten days after rewarming, EEG was performed showing no abnormalities in 10 infants; there were still present a depressed background activity in 7 neonates and some epileptic anomalies in 3 cases. During follow-up we performed a new MRI at 1 months after rewarming. The MRI was normal in 11 infants, while confirmed the diffuse hyperintensity of basal ganglia in 6. A neurological examination was performed at the beginning of the study being normal in 11 babies. In 4 children diffuse hypertonus was observed while in the remaining 5 generalized hypotonia was the most important sign, seen in 4 patients and in 1 hemiparesis was noticed. We evaluated infants at 3-6-12-18 months. The outcome was good in 11 neonates, with a normal neurological examination at 18 months of follow-up. In 4 babies hypertonia was the most important sign; 2 patients showed hypotonia, 1 left hemiparesis, 2 children died at follow-up (MRI, EEG and patients' characteristics are summarized in Table 1).

## Discussion and Conclusions

In newborns suffering from HIE, electrophysiological and neuroimaging techniques are useful and valuable methods both to evaluate severity of cerebral dysfunction and to establish an early and accurate prognosis.<sup>5-16</sup> Data collected from clinical examination and from laboratory are less reliable than those mentioned above in assigning early and accurate prognosis to these infants.<sup>17</sup>

Therapeutic mild hypothermia has been established as a successful technique to limit secondary cerebral damage in HIE and its use is increasingly spreading worldwide.<sup>1-3</sup>

Following HIE, typical MRI patterns of lesion have been previously described.<sup>12-16</sup> An acute severe global hypoxic-ischemic event affects mostly BG, T and PLIC whereas a prolonged partial hypoxic-ischemic insult affects usually WM and cortex but spares BG, T and PLIC.<sup>12</sup> Systemic hypothermia has been reported to selectively protect the cortex from the hypoxic insult and to reduce lesions in BG, T, WM and PLIC.<sup>12,13</sup>

Neurophysiological and neuroimaging data from our sample of infants undergoing hypothermic treatment due to HIE, are not different from those of previous studies. EEGs varied from inactive background to continuous

background with mild abnormalities, while MRI varied from severe BG-T and WM lesions to normal MRI. In our study severity of EEG background was associated with prevalent BG-T and WM lesions at MRI. In spite of slight methodology differences, this relationship has been already reported both in noncooled and cooled infants.<sup>17,18</sup> Nash and colleagues continuously video-EEG monitored babies from the beginning of the cooling procedure throughout the three cooling days and after the rewarming.<sup>18</sup>

They found that none of the newborns with a normal EEG background at the beginning of cooling had moderate to severe injury. Moreover, they found that all infants whose EEG background showed excessively discontinuity or extremely low voltage at the end of cooling, had moderate to severe MRI lesions. Our data are quite similar; as a matter of fact none of our newborns with mild EEG abnormalities at 6 and 24 h showed MRI lesion, whereas all infants with low voltage background at 72 h EEG exhibited moderate to severe BG-T injuries.

The persistence of a discontinuous EEG pattern after the first week of life has already been reported to be associated with severe neurological sequelae or death.<sup>18-20</sup> In our sample, a persistent discontinuity was always associated with MRI BG-T lesion which is known to be predictive of CP.<sup>16</sup> Burst suppres-

**Table 1. Electroencephalogram, magnetic resonance imaging and clinical characteristics.**

Sex	EEG (72h)	EEG	MRI 1week+ spettrosc	MRI 1 month	Neurological exam	Follow up 18 months
F	DBA, BS	DBA, BS	BGH	BGH	Generalized hypertonia, hypotonia neck flexors	Hypertonia
F	DBA, BS	DBA, BS	BGH	BGH	Generalized hypotonia, neck flexors	Hypotonia
M	DBA, BS	DBA, BS	BGH	BGH	Hypertonia	Hypertonia
F	DBA, BS	DBA, BS	BGH	BGH	Hypertonia	Hypertonia
M	N	N	N	N	N	N
M	N	N	N	N	N	N
M	DBA, BS	DBA, SPW	BGH, lesion of the right caudate nucleus	BGH	Hypotonia	Hypotonia
M	DBA, BS	DBA, SPW	BGH	BGH	Hypertonia	hypertonia
F	N	N	N	N	N	N
M	N	N	N	N	N	N
F	N	N	N	N	N	N
M	N	N	N	N	N	N
M	N	N	N	N	N	N
M	N	N	N	N	N	N
F	N	N	N	N	N	N
M	DBA, SPW	DBA, SPW	N	N	N	N
F	DBA, SPW	DBA, SPW	Lesion of the internal (right)	Lesion of the internal capsula	Left hemiparesis	Left hemiparesis
M	N	N	N	N	N	N
M	DBA, BS	DBA, SPW	BGH	BGH	Severe hypotonia	Died at follow-up
M	DBA, SPW	DBA, SPW	Lesion of the internal BGH left	Lesion of the internal capsula	Severe hypotonia	Died at follow-up

EEG, electroencephalogram; MRI, magnetic resonance imaging; N, normal EEG activity; DBA, depressed background activity; BS, burst suppression; SPW, sporadic spike and wave; BGH, basal ganglia hyperintensity.

sion pattern or continuous flat EEG is a sign of encephalopathy that can be due to several conditions like hypoxia, anesthesia, trauma. All these conditions lead to thalamo-cortical network alteration through different mechanisms (edema, inflammation, metabolic imbalance, etc.). It is well known that acute and deep hypoxic injury in the neonatal brain produce BG-T lesions, so it is not unexpected to find an association between BG-T lesions severity and EEG severity pattern.

Thus, for MRI lesions, as well as for clinical outcomes, early EEG is an excellent prognostic indicator if only mild abnormalities are present. Mildly abnormal EEG loses ability to predict a good MRI as days elapse. Our data confirm the association between EEG background acuteness and MRI severity lesions. The persistence of discontinuity or low voltage activity after first days is always associated with BGT lesions. The presence of only mild EEG anomalies during the first 2 days predicts the absence of BGT lesions (100%). Further study with larger population, and collaborative projects, are needed to better clarify the role of EEG and MRI in cooled babies

## References

- Shankaran S, Laptook AR, Ehrenkranz RA, et al. Whole body hypothermia for neonates with hypoxic-ischemic encephalopathy. *N Engl J Med* 2005;353:1574-84.
- Azzopardi D, Brocklehurst P, Edwards D, et al. The Toby study. Whole body hypothermia for the treatment of perinatal asphyxial encephalopathy: a randomized controlled trial. *BMC Pediatr* 2008;8:17.
- Azzopardi D, Strohm B, Edwards AD, et al. Moderate hypothermia to treat perinatal asphyxial encephalopathy. *N Engl J Med* 2009;361:1349-58.
- Walsh BH, Murray DM, Boylan GB. The use of conventional EEG for the assessment of hypoxic ischaemic encephalopathy in the newborn: a review. *Clin Neurophysiol* 2011;122:1284-94
- Mariani E, Scelsa B, Pogliani L, et al. Prognostic value of electroencephalograms in asphyxiated newborns treated with hypothermia. *Pediatr Neurol* 2008;39:317-24.
- Holmes G, Rowe J, Hafford J, et al. Prognostic value of the electroencephalogram in neonatal asphyxia. *Electroencephalogr Clin Neurophysiol* 1982;53: 60-72.
- Wertheim D, Mercuri E, Faundez JC, et al. Prognostic value of continuous electroencephalo-graphic recordings in full term infants with hypoxic ischaemic encephalopathy. *Arch Dis Child Fetal Neonatal Ed* 1994;71:F97-102.
- Van Lieshout HB, Jacobs JW, Rotteveel JJ, et al. The prognostic value of the EEG in asphyxiated newborns. *Acta Neurol Scand* 1995;91:203-7.
- Biagioni E, Bartalena L, Boldrini A, et al. Constantly discontinuous EEG pattern in full-term neonates with hypoxicischaemic encephalopathy. *Clin Neurophysiol* 1999;110: 1510-5.
- Lester Khan R, Lahourgue Nunes M, Garciasda Silva LF, Costa da Costa J. Predictive value of sequential electroencephalogram (EEG) in neonates with seizures and its relation to neurological outcome. *J Child Neurol* 2008;23:144-5.
- Murray DM, Boylan GB, Ryan CA, Connolly S. Early EEG findings in hypoxic-ischemic encephalopathy predict outcomes at 2 years. *Pediatrics* 2009;124:e459-67.
- Rutherford MA, Pennock JM, Counsell SJ, et al. Abnormal magnetic resonance signal in the internal capsule predicts poor neurodevelopmental outcome in infants with hypoxic-ischemic encephalopathy. *Pediatrics* 1998;102:323-8.
- Rutherford MA, Azzopardi D, Whitelaw A, et al. Mild hypothermia and the distribution of cerebral lesions in neonates with hypoxic-ischemic encephalopathy. *Pediatrics* 2005;116:1001-6.
- Mercuri E, Ricci D, Cowan FM, et al. Head growth in infants with hypoxic-ischemic encephalopathy: correlation with neonatal magnetic resonance imaging. *Pediatrics* 2000;106:235-43.
- Cheung PY, Robertson CMT. Predicting the outcome of term neonates with intrapartum asphyxia. *Acta Paediatr* 2000;89: 262-71.
- Mercuri E, Rutherford M, Barnett A, et al. MRI lesions and infants with neonatal encephalopathy. Is the Apgar score predictive? *Neuropediatrics* 2002;33:150-6.
- Briatore E, Ferrari F, Pomerio G, et al. EEG findings in cooled asphyxiated newborns and correlation with site and severity of brain damage. *Brain Dev* 2012 Aug 4. [Epub ahead of print]
- El-Ayuoty M, Abdel-Hady H, El-Mogy S, et al. Relationship between electroencephalography and magnetic resonance imaging after hypoxic-ischemic encephalopathy at term. *Am J Perinatol* 2007;24:467-73.
- Nash KB, Bonifacio SL, Glass HC, et al. Video-EEG monitoring in newborns with hypoxic-ischemic encephalopathy treated with hypothermia. *Neurology* 2011;76:556-62.
- Takeuchi T, Watanabe K. The EEG evolution and neurological prognosis of neonates with perinatal hypoxia. *Brain Dev* 1989;11:115-20.