

Case Report

# Dent Disease Type 1: Still an Under-Recognized Renal Proximal Tubulopathy: A Case Report

Monika Vitkauskaitė<sup>1,\*</sup>, Agnė Čerkauskaitė<sup>1,2</sup> and Marius Miglinas<sup>1,2</sup> 

<sup>1</sup> Faculty of Medicine, Vilnius University, 03101 Vilnius, Lithuania

<sup>2</sup> Nephrology Center, Vilnius University Hospital Santaros Klinikos, 08661 Vilnius, Lithuania

\* Correspondence: vitkausk.monika@gmail.com or monika.vitkauskaite@vu.mf.stud.lt; Tel.: +370-69219763

**Abstract:** Dent disease is a rare renal tubular disorder that appears almost exclusively in males. The diagnosis is still challenging, and therefore Dent disease is occasionally misdiagnosed. We report a case of a 45-year-old man with Dent disease who developed renal failure. Since the age of 7 months, he persistently exhibited proteinuria. At the age of 24 years, he underwent kidney biopsy, which revealed focal segmental glomerulosclerosis. The patient's brother was found to have proteinuria since he was 2 years old. At the age of 45 years, the patient was transferred to a tertiary care nephrologist, and Dent disease was suspected. Genetic testing revealed a CLCN5 mutation. We highlight the broad spectrum of clinical manifestations in Dent disease and the importance of having a high clinical suspicion to attain a definitive diagnosis. Furthermore, future research regarding the clinical course of the disease, prognosis, and effective treatment options is needed.

**Keywords:** dent disease; nephrology; renal failure; rare disease; genetic; case report



**Citation:** Vitkauskaitė, M.; Čerkauskaitė, A.; Miglinas, M. Dent Disease Type 1: Still an Under-Recognized Renal Proximal Tubulopathy: A Case Report. *Reports* **2022**, *5*, 50. <https://doi.org/10.3390/reports5040050>

Academic Editor: Nicholas Obermüller

Received: 4 October 2022

Accepted: 24 November 2022

Published: 5 December 2022

**Publisher's Note:** MDPI stays neutral with regard to jurisdictional claims in published maps and institutional affiliations.



**Copyright:** © 2022 by the authors. Licensee MDPI, Basel, Switzerland. This article is an open access article distributed under the terms and conditions of the Creative Commons Attribution (CC BY) license (<https://creativecommons.org/licenses/by/4.0/>).

## 1. Introduction

In 1964, C. E. Dent and M. Friedman reported two unrelated English boys with a rare form of renal tubular rickets with hypercalciuria and tubular proteinuria, and initially described what has been called Dent disease [1,2]. Dent disease is an X-linked recessive disorder of the proximal tubules that classically manifests with low-molecular-weight proteinuria, hypercalciuria leading to nephrocalcinosis or nephrolithiasis, and progressive renal failure [3–5]. The exact prevalence is unknown, and as of 2010, over 250 affected families had been reported [5].

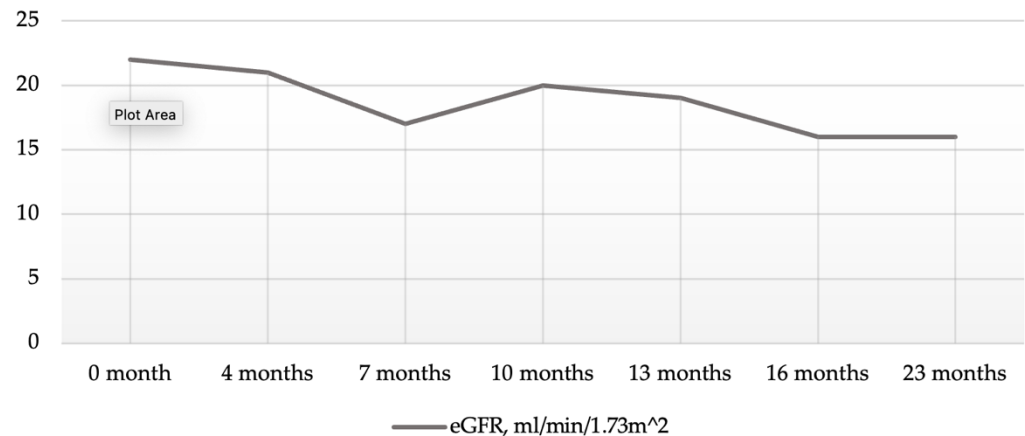
Dent disease may be caused by either an inactivating mutation in CLCN5, which is located on chromosome Xp11.22 (Dent disease type 1, OMIM #300009), or the OCRL1 gene located on chromosome Xq25 (Dent disease type 2, OMIM #300555) [5–8]. Mutations in CLCN5 are found in approximately 60% of male patients, whereas mutations in OCRL1 account for approximately 15% of cases [8–12]. For the remaining cases, there is a lack of molecular genetic characterization assuming further genetic heterogeneity [8,13]. Additionally, the phenotype is variable, and the correct diagnosis is often late or even missed [5,14,15].

Herein, we describe the case of a 45-year-old man with Dent disease who developed renal failure, with a literature review.

## 2. Case Presentation Section

A 45-year-old male was referred to a tertiary care nephrologist due to continuously deteriorating renal function over the past two years (Figure 1) and episodically elevated blood pressure. The presence of proteinuria in this patient was first noted at the age of seven months. There are no medical data before the patient was 24 years old, when a kidney biopsy was performed due to persistent nephritic syndrome (serum creatinine (SCr) was 150 µmol/L). The pathological record information at that time indicated that the

patient was diagnosed with focal segmental glomerulosclerosis (FSGS); however, electron microscopy was not performed for additional evaluation. Medullar kidney disease or Alport syndrome was suspected; unfortunately, the patient was not investigated further. Twelve years later, 24 h urinalysis was performed and revealed proteinuria (2.67 g/24 h), a urine dipstick showed hematuria, and serum creatinine was 170  $\mu\text{mol/L}$  at that time. There are no clinical records on visits to a nephrologist until the age of 43 years.



**Figure 1.** Course of renal function before transferring to a tertiary care nephrologist. Note: Kidney function was evaluated as eGFR (grey line). The 0 month marker represents the beginning of regular visits to a nephrologist in May 2019 (SCr—295  $\mu\text{mol/L}$ ), whereas 22 months represents the last visit before transferring to tertiary care (April 2021) (SCr—395  $\mu\text{mol/L}$ ).

At the first visit to the tertiary care nephrologist, the patient was asymptomatic, with a blood pressure of 127/92 mmHg and pulse of 68 beats/min. The patient's height and weight were 172 cm and 83 kg, respectively. Laboratory investigations indicated no evidence of anemia, severe acidosis, or serum electrolyte abnormalities; however, they showed high levels of serum creatinine and parathyroid hormone, dyslipidemia and vitamin D deficiency (Table 1). Urinalysis, 24 h urine sample and urine chemistries showed hypoosmotic urine, albuminuria, hypermagnesuria, and hypernatruria (Table 2). Urine protein electrophoresis was not performed. Abdominal ultrasound examination was performed, revealing nephrosclerosis and cysts in both kidneys (up to 3.6 cm). The renal parenchyma could hardly be differentiated from the surrounding tissue, and a 1.3 cm calcinate was observed in the parenchyma of the left kidney.

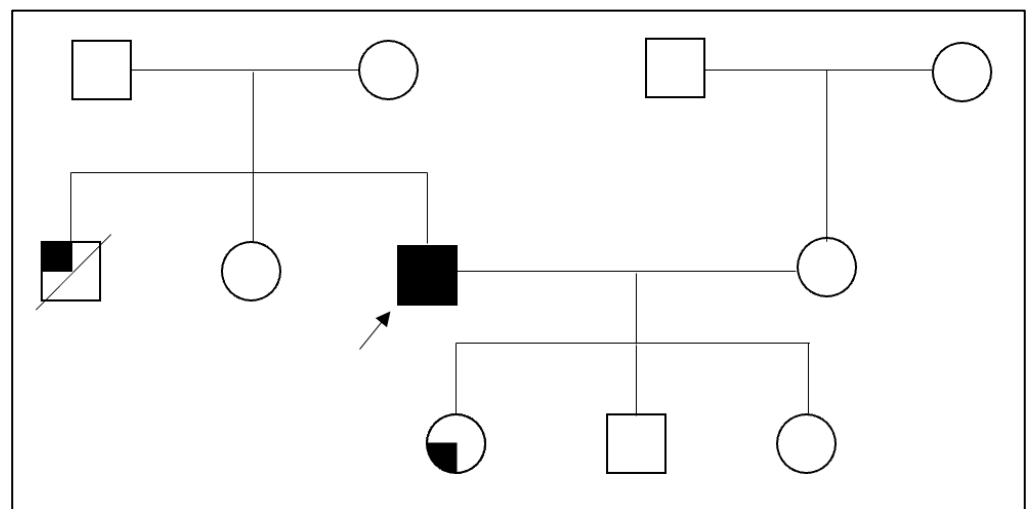
Family history revealed that his brother was also found to have proteinuria at the age of 2 years. Moreover, 15 years later he developed chronic kidney disease, and renal hypoplasia was diagnosed. At the age of 38 years, he begun dialysis, and at the age of 40 years he underwent cadaveric kidney transplantation. He died 13 years later from a myocardial infarction. Furthermore, nephrocalcinosis was seen in the patient's daughter (Figure 2).

To investigate a possible genetic mutation in this patient, a genetic analysis for hereditary kidney diseases was conducted. Informed consent for genetic analyses was obtained. A pathogenic mutation p.[(Leu129\*)] (c.386T>A) in exon 6 of the CLCN5 gene was identified by gene panel testing for renal diseases using a next-generation sequencing, which corresponds to a diagnosis of Dent disease. Genomic DNA was extracted from the peripheral blood of the patient. A close follow up, along with angiotensin-converting enzyme (ACE) inhibitors and rosuvastatin, has been continued to date. The patient's kidney function continued to worsen (Figure 3), and therefore a peritoneal dialysis catheter was implanted. He was included on the waiting list for renal transplantation and renal replacement therapy has not yet been started.

**Table 1.** Laboratory investigation.

	Value	Reference Range
<b>Complete blood count</b>		
White blood cell, $\times 10^9/L$	5.99	4.0–9.8
Hemoglobin, g/L	143	128–160
Platelet, $\times 10^9/L$	213	140–450
<b>Arterial blood gas</b>		
pH	7.386	7.35–7.45
pCO <sub>2</sub> , mmHg	37.4	35–48
pO <sub>2</sub> , mmHg	<b>74.8</b>	83–108
HCO <sub>3</sub> <sup>-</sup> , mmol/L	21.9	21–28
Actual base excess, mmol/L	<b>-2.1</b>	-2–+3
<b>Biochemistry</b>		
Serum creatinine, $\mu\text{mol/L}$	<b>366</b>	64–104
Urea, mmol/L	<b>9.8</b>	2.5–7.5
Uric acid, $\mu\text{mol/L}$	304	208–428
Total protein, g/L	67.7	66–83
Albumin, g/L	41.4	36–52
C-reactive protein, mg/L	1.68	≤5
Potassium, mmol/L	4.7	3.8–5.3
Sodium, mmol/L	145	134–148
Calcium, mmol/L	2.18	2.10–2.55
Phosphorus, mmol/L	0.85	0.74–1.52
Magnesium, mmol/L	0.82	0.65–1.05
Parathyroid hormone	<b>31.05</b>	1.6–7.3
25-hydroxyvitamin D, nmol/L	<b>27.3</b>	75–100
Cholesterol, mmol/L	<b>9.62</b>	<5.2
Triglycerides, mmol/L	<b>4.98</b>	≤1.8
High-density lipoprotein cholesterol, mmol/L	1.13	>0.91
Low-density lipoprotein cholesterol, mmol/L	<b>5.46</b>	2.6–3.5

Note: abnormal blood values are in bold.

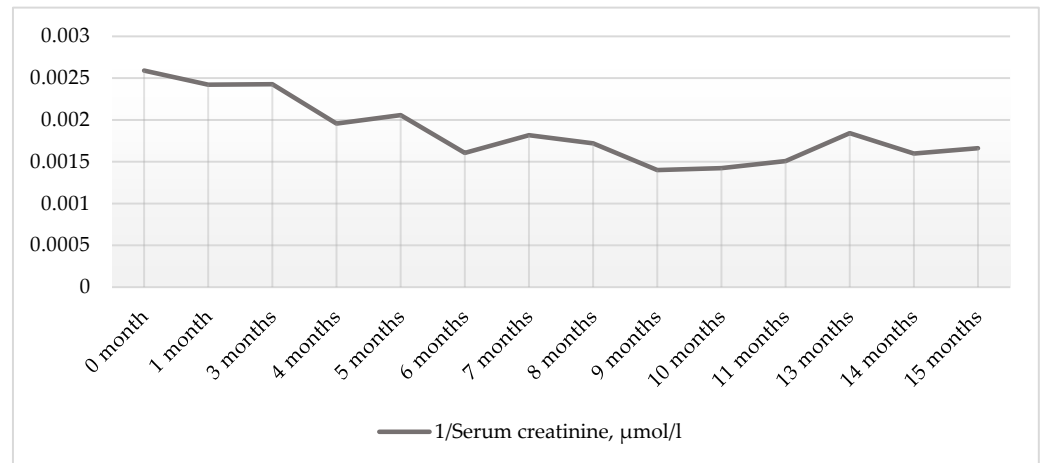


**Figure 2.** Family tree of the patient. Note: Arrow denotes the patient with Dent disease. Square represents male member, and circle represents female member. The quarter-filled square represents the patient’s brother with renal hypoplasia, whereas the quarter-filled circle represents the patient’s daughter with nephrocalcinosis.

**Table 2.** Urinary analites.

	Value	Reference Range
<b>Urinalysis</b>		
pH	6.5	4.0–8.0
Urine-specific gravity	<b>1.004</b>	1.010–1.030
Urine protein, g/L	0.7 (1+)	≤0.15
Urine glucose, mmol/L	0	≤2.8
Urine blood, mg/L	0.6 (1+)	≤0.6
Urine white blood cells, /μL	0	≤25
<b>Urine chemistries</b>		
Urine total protein, g/L	<b>0.793</b>	<0.11
24 h urine total protein, g/24 h	<b>6.106</b>	<0.15
Urine albumin, mg/L	<b>456</b>	<20
24 h urine albumin, mg/24 h	<b>3511.2</b>	<30
Albumin–creatinine ratio, mg/mmol	<b>233.85</b>	<2.5
Urine potassium, mmol/L	13.4	
24 h urine potassium, mmol/24 h	103.18	25–125
Urine sodium, mmol/L	44	
24 h urine sodium, mmol/24 h	<b>338.8</b>	40–220
Urine calcium, mmol/L	0.54	
24 h urine calcium, mmol/24 h	4.158	2.5–7.5
Urine phosphorus, mmol/L	4.44	
24 h urine phosphorus, mmol/L	34.188	16.5–48.5
Urine magnesium, mmol/L	0.83	
24 h urine magnesium, mmol/24 h	<b>6.391</b>	3.0–5.0

Note: abnormal urine values are in bold.



**Figure 3.** Course of renal function after transferring to a tertiary care nephrologist. Note: Kidney function was evaluated as 1/creatinine level (grey line). The 0 month marker represents the beginning of regular visits to a tertiary care nephrologist in May 2021 (SCr—386 µmol/L). The patient is under the supervision of a tertiary care nephrologist until present. The figure shows data on kidney function for 15 months (until August 2022) (SCr—602 µmol/L).

### 3. Discussion

Dent disease is a heterogenous group of X-linked renal tubular disorders characterized by an incomplete renal Fanconi syndrome [16]. It is a rare disorder with a variety of clinical manifestations and therefore a challenging diagnosis [5,14,15]. Bhardwaj et al. discovered that the median age at onset of Dent disease was 1.8 years (range, 0.3–8), while the median age of diagnosis was 8.0 years (range, 1.5–14) [17]. However, some asymptomatic cases are usually diagnosed in adult life due to early occurrence of idiopathic chronic kidney disease (CKD) [16,18,19]. Blanchard et al. reported the mean age of patients with end-stage

renal disease (ESRD) due to Dent disease to be 40 years [20]. In our case, proteinuria was first detected at the age of seven months, although the definitive diagnosis was established when the patient was investigated due to CKD at the age of 45 years.

The *CLCN5* gene encodes CIC-5, an electrogenic chloride channel  $\text{Cl}^-/\text{H}^+$  antiporter [7,16,21,22]. CIC-5 is mainly expressed in the proximal tubule and intercalated cells of the collecting duct, and has a crucial role in the acidification of early endosomes of proximal tubular cells [16,23,24]. More than 250 different pathogenic variants of *CLCN5* in Dent disease have been identified thus far, mainly including missense (35%) or frameshift (31%) mutations, followed by nonsense, splicing mutations, and large deletions (16%, 10%, and 4%, respectively) [16,25,26]. Mansour-Hendili et al. found that the most frequent mutations are p.Ser244Leu, p.Arg637\*, and p.Arg704\* [26]. We presented a case with a p.[(Leu129\*)] (c.386T>A) mutation in the *CLCN5* gene, which has not been described in the literature before; therefore, the impact of the mutation on Dent disease phenotype is unestablished.

Lack of functional CIC-5 inhibits the endocytosis of proximal tubular epithelial cells, therefore the primary function of reabsorbing amino acids, hormones, and carbohydrates cannot be exerted causing low-molecular-weight proteinuria (LMWP) [11,16,24]. The CIC-5 disruption reduces megalin expression at the brush border membrane of proximal tubular cells and impairs the endocytosis of parathyroid hormone (PTH), leading to an increased concentration of PTH in the urine, and consequently a high level of 1,25-(OH)<sub>2</sub>-vitamin D<sub>3</sub>. Therefore, the intestinal absorption of calcium is promoted, resulting in hypercalciuria and renal calcification [22–24,27]. In addition, accumulation of PTH at the renal tubules stimulates PTH receptors and reduces phosphate reabsorption, leading to hypophosphatemia/hyperphosphaturia [22,23].

There is no genotype–phenotype correlation and the spectrum of the disease’s clinical presentation is broad [28]. Soares et al. stated that the phenotypic differences worldwide are due to a combination of dietary and environmental factors, delayed diagnosis and the effect of modifier genes [28,29]. Moreover, Blanchard et al. found that with age the phenotype progresses from proximal nephropathy to a combined proximal/distal salt-losing tubulopathy [20]. An estimated decline in glomerular filtration rate (GFR) with age is from 1.0 to 1.6 mL/min/1.73 m<sup>2</sup> per year [20]. According to Bhardwaj et al., the p.Ser244Leu mutation is associated with more rapid progression to kidney failure in the first decade [17]. The key characteristics of Dent disease include LMWP, hypercalciuria (>4.0 mg in adults), and at least one of the following: nephrocalcinosis, nephrolithiasis, hypophosphatemia, CKD, or family history consistent with X-linked inheritance [22,28,30]. In contrast to LMWP, hypercalciuria is a less-constant feature and declines with age. In addition, it was found that 85% of patients older than 30 years had normal calcium in their urine [20]. Nephrocalcinosis usually occurs in childhood and appears in almost 75% of patients [20,31]. Our patient presented with secondary hyperparathyroidism, albuminuria, and no signs of hypercalciuria. Hypercholesterolemia and hypertriglyceridemia were also seen. Although dyslipidemia is not a typical observation in Dent disease, Soares et al. described a case with hypercholesterolemia refractory to statin therapy [28].

Currently, there is no reliable verification of kidney biopsy with either diagnostic or prognostic value [16]. However, glomerulosclerosis is found in almost two-thirds of the biopsies, with a median of 17% glomeruli being sclerosed [32–35]. Furthermore, the glomerulosclerosis is usually focal–global rather than focal–segmental [32,34,35]. In our case, kidney biopsy showed focal segmental glomerulosclerosis, which is seen in approximately 6.6% of Dent disease cases [10,20,34]. Focal interstitial fibrosis and inflammation, as well as tubular atrophy, dilatation or tubulitis, are also seen in renal biopsies (60%, 53.3%, and 70% of cases, respectively) [10,20,36]. Focal giant mitochondria with dense condensation and dilatation of the endoplasmic reticulum in the proximal tubules are uncommon findings [10]. Furthermore, interstitial fibrosis and inflammation were usually located adjacent to a sclerotic glomeruli [10]. Wang et al. reported that foot process effacement was noted in 57% of the patients, and was mostly mild and segmental [10]. Additionally, the

presence of foot process effacement was linked to a steeper annual eGFR decline during the follow-up [10].

There is no specific treatment; however, the main goals of therapy are to decrease hypercalciuria, prevent nephrocalcinosis and renal stones, and slow down the progression to ESRD [28,37,38]. Administration of thiazide diuretic and restriction of dietary sodium intake reduces calcium excretion. Moreover, thiazide diuretics doses greater than 0.4 mg/kg/day reduces urinary calcium excretion by more than 40%, albeit patients with such doses may develop symptomatic hypotension or hypokalemia [28,37,39]. Data regarding RAAS inhibition in Dent disease are scant, although Deng et al. showed a reduction in the urinary microalbumin-to-creatinine ratio in 54% of children after a median 1.7 years of treatment [40]. In our case, the patient did not receive thiazide diuretics in addition to ACE inhibition. Patients with ESRD need renal replacement therapy and are often excellent candidates for transplantation, since the disease is unlikely to recur after transplantation [3,41–43]. Moreover, experimental models have shown positive effects of a diet high in citrate in suspending the progression of kidney disease [44].

#### 4. Conclusions

Dent disease has a variable phenotype; therefore, the diagnosis may be underrecognized. This case is significant due to a delayed diagnosis of Dent disease, which could be caused by non-specific clinical manifestation and histological findings of kidney biopsy. Moreover, Dent disease is still a relatively new concept, especially in the adult population. Thus, Dent disease should be considered in the presence of a family history of kidney disease, persistent albuminuria from a young age, glomerulosclerosis in renal biopsy, and progressive idiopathic renal failure in male adult patients.

**Author Contributions:** Conceptualization, M.V., A.Č. and M.M.; writing—original draft preparation, M.V.; writing—review and editing, A.Č. and M.M.; visualization, M.V.; supervision, A.Č. and M.M. All authors have read and agreed to the published version of the manuscript.

**Funding:** This research received no external funding.

**Institutional Review Board Statement:** Not applicable. Ethical approval was not sought for the present study because Lithuanian Bioethics Committee does not interpret the Clinical Case Report of a single person as a clinical study.

**Informed Consent Statement:** Written informed consent has been obtained from the patient to publish this paper.

**Data Availability Statement:** No new data were created or analyzed in this study. Data sharing is not applicable to this article.

**Conflicts of Interest:** The authors declare no conflict of interest.

#### References

1. Dent, C.E.; Friedman, M. Hypercalcuric Rickets Associated with Renal Tubular Damage. *Arch. Dis. Child.* **1964**, *39*, 240–249. [[CrossRef](#)] [[PubMed](#)]
2. Solano, A.; Lew, S.Q.; Ing, T.S. Dent–Wrong disease and other rare causes of the Fanconi syndrome. *Clin. Kidney J.* **2014**, *7*, 344–347. [[CrossRef](#)] [[PubMed](#)]
3. Scheinman, S.J. X-linked hypercalciuric nephrolithiasis: Clinical syndromes and chloride channel mutations. *Kidney Int.* **1998**, *53*, 3–17. [[CrossRef](#)] [[PubMed](#)]
4. Devonald, M.A.J.; Karet, F.E. Renal Epithelial Traffic Jams and One-Way Streets. *J. Am. Soc. Nephrol.* **2004**, *15*, 1370–1381. [[CrossRef](#)] [[PubMed](#)]
5. Devuyt, O.; Thakker, R.V. Dent’s disease. *Orphanet J. Rare Dis.* **2010**, *5*, 28. [[CrossRef](#)]
6. Wrong, O.M.; Norden, A.G.; Feest, T.G. Dent’s disease: A familial proximal renal tubular syndrome with low-molecular-weight proteinuria, hypercalciuria, nephrocalcinosis, metabolic bone disease, progressive renal failure and a marked male predominance. *QJM Mon. J. Assoc. Physicians* **1994**, *87*, 473–493.
7. Scheel, O.; Zdebik, A.A.; Lourdel, S.; Jentsch, T.J. Voltage-dependent electrogenic chloride/proton exchange by endosomal CLC proteins. *Nature* **2005**, *436*, 424–427. [[CrossRef](#)]

8. Hoopes, R.R., Jr.; Shrimpton, A.E.; Knohl, S.J.; Hueber, P.; Hoppe, B.; Matyus, J.; Simckes, A.; Tasic, V.; Toenshoff, B.; Suchy, S.F.; et al. Dent Disease with Mutations in OCRL1. *Am. J. Hum. Genet.* **2005**, *76*, 260–267. [[CrossRef](#)]
9. Lloyd, S.E.; Pearce, S.H.; Fisher, S.E.; Steinmeyer, K.; Schwappach, B.; Scheinman, S.J.; Harding, B.; Bolino, A.; Devoto, M.; Goodyer, P.; et al. A common molecular basis for three inherited kidney stone diseases. *Nature* **1996**, *379*, 445–449. [[CrossRef](#)]
10. Wang, X.; Anglani, F.; Beara-Lasic, L.; Mehta, A.J.; Vaughan, L.E.; Herrera Hernandez, L.; Cogal, A.; Scheinman, S.J.; Ariceta, G.; Isom, R.; et al. Glomerular Pathology in Dent Disease and Its Association with Kidney Function. *Clin. J. Am. Soc. Nephrol. CJASN* **2016**, *11*, 2168–2176. [[CrossRef](#)]
11. Ehlayel, A.M.; Copelovitch, L. Update on Dent Disease. *Pediatr. Clin.* **2019**, *66*, 169–178. [[CrossRef](#)]
12. Böckenhauer, D.; Bökenkamp, A.; Nuutinen, M.; Unwin, R.; Van't Hoff, W.; Sirimanna, T.; Vrljicak, K.; Ludwig, M. Novel OCRL mutations in patients with Dent-2 disease. *J. Pediatr. Genet.* **2012**, *1*, 15–23. [[CrossRef](#)]
13. Zaniew, M.; Mizerska-Wasiak, M.; Załuska-Leńniewska, I.; Adamczyk, P.; Kiliś-Pstrusińska, K.; Haliński, A.; Zawadzki, J.; Lipska-Ziętkiewicz, B.S.; Pawlaczyk, K.; Sikora, P.; et al. Dent disease in Poland: What we have learned so far? *Int. Urol. Nephrol.* **2017**, *49*, 2005–2017. [[CrossRef](#)]
14. Ludwig, M.; Utsch, B.; Monnens, L.A.H. Recent advances in understanding the clinical and genetic heterogeneity of Dent's disease. *Nephrol. Dial. Transplant.* **2006**, *21*, 2708–2717. [[CrossRef](#)]
15. Beara-Lasic, L.; Cogal, A.; Mara, K.; Enders, F.; Mehta, R.A.; Haskic, Z.; Furth, S.L.; Trachtman, H.; Scheinman, S.J.; Milliner, D.S.; et al. Prevalence of low molecular weight proteinuria and Dent disease 1 CLCN5 mutations in proteinuric cohorts. *Pediatr. Nephrol.* **2020**, *35*, 633–640. [[CrossRef](#)]
16. Ganesello, L.; Del Prete, D.; Anglani, F.; Calò, L.A. Genetics and phenotypic heterogeneity of Dent disease: The dark side of the moon. *Hum. Genet.* **2021**, *140*, 401–421. [[CrossRef](#)]
17. Bhardwaj, S.; Thergaonkar, R.; Sinha, A.; Hari, P.; Hi, C.; Bagga, A. Phenotype of dent disease in a cohort of Indian children. *Indian Pediatr.* **2016**, *53*, 977–982. [[CrossRef](#)]
18. Lloyd, S.E.; Pearce, S.H.; Günther, W.; Kawaguchi, H.; Igarashi, T.; Jentsch, T.J.; Thakker, R.V. Idiopathic low molecular weight proteinuria associated with hypercalciuric nephrocalcinosis in Japanese children is due to mutations of the renal chloride channel (CLCN5). *J. Clin. Investig.* **1997**, *99*, 967–974. [[CrossRef](#)]
19. Zaniew, M.; Bökenkamp, A.; Kolbuc, M.; La Scola, C.; Baronio, F.; Niemirska, A.; Szczepanska, M.; Bürger, J.; La Manna, A.; Miklaszewska, M.; et al. Long-term renal outcome in children with OCRL mutations: Retrospective analysis of a large international cohort. *Nephrol. Dial. Transplant.* **2018**, *33*, 85–94.
20. Blanchard, A.; Curis, E.; Guyon-Roger, T.; Kahila, D.; Treard, C.; Baudouin, V.; Bérard, E.; Champion, G.; Cochat, P.; Dubourg, J.; et al. Observations of a large Dent disease cohort. *Kidney Int.* **2016**, *90*, 430–439. [[CrossRef](#)] [[PubMed](#)]
21. Picollo, A.; Pusch, M. Chloride/proton antiporter activity of mammalian CLC proteins CIC-4 and CIC-5. *Nature* **2005**, *436*, 420–423. [[CrossRef](#)] [[PubMed](#)]
22. Claverie-Martín, F.; Ramos-Trujillo, E.; García-Nieto, V. Dent's disease: Clinical features and molecular basis. *Pediatr. Nephrol.* **2011**, *26*, 693–704. [[CrossRef](#)] [[PubMed](#)]
23. Poroca, D.R.; Pelis, R.M.; Chappel, V.M. CIC Channels and Transporters: Structure, Physiological Functions, and Implications in Human Chloride Channelopathies. *Front. Pharmacol.* **2017**, *8*, 151. [[CrossRef](#)]
24. Jin, Y.Y.; Huang, L.M.; Quan, X.F.; Mao, J.H. Dent disease: Classification, heterogeneity and diagnosis. *World J. Pediatr.* **2021**, *17*, 52–57. [[CrossRef](#)]
25. Ganesello, L.; Del Prete, D.; Ceol, M.; Priante, G.; Calò, L.A.; Anglani, F. From protein uptake to Dent disease: An overview of the CLCN5 gene. *Gene* **2020**, *747*, 144662. [[CrossRef](#)]
26. Mansour-Hendili, L.; Blanchard, A.; Le Pottier, N.; Roncelin, I.; Lourdel, S.; Treard, C.; González, W.; Vergara-Jaque, A.; Morin, G.; Colin, E.; et al. Mutation Update of the CLCN5 Gene Responsible for Dent Disease 1. *Hum. Mutat.* **2015**, *36*, 743–752. [[CrossRef](#)]
27. Günther, W.; Piwon, N.; Jentsch, T.J. The CIC-5 chloride channel knock-out mouse—An animal model for Dent's disease. *Pflüg. Arch.* **2003**, *445*, 456–462. [[CrossRef](#)]
28. Soares, R.B.; Bhat, N. Dent Disease Type 1: A Diagnostic Dilemma and Review. *Cureus* **2022**, *14*, e23910. [[CrossRef](#)]
29. Sekine, T.; Komoda, F.; Miura, K.; Takita, J.; Shimadzu, M.; Matsuyama, T.; Ashida, A.; Igarashi, T. Japanese Dent disease has a wider clinical spectrum than Dent disease in Europe/USA: Genetic and clinical studies of 86 unrelated patients with low-molecular-weight proteinuria. *Nephrol. Dial. Transplant.* **2014**, *29*, 376–384. [[CrossRef](#)]
30. Akuta, N.; Lloyd, S.E.; Igarashi, T.; Shiraga, H.; Matsuyama, T.; Yokoro, S.; Cox, J.P.; Thakker, R.V. Mutations of CLCN5 in Japanese children with idiopathic low molecular weight proteinuria, hypercalciuria and nephrocalcinosis. *Kidney Int.* **1997**, *52*, 911–916. [[CrossRef](#)]
31. Scheinman, S.J. Nephrolithiasis. *Semin. Nephrol.* **1999**, *19*, 381–388.
32. Frishberg, Y.; Dinour, D.; Belostotsky, R.; Becker-Cohen, R.; Rinat, C.; Feinstein, S.; Navon-Elkan, P.; Ben-Shalom, E. Dent's disease manifesting as focal glomerulosclerosis: Is it the tip of the iceberg? *Pediatr. Nephrol.* **2009**, *24*, 2369–2373. [[CrossRef](#)]
33. Van Berkel, Y.; Ludwig, M.; van Wijk, J.A.E.; Bökenkamp, A. Proteinuria in Dent disease: A review of the literature. *Pediatr. Nephrol.* **2017**, *32*, 1851–1859. [[CrossRef](#)]
34. Copelovitch, L.; Nash, M.A.; Kaplan, B.S. Hypothesis: Dent Disease Is an Underrecognized Cause of Focal Glomerulosclerosis. *Clin. J. Am. Soc. Nephrol.* **2007**, *2*, 914–918. [[CrossRef](#)]

35. Fervenza, F.C. A Patient with Nephrotic-Range Proteinuria and Focal Global Glomerulosclerosis. *Clin. J. Am. Soc. Nephrol.* **2013**, *8*, 1979–1987. [[CrossRef](#)]
36. Yanagida, H.; Ikeoka, M.; Kuwajima, H.; Wada, N.; Tabata, N.; Sugimoto, K.; Okada, M.; Takemura, T. A boy with Japanese Dent's disease exhibiting abnormal calcium metabolism and osseous disorder of the spine: Defective megalin expression at the brushborder of renal proximal tubules. *Clin. Nephrol.* **2004**, *62*, 306–312. [[CrossRef](#)]
37. Raja, K.A.; Schurman, S.; D'mello, R.G.; Blowey, D.; Goodyer, P.; Van Why, S.; Ploutz-Snyder, R.J.; Asplin, J.; Scheinman, S.J. Responsiveness of Hypercalciuria to Thiazide in Dent's Disease. *J. Am. Soc. Nephrol.* **2002**, *13*, 2938–2944. [[CrossRef](#)]
38. Güngör, T.; Eroğlu, F.K.; Yazılıtaş, F.; Gür, G.; Çakıcı, E.K.; Ludwig, M.; Bülbül, M. A case of Type 1 Dent disease presenting with isolated persistent proteinuria. *Turk. Arch. Pediatr. Pediatr. Arş.* **2020**, *55*, 72–75.
39. Blanchard, A.; Vargas-Poussou, R.; Peyrard, S.; Mogenet, A.; Baudouin, V.; Boudailliez, B.; Charbit, M.; Deschesnes, G.; Ezzhair, N.; Loirat, C.; et al. Effect of hydrochlorothiazide on urinary calcium excretion in dent disease: An uncontrolled trial. *Am. J. Kidney Dis.* **2008**, *52*, 1084–1095. [[CrossRef](#)]
40. Deng, H.; Zhang, Y.; Xiao, H.; Yao, Y.; Zhang, H.; Liu, X.; Su, B.; Guan, N.; Zhong, X.; Wang, S.; et al. Phenotypic spectrum and antialbuminuric response to angiotensin converting enzyme inhibitor and angiotensin receptor blocker therapy in pediatric Dent disease. *Mol. Genet. Genom. Med.* **2020**, *8*, e1306. [[CrossRef](#)]
41. Gambaro, G.; Naticchia, A.; Ferraro, P.M.; Spagnoletti, G.; Romagnoli, J.; Salerno, M.P.; Citterio, F. Living Kidney Donation in a Type 1 Dent's Disease Patient from His Mother. *Kidney Blood Press. Res.* **2019**, *44*, 1306–1312. [[CrossRef](#)]
42. Edvardsson, V.O.; Goldfarb, D.S.; Lieske, J.C.; Beara-Lasic, L.; Anglani, F.; Milliner, D.S.; Palsson, R. Hereditary causes of kidney stones and chronic kidney disease. *Pediatr. Nephrol.* **2013**, *28*, 1923–1942. [[CrossRef](#)]
43. Alhasan, K.; D'Alessandri-Silva, C.; Mongia, A.; Topaloglu, R.; Tasic, V.; Filler, G. Young Adults with Hereditary Tubular Diseases: Practical Aspects for Adult-Focused Colleagues. *Adv. Chronic Kidney Dis.* **2022**, *29*, 292–307. [[CrossRef](#)]
44. Cebotaru, V.; Kaul, S.; Devuyt, O.; Cai, H.; Racusen, L.; Guggino, W.B.; Guggino, S.E. High citrate diet delays progression of renal insufficiency in the CIC-5 knockout mouse model of Dent's disease. *Kidney Int.* **2005**, *68*, 642–652. [[CrossRef](#)]